

PHILOSOPHICAL TRANSACTIONS.

I. *A Record of Experiments upon the Functions of the Cerebral Cortex.*

By VICTOR HORSLEY, M.B., F.R.C.S., F.R.S., *Professor Superintendent of the Brown Institution, and EDWARD ALBERT SCHÄFER, F.R.S., Jodrell Professor of Physiology in University College, London. (From the Physiological Laboratory, University College.)*

Received February 5,—Read February 17, 1887.

[PLATES 1–7.]

INTRODUCTORY REMARKS.

THE experiments which are here recorded are selected from a series which we have been engaged upon during the past three years, having for their object the further elucidation of the functions of the several parts of the cerebral cortex, with especial reference to localisation of the centres for voluntary action and sensation. They were undertaken by us in the hope of clearing up some of the discrepancies in the evidence offered upon these points by previous observers, and for this purpose it was important to go over ground which had already been trodden; but we subsequently found it to be necessary to investigate portions of the cortex which, probably by reason of difficulty of access, had not, so far as we could ascertain, been touched by our predecessors in this field of physiological research, and particularly the convolutions upon the mesial aspect of the hemisphere, viz., the gyrus marginalis and the gyrus fornicatus.

Methods.

The methods we have employed have been: 1. Electrical Excitation, and 2. Ablation. For the purposes of electrical excitation we have generally used a DU BOIS-REYMOND inductorium, with a metallic reed interruptor in place of the

usual WAGNER hammer, so arranged that, as with the HELMHOLTZ side-wire, the primary current is never entirely opened; this method we have already described elsewhere.* The strength of the excitation used was always such as to produce no more than a slight pricking sensation on the tongue. The removal of the various parts of the cerebral cortex has in all our experiments, except the first few, been effected by the knife, or by small cutting instruments specially constructed for the purpose. We were led to adopt the knife instead of the galvanic cautery (which had been used by Professors FERRIER and YEO) on account of the greater facility with which the lesion can be limited exactly in depth and extent without risk of subsequent disintegration of the neighbouring parts, while at the same time the bleeding is not markedly greater, and is usually readily stayed by gentle pressure. All these experiments have been performed with the strictest antiseptic precautions and under carbolic spray, and the wound, after being closely stitched, has been dressed with antiseptic gauze, and this again overlaid and rendered firmly adherent to the surrounding scalp by a layer of thick collodion so as to make it impossible for the animals to tear away the dressing; at the same time, the collodion, shrinking and becoming hard in drying, serves temporarily to support the contents of the skull, and to prevent their protrusion through the aperture made by the trephine or saw. The dressing was always removed within a week after the operation, sometimes as early as the third day, and it was almost invariably found that the edges of the wound in the skin had completely united, and that the animal could safely be left without further dressing or attention. Moreover there appears to be no tendency under these circumstances for any extension of the lesion to occur by inflammation of the surrounding parts of the brain, nor do adhesions form between the surface of the brain and the enveloping membrane, except along the edges of the wound. In all the cases here recorded the animals employed have been Monkeys, but we have not confined ourselves to one kind alone, having used indiscriminately individuals belonging to various species. They have usually been kept alive for some weeks or months after the operation, sometimes being submitted to two or more successive ablations at variable intervals of time. In those cases in which the animals have died, death has very rarely been due to the shock or severity of the operation, except in the case of lesions producing very extensive motor paralysis, but has been the result of accidental causes, and especially of a sort of dysenteric diarrhoea to which Monkeys appear peculiarly liable. In most instances the animals have been purposely killed after having been sufficiently long under observation, and, the condition of the brain having been accurately recorded, the whole of the central nervous system has been preserved for future investigation. All the operations have been performed under anæsthetics, either chloroform or ether being used, almost always supplemented by the hypodermic injection of morphia (as much as from half to one grain of the acetate

* HORSLEY and SCHÄFER, "Experiments on the Character of the Muscular Contractions which are evoked by Excitation of the various Parts of the Motor Tract." 'Journal of Physiology,' vol. 7, p. 96.

having usually been given). This has the great advantage of causing the animal to remain perfectly quiet for several hours after the operation, and of permitting it, during the slow process of recovery from the effects of the morphia, to become accustomed to the collodion dressing, which would otherwise be irksome, and this would lead to attempts at removal.*

It has, however, the disadvantage that observations cannot be at once made upon the disturbance of function produced by the lesion, on account of the condition of stupor which is caused by the morphia. This disadvantage is not so great as it may at first sight seem, for such immediate observations are of less value than later ones, especially when the lesion is an extensive one, on account of the very considerable disturbance which must be temporarily produced upon the remainder of the hemisphere, partly by the blocking of the vessels of the ablated portion, and partly by the loss of support experienced by the neighbouring portions when a large piece has been removed at one operation.

We may conveniently arrange our general results according to the regions to which they respectively relate, and they will therefore be grouped under the following heads, viz. :—I. Prefrontal ; II. Central or Motor ; III. Occipital ; IV. Temporo-sphenoidal and Limbic.

I.—RESULTS OF EXPERIMENTS UPON THE PREFRONTAL REGION OF THE HEMISPHERE.

Results of excitation.—Electrical excitation of the anterior end of the frontal lobes has invariably yielded negative results in our hands. But behind the anterior end of the sagittal limb of the precentral sulcus the lateral movement of the head and eyes described by FERRIER† begins to be evident.

Result of ablation.—In three cases we have completely removed at one operation the anterior third or fourth of both frontal lobes, including all that part which we had found electrically inexcitable. In two of these the animals rapidly recovered without showing any sign of motor paralysis,‡ nor could any deficiency of general or special sensibility be detected. One of the two Monkeys was a very tame animal, which had acquired certain tricks before the operation ; these were exhibited equally well afterwards ; nor was the Monkey rendered any less tame or intelligent, so far as could be detected, as the result of the lesion. In both cases the animals were under

* The morphia has also appeared to us to diminish the hæmorrhage from the cut cerebral surface. This is in any case easily stayed by the application of gentle pressure.

† FERRIER, 'Functions of the Brain,' 2nd edition, p. 242.

‡ After lesions of the anterior part of the frontal lobes the animals for the first few days always assume a characteristic attitude, sitting with the head bent downwards between the arms, and they appear more lethargic than is usual after operations involving other parts of the brain. But after a few days all these symptoms pass completely away, and the normal attitude and disposition are resumed.

observation for nearly four months without showing any abnormal symptoms whatever. The extent of the lesion in these two cases is shown in figs. 1 and 2; and the extent in a third experiment upon this region in fig. 3 (Plate 1). As was *à fortiori* to have been expected, unilateral ablation, which we performed in one case, proved equally devoid of positive results.

Conclusions and remarks.—The results of our experiments upon the anterior part of the frontal lobes have been completely negative so far as electrical excitation or the permanent result of ablation are concerned. In this we are in agreement with FERRIER and YEO,* but in contradiction of the results obtained by H. MUNK.† FERRIER and YEO, it is true, describe certain transient symptoms as having been observed by them, but we have already given our reasons for regarding such immediate and only transitory effects as not to be laid too much stress upon in the determination of the function of a part. And they expressly state that in the Monkeys which they were successful in keeping alive for any considerable time no physiological defect of any kind could be substantiated.‡ MUNK, on the other hand, has described positive symptoms as resulting from extirpation of this part of the cerebrum both in Dogs and Monkeys, viz., a paresis of the trunk muscles, causing loss of rotating power if the extirpation be unilateral; and with bilateral removal in Monkeys a peculiar cat-like bending of the trunk.§ MUNK also found that electrical excitation caused contraction of the muscles of the back and abdomen, and even the diaphragm, but admits that very strong excitations are necessary to produce any effect. He attempts to explain the necessity for such strong excitation by the greater weight which the trunk muscles have to move (in proportion to their number and size?), but it seems to us that a much simpler explanation may be given, and that the results which he describes are due to the spreading to other regions of the brain of the strong currents which he confesses to have been obliged to employ. The governance of the trunk muscles, which MUNK has ascribed to the prefrontal region, belongs rather, as we shall immediately show, to the middle of the marginal convolution and the adjoining part of the external surface of the hemisphere. The discrepancy between the

* FERRIER and YEO, "A Record of Experiments on the Effects of Lesion of different Regions of the Cerebral Hemispheres," 'Philosophical Transactions,' 1884. See also FERRIER, 'Functions of the Brain,' p. 396. It would seem that the whole of the prefrontal region was not removed in all the cases cited by Professors FERRIER and YEO, for in many the orbital surface is left intact. On the other hand, in some the lesion encroaches above and posteriorly on the centre for movement of the head and eyes.

† H. MUNK, "Ueber die Stirnlappen des Grosshirns," 'Sitzungsberichte der k. Preussischen Akademie,' 1882.

‡ See especially their remarks upon Case No. 22 recorded by them, in which the lesion of the prefrontal region was very complete.

§ Probably the attitude we have described in the note on the previous page. MUNK also affirms that cutaneous and muscular sensibility is lost in the trunk after this lesion, and indeed in all these cases of cortical lesion refers the resulting muscular paralysis to the loss of such sensibility; this is, however, a question which will be discussed later on.

results of our experiments upon the ablation of this part and those of MUNK we are unable to explain otherwise than by supposing that sufficient care was not taken by MUNK to localise the lesion by the adoption of the precautions of modern antiseptic surgery. Thus he speaks of operations upon this region in the Dog as taking two or three weeks to heal in the most favourable instances, and even then as discharging pus! And, although according to this author Monkeys appear to bear the removal of portions of the brain far more easily, so far as the after-process of healing is concerned, than Dogs, yet it must be assumed that there will be a greater or less amount of inflammatory extension of the intended lesion in all cases in which antiseptic precautions are omitted. Indeed we do not hesitate to affirm, on the strength of the evidence afforded by two or three of our cases in which the wound, although at first aseptic, subsequently became septic, that all experiments upon the brain in which these precautions are neglected are not only liable to be lacking in definiteness and precision, but may even be expected to yield illusory results.

No doubt the same remark will apply to the earlier experiments of FERRIER, which were performed without the employment of such precautions, and were obviously followed in many cases by inflammatory extension of the original lesion. The argument that such extension must have taken place, which with other arguments MUNK urges with somewhat unnecessary bitterness ('Functionen der Grosshirnrinde—Erste Mittheilung'), attempting to discredit the whole of FERRIER'S work in this direction, can be used with equal force against many of the results obtained by himself.

II.—RESULTS OF EXPERIMENTS UPON THE MOTOR REGION OF THE CEREBRAL CORTEX.

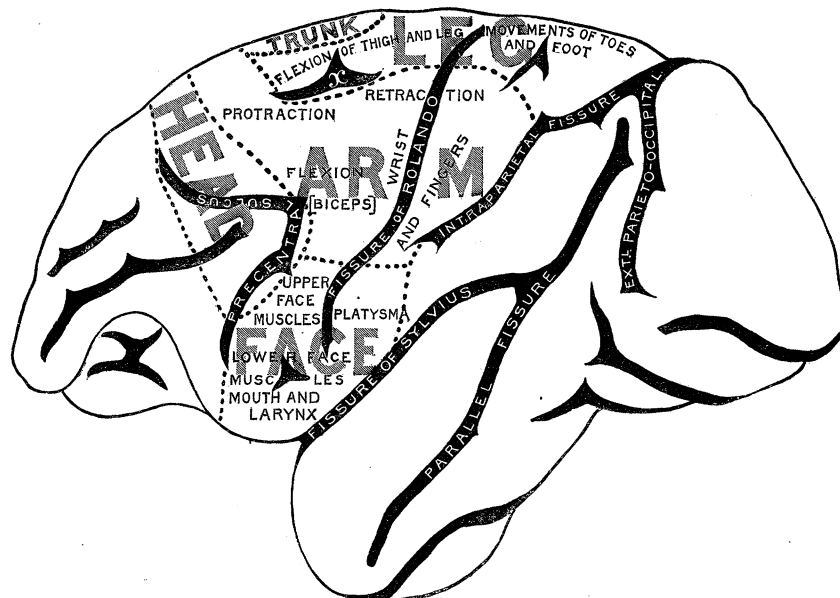
Results of excitation of the external surface.—Excitation of the external surface of the hemisphere has in our hands yielded results which are generally similar to those described by FERRIER,* which they may be said to extend and confirm, with some exception as to detail. It will be remembered that besides certain areas close to the great longitudinal fissures, which are concerned with movements of the hind-limb, the principal movements obtained by FERRIER by stimulation of the excitable portion of the external surface were: (1) On the middle of the frontal lobe—movements of the head and eyes. (2) Just behind this area on the ascending frontal—movements of the hand and arm. (3) On the ascending parietal—movements of the fingers and wrist. And (4) around the lower end of the fissure of ROLANDO, including parts of both central convolutions—movements of the face, jaw, and tongue (several of these movements being still further differentiated). Our experiments show that the motor portion of the cerebral cortex may be mapped out into a certain number of main areas, each of which is chiefly concerned with the movements of a particular part or limb, and in some of which certain centres concerned with more specialised

* 'Proceedings of the Royal Society,' vol. 23, 1875, p. 409.

movements may be marked out.* It will be convenient, in the first place, to describe those portions of these areas which are seen upon the external surface of the brain (see Diagram I.), and subsequently those which are met with upon the mesial surface.†

The *arm-area* occupies a portion of the cerebral surface which is triangular in shape, being broad behind and narrow in front. It comprises most of the upper half of the ascending parietal and ascending frontal gyri, from a little below the level of the sagittal part of the precentral fissure below, nearly to the margin of the hemisphere above, together with the adjacent part of the frontal lobe below the small antero-posterior sulcus marked *x*. In front of this sulcus it bends round to the mesial surface and is continuous with a part of the marginal gyrus, excitation of which also produces movements of the shoulder and arm, and which must therefore be regarded as also belonging to the arm-area.

Diagram I.



Over a large part of this area the actual movement which is obtained is the raising and protraction of the arm and hand, described by FERRIER as resulting from excitation of the area marked (5) in his diagram. In this movement most of the muscles of the shoulder and arm share in some degree or other, the exact part taken by one or other group, and consequently the effect produced, varying with the portion of the

* Although it is convenient for purposes of description to represent the areas and centres of the motor region as if they were sharply marked off from one another, there is no distinct evidence that this is really the case; but, on the contrary, if we are to accept the results of excitation (and, according to LUCIANI, they are confirmed in this particular by the results of localised ablation), there are no such sharp lines of demarcation, but every centre and area overlaps to a greater or less extent the surrounding areas.

† More precise details regarding the character of the movements evoked on excitation of the several parts of each area are given by Professor SCHÄFER in an article "Ueber die motorischen Rindencentren des Affengehirns" in 'Beiträge zur Physiologie, C. LUDWIG gewidmet,' Leipzig, 1887.

area stimulated. As a general fact, it may be stated that the shoulder muscles come into play most strongly when the electrodes are applied near the superior limit of the area, the muscles moving the forearm and wrist when they are applied near the central and inferior portions of the area, and the muscles of the wrist and fingers when applied along the posterior border. Here it is sometimes possible also to differentiate between the different movements of the fingers and wrist, for superiorly the excitation usually produces pronation of the hand with extension of the fingers and wrist, and inferiorly supination of the hand with flexion of the fingers. The production of these movements of the fingers is not confined to excitation of the ascending parietal gyrus,* but in very many cases the same movements are produced by exciting the ascending frontal at the corresponding point just across the fissure of ROLANDO.

The supination which frequently accompanies flexion of the fingers on excitation of the lower end of the posterior margin of the arm-area appears to be brought about by contraction of the supinator longus. But just in front of the centre for this movement is a considerable portion of the arm-area, excitation of which is invariably followed by biceps flexion and supination. This may therefore be regarded as a *biceps-centre* (nearly corresponding with that marked (6) by FERRIER†), although other muscles than the biceps are also brought into action when it is stimulated. It includes a portion of the ascending parietal and the adjacent part of the second frontal gyrus, and it abuts below on the face-area, and in front on the head-area.‡ Again the retraction of the shoulder and arm, which is produced by excitation at the upper part of the area on either side of the fissure of ROLANDO, is largely produced, as FERRIER has also shown, by the latissimus dorsi (although other muscles are also thrown into action), and might be described as the *latissimus-centre*.

The *face-area*, although we have so called it for convenience sake, actually gives rise to movements not only of the facial muscles, but also of the whole of the upper part of the alimentary tube (mouth, throat, and larynx). It comprises the whole of the ascending parietal and frontal convolutions below the arm-area, extending down to the fissure of SYLVIVS, and including the external surface of the operculum. It is physiologically remarkable from the fact that many of the movements which result from its excitation are apt to be executed bilaterally, which is only exceptionally the case with excitation of the other areas (except that for the head and eyes).

Excitation of the upper third or half of the area causes winking, or closure of the eyelids, elevation of the ala of the nose, and retraction and elevation of the angle of the mouth. This may be termed the *upper face-centre*.

* Compare FERRIER, 'Roy. Soc. Proc.,' vol. 23, 1875.

† A lesion of the ascending frontal portion of this centre, producing paralysis of the hand and forearm, is shown by FERRIER in 'Functions of the Brain,' 2nd edition, fig. 113, p. 351.

‡ The arm-area has, since our experiments, been carefully investigated by Dr. C. E. BEEVOR in conjunction with Professor HORSLEY. The results at which they have arrived, and which are generally confirmatory of those here given, have been already communicated to the Royal Society.

Excitation over the lower third (*lower face-centre*) is accompanied by varying movements of the jaw and tongue, some of them being very like those of mastication. As a rule excitation of the posterior part of this centre is accompanied by retraction, of the anterior part by protrusion, of the tongue* in combination with movements of the mouth generally. On the other hand, if the electrodes are applied in the middle of the centre, alternate movements of protraction and retraction may be obtained.

At the lower end of the ascending parietal gyrus, and extending in some instances to the lower end of the ascending frontal, is a centre, excitation of which causes the mouth to be opened, accompanied by retraction of the tongue and of the lower lip, and sometimes a bending of the head to the side. This is due to contraction of the *platysma myoides*. Its action is sometimes produced over a considerable part of the face-area, but always most markedly along that part of the area which lies behind the lower end of the fissure of ROLANDO.†

The *head-area* or *area for visual direction* comprises an oblong portion of the surface of the frontal lobe, extending from the margin of the hemisphere, round which it dips for a short distance, outwards and somewhat backwards to the upper and anterior limit of the face-area. Posteriorly, it is bounded by the arm-area, and in front by the non-excitabile portion of the lobe. It extends, therefore, in front as far as the extremity of the precentral sulcus, and it includes the middle part of the frontal lobe above the antero-posterior limb of that sulcus, the part included in the angle formed by the antero-posterior and vertical limbs of the sulcus, and perhaps a small portion of the ascending frontal gyrus, close to the vertical limb of the same fissure. The effects produced by excitation of this area are similar to those described by FERRIER as resulting from excitation of the rather more limited area marked 12 in his diagrams, viz., opening of the eyes, dilatation of the pupils, and turning of the head to the opposite side, with conjugate deviation of the eyes to that side. If the electrodes are applied near the angle of the precentral sulcus, the ears are frequently also strongly retracted.

Besides these three main areas, which occupy the greater part of the excitable region of the external surface, portions of two other areas, one concerned with movements of the lower limb, and the other with movements of the trunk, occupy a part of this surface close to the great longitudinal fissure, although their main parts are found upon the marginal gyrus. The *leg-area* is partly situated upon the mesial surface of the hemisphere, where its limits will be presently pointed out, but it also extends, as we have just explained, over the margin, occupying a strip of the external surface from the parieto-occipital fissure nearly to the level of the anterior end of the small

* As mentioned by FERRIER for his centres (9) and (10), 'Functions of the Brain,' p. 242.

† Since our experiments, Dr. FELIX SEMON, working in conjunction with Professor HORSLEY, has found that the lower end of the ascending frontal gyrus anteriorly is also excitable; an effect being produced upon the glottis by its excitation, viz., to bring about phonatory closure of the vocal cords. A similar centre was discovered in the Dog by H. KRAUSE.

sulcus *x*. In front and externally it approaches the arm-area, and excitation along the line of junction of the two causes the combined forward movement of the arm and leg which FERRIER has described.*

The muscular contractions which are produced by excitation of this strip vary according to the place of application of the electrodes, but they are generally such as to produce flexion of the joints of the lower limb. Behind the upper end of the fissure of ROLANDO the excitation takes effect chiefly upon the ankle and digits, producing most commonly flexion of the foot with either flexion or extension of the digits—most commonly the latter (especially near the posterior extremity of the area). In front of the upper end of that fissure flexion of the foot and movements of the toes are still very common, but the most marked movement is flexion of the leg at the knee, caused by strong contraction of the hamstrings, with the addition, when the electrodes are applied still more anteriorly, of flexion at the hip, so that the whole limb is now brought forward under the abdomen.

The *trunk-area*, unlike the last, scarcely, if at all, extends over the margin to reach the external surface. We have occasionally obtained movements of the trunk when the electrodes have been applied between the sulcus *x* and the margin, but have much more often obtained a negative result as regards the spine and abdominal muscles, movements of the leg at the hip and of the arm at the shoulder being generally the only effect produced. The movements of the tail, which FERRIER describes as being produced by excitations applied over the situation of *x*, we have not obtained at this point.

Results of excitation of the marginal convolution.—As we have already stated in a preliminary communication to the Royal Society,† electrical excitation of the marginal convolution in Monkeys is followed by various movements of the limbs or trunk according to the part stimulated. Excitation of this convolution in the prefrontal region yields no result. But if the electrodes be applied about opposite the anterior end of the corpus callosum, especially close to the margin of the hemisphere, the movement of the head and eyes characteristic of excitation of FERRIER'S centre (12) may be obtained (extension of the *head-area*, *vide antea*, p. 8, and Diagram II.). A little behind this point well-marked movements of the opposite arm are observed. They occur chiefly at the shoulder, and consist usually of retraction of the scapula and adduction of the arm to the side, but are frequently combined, especially when the electrodes are applied more anteriorly, with movements at the elbow (flexion or extension, more commonly the former), and more rarely with extension of the hand. This portion of the marginal convolution forms, therefore, an extension over to the mesial surface of the hemisphere, of the large *arm-area* of the external surface (*vide antea*, p. 6). Opposite the level of the anterior extremity of *x*, contraction of the

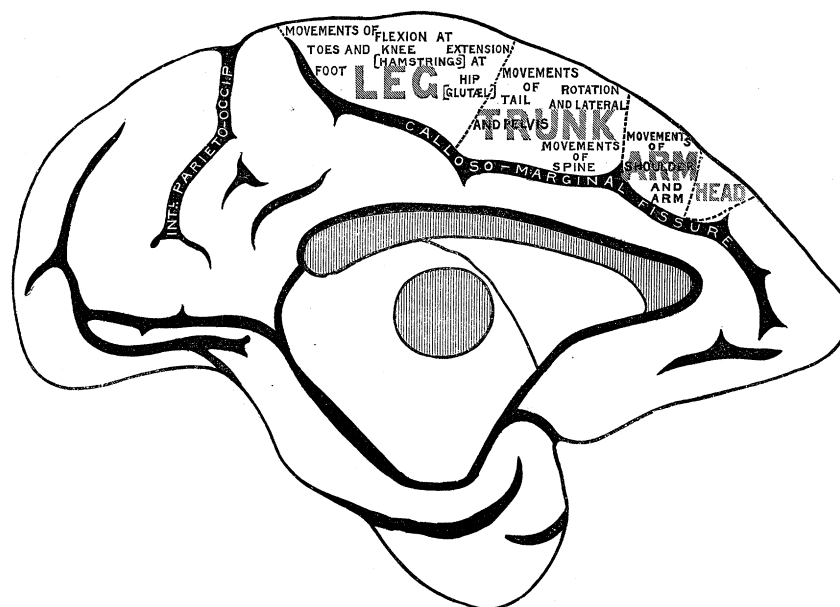
* 'Roy. Soc. Proc.,' vol. 23, 1875.

† HORSLEY and SCHÄFER, "Experimental Researches in Cerebral Physiology.—I. The Functions of the Marginal Convolution," 'Proceedings of the Royal Society,' vol. 36, 1884, p. 437.

muscles moving the upper part of the trunk may be produced, causing a rotation and arching of the dorsal spine (the convexity to the opposite side), but the effect frequently extends also to the lower part of the spine. Superiorly some of the muscles which pass from the spine to the scapula may also be thrown into action, and inferiorly some of those which pass from the pelvis to the lower extremity, especially the *glutæi*.

But the effects upon the lower spine and hip muscles more often result from excitation at a point a little further back, about opposite the posterior end of the furrow α . Excitation of this point also almost invariably produces, besides the rotation and arching of the lower spine and the pelvis and extension of the hip, which have just been mentioned, movement of the tail to the opposite side and flexion at the knee, the last-named movement being caused by contraction of the hamstrings.

Diagram II.



At a point slightly farther back, opposite the upper end of the ascending frontal convolution, the flexion of the knee is the most constant result of excitation, but it is often combined with eversion of the foot, and sometimes with flexion of the foot.*

Finally, at the posterior extremity of the convolution, we have usually obtained as the primary result of a weak excitation flexion of the foot and extension of the toes, but other muscles of the leg and foot than those concerned in these movements, and especially the hamstrings, may also be brought into action.

Looking, as a whole, at the results of stimulation of the excitable portion of the marginal gyrus, it would appear that the application of the electrodes at successive points from before backwards produces (1) movements of the head; (2) of the forearm and hand; (3) of the arm at the shoulder; (4) of the upper (dorsal) part of the

* By "flexion of the foot" dorsal flexion is meant.

trunk ; (5) of the lower (pelvic) part of the trunk ; (6) of the leg at the hip ; (7) of the lower leg at the knee ; (8) of the foot and toes.* The part which is concerned with the rotation of the head is very small, and close to the margin ; it belongs to the large *head-area* of the external surface. The part concerned with movements of the upper limb, which is, as we have already stated, a portion of the *arm-area*, extends back upon the gyrus marginalis to about the level of the anterior end of the sulcus *x*. Then comes a small portion of the convolution, excitation of which is followed by movements of the trunk muscles, causing rotation and arching of the spine. This may be termed the *trunk-area*. It overlaps the arm-area in front and the leg-area behind, and about corresponds in length with the sulcus *x*, being seldom more than half-an-inch in length. In some cases it appears to extend a short way over the margin towards *x*. It is certainly not a little remarkable that the numerous and powerful muscles of the spine should be governed from so small a portion of the cerebral cortex, but it is to be remembered that the movements of which the spine is capable are comparatively few and simple. All the rest of the convolution, from about the level of the middle of *x* to the posterior limit of the gyrus, forms, together with the corresponding strip upon the external surface, the *leg-area*.

In this marginal portion of the leg-area, as in the external portion, we can distinguish between the movements caused by excitation of successive parts from before backwards. When the electrodes are applied to the anterior part the most marked movement usually obtained is at the hip joint, but here it is a movement of extension instead of the flexion produced by excitation of the corresponding part of the external portion of the area. It is usually accompanied by extension or lateral movement of the tail. The movements in question are obviously caused in chief part by the glutæi muscles, and this anterior end of the marginal leg-area may be distinguished as the *glutæus-centre*, but the hamstrings are also usually thrown into contraction at the same time. Next comes a part, opposite the upper end of the ascending frontal gyrus, excitation of which is followed by well-marked action of the hamstrings, either alone or accompanied by contraction of the calf-muscles and peronæi. This is, therefore, an extension of the *hamstring-centre* of the external surface. It overlaps the glutæus-centre in front, and the succeeding centre behind. Lastly, the movements most characteristic of excitation of the posterior part of the area are similar to those caused by excitation of the corresponding part of the external surface, viz., movements of the foot and toes ; flexion of the foot and extension of the toes being those which we have most frequently obtained. They are often accompanied by flexion at the knee, due to hamstring action. This part of the leg-area may, therefore, be distinguished as the *foot-centre*.†

* The movements here mentioned are the primary movements, but, as will be seen from the previous description, they are almost invariably complicated by secondary movements, which are usually the primary movements produced by excitation at the adjacent parts.

† The part of the marginal convolution which is concerned with movements of the leg and foot is that portion which is often known as the *paracentral lobule*.

Results of ablation of the external motor areas.—The experiments of FERRIER, both alone and in conjunction with YEO, have yielded distinct and conclusive results from the removal of the excitable areas upon the external surface. But we have found it necessary to repeat some of their experiments partly for the sake of contrasting the effect of removal of these areas with that of removal of those upon the mesial surface; and partly to put to the test the statements of SCHIFF, MUNK, LUCIANI, and other experimental physiologists regarding the sensory functions of these areas.

We have accordingly performed a certain number of experiments involving more or less complete removal of these motor areas, and in some we have at a later period followed this up by removal of the mesial areas as well. In other experiments we have first removed the mesial areas and subsequently those of the external surface. In one or two instances we have cut away the whole of the motor cortex at one operation, but, although the hæmorrhage from this operation need not be excessive, the prostration and shock which accompany the sudden production of such a complete condition of unilateral paralysis* as results from this extensive lesion has in all our cases been so great that the animal has invariably succumbed within a very short period after the operation (seven or eight days at the utmost). The extraordinary degree of shock which accompanies this absolute hemiplegic condition is well exemplified in the case of a large, strong, tame Jew Monkey, from the left side of whose brain had been removed, by three successive operations spread over a period of several months, the occipital lobe, the prefrontal lobe, including a portion of the head-centre, and nearly the whole of the temporo-sphenoidal lobe, including the greater part of the hippocampus major. From all these operations, involving collectively, as they did, the removal of at least one-half of the whole cortex cerebri, recovery was easy and rapid; and, apart from a certain amount of hemiopic disturbance of vision, and a slight degree of facial paralysis (due probably to an accidental lesion in the face-area), was unaccompanied by any permanent symptoms whatever. But on removing the rest of the cortex, comprising the angular gyrus, the motor areas of the external surface, and the gyrus marginalis (but not the gyrus fornicatus), although the amount of brain substance removed was considerably less than in the other operations, the shock and prostration were so severe as to cause death within a few hours. (See 'Record of Experiments,' Case 24.)

The symptoms produced by removal of the external motor areas alone, including that part of the leg-area which extends over the margin, are almost complete paralysis of the opposite arm, facial paralysis, paresis of the leg-muscles, chiefly involving the flexors of the hip and ankle and the extensors of the toes, and greater or less inability to rotate the head to the opposite side. But the trunk-muscles are unaffected, and

* The hemiplegia which is produced by the complete removal of the whole motor cortex involves not only the limbs and face, but the whole opposite side of the trunk. In speaking of such a hemiplegic condition as distinguished from that which involves only the limbs, we shall in future use the term *complete or absolute hemiplegia*.

the paralysis of the lower limb is not sufficiently marked to prevent the animal from using it in the ordinary movements of walking and climbing, although there is distinct and permanent lameness in progression.

We have not performed this ablation bilaterally, nor have we made more than one or two experiments upon the effect of ablations of localised portions of the external surface. Such as we have done, however, afford strong confirmation of the results obtained by electrical excitation. Thus we have found that removal of that part of the ascending parietal gyrus, excitation of which causes movements of the wrist and fingers, is followed by permanent paresis of those parts, the function of no other part of the body being interfered with. And the removal of the arm-area produces paralysis of the opposite arm without any accompanying paresis of face, head, trunk, or leg. Nor does there appear to be any real recovery from the paralysis which may have been produced by the lesion, although in all lesions of the motor areas, when any portion of an area is left, it may happen that the muscles which are governed from that portion may by practice succeed in imperfectly reproducing some of the movements which are ordinarily produced by the paralysed muscles. The effects of ablation of the motor cortex upon sensibility will be referred to later on.

Results of ablation of the marginal gyrus.—The results of *bilateral* ablation of the marginal gyrus from the level of the anterior extremity of the corpus callosum to the posterior termination of the convolution just behind the level of the upper end of the furrow of ROLANDO is, considering the relatively small extent of the cerebral cortex thus destroyed, most remarkable. The operation is followed by complete paralysis of the trunk-muscles, some paresis of the arms, and very extensive paralysis of the muscles of the legs. The paresis of the arms chiefly affects some of the shoulder-muscles, especially those which retract and at the same time elevate the scapula; it is less marked in the case of the muscles of the upper arm and fore-arm, and hardly, if at all, perceptible in those moving the fingers. The paralysis of the leg extends to almost all the muscles, both those which are intrinsic and those which connect the limb with the trunk, with the exception of certain flexors of the hip—probably the iliopsoas and the tensor vaginæ femoris. The attitude and general appearance of a Monkey in which this double lesion has been produced are very striking (fig. 20, Plate 3). Instead of sitting up with back somewhat curved, in the manner normal to Monkeys, an animal which has been submitted to this operation lies prone, with legs and feet outstretched (or at most with flexed hips), back flat, tail straight and motionless, and arms put forward to clutch at any neighbouring object. The head retains its power of rotation as well as flexion and extension, and the movements of the eyes and facial muscles appear normal. The animal frequently props itself upon its elbows, but never assumes the normal sitting attitude. If the Monkey desires to sit up, it can only do so by dragging itself into the sitting posture by its arms and hands, and holding on by these to the wires of the cage or to any neighbouring object. If the hold be detached, the animal immediately tends to fall over. Progression is effected

almost entirely by the arms, the Monkey dragging itself along with the aid of these, assisted by the flexion which occurs at the hips ; the legs are quite limp and draggled, the dorsal surface of the toes being drawn over the ground.

This ablation, although involving a more limited removal of the skull-cap, and a smaller cerebral injury than almost any other operations that we have undertaken, and although it can be performed with very little hæmorrhage and disturbance of the cerebral circulation (for the veins which are passing from the external surface to the longitudinal sinus can generally be avoided without the necessity of cutting or tying them), is nevertheless followed by much more considerable shock than any other lesion, even of much greater extent. Indeed it is difficult to keep an animal, on which the bilateral operation has been performed, alive for more than a few days, even although it may be got to feed fairly well, for diarrhœa is apt to supervene, and the animal soon gets emaciated and dies. Out of four cases in which we have performed the bilateral operation at one sitting, two died, in spite of every care, on the eighth day, and the other two survived only three or four weeks. But even in these last cases there was no recovery from the paralysis, although the animals learned to get about and even to climb the wires of the cage quite readily with the use of their arms, the legs being always used merely passively as props.

The results which follow *unilateral* removal of the gyrus marginalis are perfectly well marked, but far less striking. This arises from the fact that the animal is able to assume and maintain a nearly normal attitude; a result due, no doubt, to the action of the muscles upon the one side of the spine being sufficient for this purpose. Rotation of the trunk to the side opposite to the cerebral lesion appears, however, to be deficient, and paralysis of the opposite leg is always very distinct; the foot and leg hanging down when the animal is seated upon a perch, and remaining passive when the animal is taken up by the shoulders and somewhat rapidly lowered to the ground. Under these circumstances a normal Monkey will always extend the hip and put down the foot to meet the ground, but in cases with a unilateral lesion of this description it is only the foot which is upon the same side as the cerebral lesion which is thus lowered. The hip can, however, be freely flexed, and the paralysis of the leg-muscles does not appear to be nearly so well marked when only one side is involved as it is after the performance of the double operation. Indeed, while the animal has been running and climbing, it is difficult to distinguish the paralysed side. It is certain that such constantly recurring actions as walking and running, to which, in the case of the Monkey, we may add climbing, may by habit almost cease to lose their distinctively voluntary character, and it is conceivable that they may be often carried on by the action of the lower nerve-centres in the cord and medulla oblongata after having been started by that of the higher centres in the cerebral cortex. But it must be admitted that when the paralysis of any true voluntary movement which has been produced by ablation of a part of the cerebral cortex is complete and extensive it is in most cases not followed

by recovery ; and it is not impossible that in those instances in which recovery seems to occur the permanent injury has been less complete than was at first supposed from the effects exhibited, but has been temporarily extended by the disturbance produced in the neighbouring grey matter by the operation.

We have performed the operation of removing the grey matter of the gyrus marginalis of one side of the brain, at least of its posterior two-thirds or more, in eight cases, and in some of these, after a lapse of time, varying from a few days to several weeks, it was followed by a second operation for the removal of some other portion of the motor cortex.

Conclusions and remarks.—The results of ablation in the motor regions of the cortex afford very direct corroborative evidence regarding the functions of those regions which are deducible from the effects of excitation. This is already perfectly well known so far as regards the areas of FERRIER upon the external surface, and our experiments on the ablation of these areas are so far only confirmatory of those of previous observers. They show, however, in addition, that in order that the hemiplegia or paraplegia which is produced by cortical ablation shall be complete it is necessary to include the part of the marginal gyrus corresponding in longitudinal extent to the excitable areas of the external surface, and indeed that the amount of paralysis produced by ablation of the marginal gyri alone is as great as, or even greater than, that caused by removal of the much more extensive external areas. But, on the other hand, the *complexity of the muscular movements* which are governed from these areas, including as they do most of the movements of the arm and fingers, and of the face and head, is evidently much greater than in those which are governed from the marginal gyrus.

Effects of ablation of the excitable areas of the cortex upon sensibility.—It is much more difficult than would at first sight appear to determine in animals whether a part in which motor paralysis has been produced by a lesion of the cerebral cortex is deficient in sensibility. For, on the one hand, the subject of the experiment no longer possesses the power of voluntarily withdrawing the irritated part, and thus the most obvious indication of perception of sensation is necessarily absent, while, on the other hand, there is the possibility of an involuntary or reflex response which might without due care be taken to indicate the continued existence of sensibility. It is, however, undoubtedly the fact that in our cases of cerebral lesion producing paralysis of voluntary motion reflex movements of the paralysed part are produced with great difficulty and require a powerful stimulus ; from which it would appear that the inhibitory action exercised by the brain over reflex movements is not only not removed by a lesion of the cortex which is accompanied by loss of power voluntarily to produce contraction of the muscles, but is on the contrary markedly increased by such lesion.

We have seen sufficient, however, to convince ourselves that a lesion of the cortex which produces paralysis of voluntary motion in a part is not necessarily accompanied

also by loss of general sensibility of the paralysed part. At the same time there is often undoubted diminution of reaction to stimuli of various kinds (touch, prick, hot wire, electric shocks), but it is impossible to say how far this may indicate a corresponding diminution of sensibility. Monkeys present very great differences in the degree to which they exhibit emotion, some being habitually dull and stupid, while others are lively and mercurial in temperament. In those belonging to the former class it is often difficult to elicit any information from the expression of the face, so that an irritation of the paralysed limb, insufficient to cause general movement of the body, does not provoke any indication of perception. On the other hand, in lively Monkeys we have often obtained, as the result of even slight irritation of paralysed parts, unmistakable signs of perception, and in cases of this kind in animals one positive observation must be regarded as of greater importance than many negative statements. But in dealing with questions of sensibility the results of experiments upon animals must always be to a certain extent unsatisfactory, since we can obtain no evidence of the actual character of the sensation provoked. Fortunately it is probable that the elucidation of this question by careful observations of cases of cerebral injury in Man will not long be wanting.

Difficult as it is to decide in animals questions relating to the general and tactile sensibility of a limb deprived of voluntary motion, it is yet more difficult to form any opinion regarding the presence or absence of the so-called muscular sense. It was the opinion of HITZIG that a lesion of the motor cortex effected an abolition of the muscular sense of the part paralysed, and he inclined to regard the paralysis as produced rather in consequence of the loss of this directive sensation than immediately by removal of motor nerve-cells. This mode of viewing the question and of explaining the facts of experiment has been adopted and ably advocated by BASTIAN, who brings forward a large amount of evidence derived from pathological observation in its favour.* FERRIER, on the other hand, appears to admit only the direct production of motor paralysis, and is disposed to localise all kinds of sensibility, including the muscular sense (which he regards as entirely derived from indications conveyed by nerves of ordinary tactile sensibility) in other regions of the cortex than those connected with the production of voluntary motion; while others, again, amongst whom SCHIFF and MUNK are to be included, endeavour to show that, while from one set of nerve-cells of the excitable regions of the cortex the fibres which convey voluntary impressions may directly arise, other cells of the same regions, indirectly connected with the first set, may serve as the terminal organs of the nerve-fibres, which convey sensory impressions, general, tactile, and muscular, and may transfer these centrifugal impressions to cells which give origin to the fibres of the motor tract. And it would appear that, in connection with this view, those who advocate it are for the most part

* 'Brain as an Organ of Mind.' See also his article on Motor Centres and the Muscular Sense in a recent number of 'Brain.'

of opinion that it is the superficial layers of smaller cells of the grey cortex that are immediately connected with the sensory tracts, and the larger cells of the deeper layers of the cortex that give origin to the fibres of the motor tract.

In order to test this last opinion, we in one instance endeavoured to destroy, by searing the surface of the excitable region of the brain with the actual cautery, the superficial part of the grey matter, while leaving the deeper layers of nerve-cells intact. In spite of the complete blocking of the superficial vessels which is produced by this treatment, we obtained only an incomplete muscular paralysis as the immediate result of the operation; but, although the superficial layers of the cortex must have been destroyed, there was no diminution of sensibility in the parts affected by paresis. The subsequent softening and disintegration which occurred in consequence of the thromboses caused by the cautery was accompanied by a much more complete condition of muscular paralysis; but the general sensibility of the opposite side was still apparently unaffected, and continued so until the death of the animal (see 'Record of Experiments,' Case 6, and fig. 6, Plate 1).

The result of this experiment, so far as it goes, is opposed to the opinion in question, but we would disclaim attaching too much importance to a single case of the kind, especially since the depth of the primary lesion could not have been uniform, and was probably much less in some parts than in others. It must be admitted that the question whether there is any localisation of sensibility, either for the muscles which are governed from the cortical motor regions or for the parts which they move, is one which can scarcely be answered by experiments upon animals, and that for its solution we must await the result of clinical and pathological observation upon Man.*

* H. MUNK ('Ueber die Functionen der Grosshirnrinde, 4te Mittheilung,' fig. 4, p. 63) has mapped out the external surface of the Monkey's brain in a manner which, in certain particulars, corresponds with the plan we have here given (in Diagram I.). Although he regards the areas in question as sensory rather than motor, the difference is merely one of terms, for the facts upon which he rests this opinion are nearly the same as those which have guided us in arriving at our results. For the author (p. 66) admits that he has found it difficult to prove that after extirpation of his so-called "sensory areas" in Monkeys there is any loss of sensibility, at least to pressure, and it seems to be a mere assumption that other forms of sensation, such as tactile sensibility and the muscular sense, are abolished. Dismissing, then, the question of nomenclature, the two plans, so far as they deal with the same regions, are strictly comparable.

On instituting such comparison, we find that our *leg-*, *arm-* and *face-*areas very nearly correspond with those of MUNK (who, however, designates as *head-region* that which we term the *face-area*, but connects it with the movements of the same parts as our *face-area* is concerned with). The main differences are to be found in the other two areas, viz., those for the trunk and head and eye movements respectively. MUNK's *trunk-region* occupies the prefrontal lobe, whilst our *trunk-area* is comprised within the *leg-region* of MUNK. We have already given our reasons for believing that MUNK is altogether mistaken in believing that the prefrontal region is concerned with movements of the trunk. The area concerned with rotation and lateral movements of the head, which MUNK designates the *neck-region*, appears far smaller than the corresponding area in our plan, and even much smaller than that given by FERRIER.

III.—LESIONS OF THE OCCIPITAL LOBES.

We have found that removal of the occipital lobe upon one side is followed, as MUNK* was the first to prove, by a condition of hemiopia; blindness being produced in the lateral half of each retina corresponding to the side of the brain which has been submitted to the operation. The blindness is at first complete. The animal takes no notice of a threatened blow directed from the opposite side, tends to knock against obstacles which lie in the way of that side, and only picks up such objects (raisins, &c.) as happen to lie upon the same side of the mesial plane of vision. In a few days, however, this condition begins to pass off: threats are avoided; large objects lying on the opposite side of the mesial plane are seen and picked up, at first with some awkwardness; and eventually it is not possible to substantiate any permanent affection of vision. We have performed this operation four times. We have removed the occipital lobes of both sides in two cases only, and in these by two successive operations, only a short interval of time having elapsed between them; one only of these two cases survived the operation for any length of time. At first complete blindness, affecting the whole visual field, was the result, but this appeared to be subsequently in great measure recovered from, although it seemed to us that there was some permanent impairment of visual perception. For, although objects were undoubtedly seen, there was much greater slowness and difficulty manifested in seizing them. This was the case at least with such a small object as a currant upon the floor, the animal often fumbling about for a moment or two in the attempt to pick it up. More conspicuous objects did not appear to offer the same difficulty, for the animal would spring from the side of the cage on to a hanging rope with unerring precision.

In this case, in which we had removed both occipital lobes in previous operations, and after the animal had recovered its visual perceptions so far as has just been described, we subsequently cut away the cortex of the angular gyrus of one side. This lesion was followed by a return of hemiopia, which remained permanent and apparently complete until the death of the animal (from dysentery) four months later. This is the only experiment we have made upon the angular gyrus. We have also sometimes produced hemiopia in consequence of operations involving the under-surface of the temporo-sphenoidal lobe. These cases are probably to be explained by the fact that the optic radiations into the occipital lobe have been reached by the

Movements of the eyes MUNK appears inclined, but on very insufficient grounds, as it seems to us, to connect with the angular gyrus. The *ear-region* he places around the extremity of the SYLVIAN fissure.

It must be borne in mind that the plan which MUNK has drawn up has been obtained chiefly, if not entirely, by ablation, whereas ours is mainly the result of excitation. Unfortunately MUNK has not given the particulars of his experiments, but has merely stated their general tendency. In our opinion their value would be greatly enhanced, were the precise symptoms manifested during life, and the exact extent of the cortical lesion in each case, as determined by post-mortem investigation, recorded.

* 'Functionen der Grosshirnrinde—Erste Mittheilung.' 1877.

lesion.* In one or two of these instances there has occurred softening of the occipital lobe, at least of its lower part, probably in consequence of derangement of its vascular supply.

Conclusions and remarks.—Our experiments upon the occipital region, although few in number, seem to link together the conclusions arrived at by MUNK, and by FERRIER and YEO, as the result of their experiments. They indicate that both the occipital lobes and angular gyri are concerned with visual perceptions in such a manner that each occipital region is connected with the corresponding lateral half of each retina, and that a part only of the cortex of the region in question is able to take on in great measure, how completely cannot be determined in animals, the functions of the whole. This is in conformity also with the results of LUCIANI. So far as the occipital lobe alone is concerned, our observations confirm the statement of MUNK that the effect of this lesion is to produce a hemiopic disturbance of visual consciousness. But the imperfect vision which remains after removal of both occipital lobes (see Cases 25 and 26) suggests that the area which is concerned with visual consciousness is not confined to those lobes, as was inferred by MUNK, but extends over into the angular gyrus, permanent hemiopia being produced by the subsequent removal of that convolution. It will, however, be necessary that further experiments should be undertaken in order to determine more precisely, not only the extent, but also the relative importance of the anterior, posterior, and mesial portions of the visual area of the cortex.†

IV.—RESULTS OF EXPERIMENTS UPON THE TEMPORO-SPHENOIDAL LOBE AND ON THE LIMBIC LOBE.

We have in several instances effected the removal of the greater part of the temporo-sphenoidal lobe. Our object in most of these experiments was to get at the hippocampal region in order to remove or destroy the hippocampus and uncinata gyrus, a lesion which had only been performed hitherto by FERRIER, partly in conjunction with YEO, and which in the hands of those observers was followed by hemianæsthesia

* LUCIANI ("On the Sensorial Localisations in the Cortex Cerebri," 'Brain,' vol. 7) appears disposed to regard these cases as being due to injury of an extension of the visual region into the temporal lobe. But, since the main centre for vision (in the occipital lobe) is intact, one would scarcely expect hemiopia to result from the removal of an outlying part!

† A further investigation upon this region and into the parts of the cortex which are connected with other special sense functions is, in fact, now being carried on by one of us, in the hope of succeeding in clearing up some of the discrepancies in the evidence of previous observers. We may perhaps here most conveniently notice a statement which has been made by Dr. FERRIER in the second edition of his 'Functions of the Brain,' to the effect that we had removed the occipital lobes on one or both sides "without the slightest appreciable impairment of vision." It will be seen from the text, and from our Record of Cases, that this is a mistake. It appears to have arisen solely from a misunderstanding, for, whereas we informed Dr. FERRIER that we had not been able to determine that this lesion produced any *permanent* impairment of vision, he understood, it would seem, that we had not obtained any effect whatever.

more or less complete.* But, as their experiments were performed by a less exact method than that of simple excision, and since moreover in none of their experiments upon this region did the animals survive more than a few days, it occurred to us to approach the same part from the outer side after removal of the lateral portion of the temporo-sphenoidal lobe, instead of from behind through the occipital lobe, and we accordingly endeavoured in the first instance to determine what effect, if any, is obtained by removal of this portion. Our results have proved uniformly negative so far as the larger portion of the lobe is concerned. The animals have exhibited no signs of motor paralysis nor any loss of general or tactile sensibility.† We have usually left the whole or part of the superior temporo-sphenoidal gyrus and the anterior extremity of the lobe, but in one of our cases the superior gyrus was almost completely removed upon both sides, only the narrow posterior extremity, for about $\frac{3}{8}$ -inch in length, being left upon the right side. In this case the animal certainly appeared to hear quite distinctly, and so far as it goes the experiment is at variance both with the results of FERRIER and with those of MUNK. But we have not as yet systematically pursued the question of the cortical localisation of auditory sensations, although it is right to state that such incidental observations as we were able to make upon this function have almost uniformly proved negative.‡ We have not, as the result of any bilateral operation, been able to convince ourselves that deafness has been established in a single case.§ This is indeed a very difficult point to determine in many intact Monkeys, which, when their attention is attracted by other causes, will often fail to give evidence of the hearing even of loud noises, while, on the other hand, other individuals readily show that they are conscious of the slightest unusual sound.

In our earlier experiments upon the hippocampal region we were satisfied, after removing the external part of the temporo-sphenoidal lobe, and exposing the hippocampus major by opening up the descending cornu of the lateral ventricle, with removing as much of the hippocampus major as could conveniently be got at, usually

* FERRIER, 'Phil. Trans.,' 1875, and 'Functions of the Brain,' pp. 327 *et seq.* FERRIER and YEO, 'Phil. Trans.,' 1884.

† That is, after the shock of the operation was recovered from.

‡ Dr. FERRIER is mistaken in the statement ('Functions of the Brain,' 2nd edition, pp. 310, 311) that we have been able to corroborate his observations upon the localisation of this function in the superior temporo-sphenoidal gyrus in Monkeys. We have so far neither obtained any distinct corroboration nor refutation of them, but regard the question as still open; and, as we have stated in a preceding note, one of us is now engaged in a further investigation regarding the localisation of this and other special sense functions. The same statement will also hold good with regard to the localisation of olfactory and gustatory sensations. Unilateral lesions are probably of but little value in elucidating these functions; at least, we have been unable to obtain any determinate results from them.

§ It is right to add that we were not specially intending to investigate this point (the localisation of auditory perceptions), and that the lesions of this lobe which we record were performed with another object, *viz.*, to arrive at the hippocampal region. But, as we have been careful to note all the symptoms that we could observe, they are not without their value on this point.

about three-quarters of an inch, and the adjoining portion of the uncinate convolution. Such removal, although effecting an extensive lesion in this region, produced, however, no effect, so far as we could determine, upon the sensibility of the opposite side of the body, such as we had been led to expect from the experiments of FERRIER would have been the case. On communicating this result to Professor FERRIER, he suggested that the difference probably arose from the smaller extent of the lesion, especially of the uncinate gyrus, as compared with the cases published by him; and we accordingly in further experiments endeavoured to effect a more complete removal of that convolution as well as of the hippocampus itself. The result of this was that in many cases there was produced, as FERRIER has described, a unilateral diminution of sensibility affecting the whole of the opposite side of the body. This condition of hemianæsthesia, although fairly well marked, was in our experiments never complete, nor was it permanent; and, indeed, in most instances it was found to have disappeared within a week of the operation. Since even with a tolerably extensive lesion in this region we were not always able to substantiate the fact that there was a diminution of sensibility produced, at least on testing the animals some hours after the operation, and since also, when a distinct effect was obtained, it was comparatively transient, it was difficult to be certain that the result yielded by the operation was really due to the removal of a part of the cortex connected with the consciousness of sensations, and might not be otherwise explained, as we have previously pointed out, by a disturbance of the function of other parts, which must always be produced by any extensive cerebral lesion; and this explanation seems at all events as reasonable as one which assumes that it is exclusively the region in question which is concerned with the appreciation of tactile and painful sensibility. Another explanation is, however, possible, and would equally well fit in with the facts which we have to record. For, as we shall immediately show, the gyrus fornicatus is certainly connected with the sensibility of the opposite side of the body. Now the gyrus fornicatus is anatomically to be regarded as a direct continuation of the gyrus hippocampi (the two constituting the great limbic lobe of BROCA).* It is probable, therefore, that the functions of the two are similar, and possible that, as in the case of the visual sensory area, after removal of a part, the remainder of the area can carry on, more or less efficiently, the functions of the whole. But, before discussing this possibility further, we will describe the results we have obtained from lesions of the gyrus fornicatus.

Experiments upon the gyrus fornicatus.—We have endeavoured to remove the cortex of the gyrus fornicatus by exposing freely the upper surface of the hemisphere, drawing the brain gently away from the falx with retractors, and bringing to view the convolution in question, which could thus, with some difficulty it must be admitted, be got at and cut away to a greater or less extent by the aid of a specially constructed curved knife. We have operated in this way upon the gyrus fornicatus

* In the Kangaroo, as BEEVOR has shown, the microscopic structure is identical in both the gyrus fornicatus and gyrus hippocampi.

in a number of Monkeys, and, although we have never succeeded in effecting a complete removal of the grey matter of the convolution—indeed, from the depth at which it is situated this is scarcely possible without injuring neighbouring parts or producing fatal hæmorrhage—we have in several instances removed or destroyed considerable portions without lesion to other parts, or with but a small injury to the marginal gyrus, the effect of which, from our previous experiments upon this region, could be readily discounted. As the result of these experiments, we have found that any extensive lesion of the gyrus fornicatus is followed by hemianæsthesia more or less marked and persistent. In some cases the anæsthetic condition has involved almost the whole of the opposite side of the body, in others it has been localised to either the upper or the lower limb and to particular parts of the trunk, but we have not yet succeeded in establishing the relationship between special regions of the body and the parts of the convolution which have been destroyed. Moreover, the anæsthesia was frequently very pronounced and general during the first three or four days after the operation (and indeed in several instances took the form of complete insensibility to both tactile and painful impressions, so that even a sharp prick or the contact of a hot iron would produce no indication of sensation), but after that time this general condition would become gradually in great part recovered from, or more localised in definite regions. In all cases, however, in which the diminution of sensibility was well marked during the first few days, it has persisted, although with lessened intensity, for many weeks in those instances in which the animals have been preserved for so long. In other cases, in which apparently the lesion was slight, the diminution of sensibility, although at first well marked, subsequently disappeared entirely. In some instances the hemianæsthesia took the form of inability (or a diminution of ability) to localise the seat of irritation, whilst in one case, in which diminution of sensibility was exhibited in a very striking manner, the irritation, when rendered sufficiently intense for the Monkey to become conscious of it, was responded to by the animal scratching a different part of its body from that to which the stimulus was applied.

These experiments were frequently, but by no means in every case, complicated by the presence of a certain amount of motor paralysis, chiefly, if not entirely, affecting the muscles of the leg. We have no doubt that this condition was always due to a lesion (accidentally produced during the operation, or subsequently, as the result of interference with the circulation) in the leg-area of the marginal convolution. Now in one or two of these cases the anæsthesia affected chiefly the pàresed limb, and it might therefore be argued by those who, like SCHIFF and MUNK, hold that the excitable areas of the cortex are concerned with the perception of sensory impressions from the corresponding regions of the body that the loss of sensibility was due to the lesion of the motor area. But against this argument we may not only put orward those experiments in which there has been no accompanying paralysis, but also others in which the hemianæsthesia has been well marked in the upper limb and

upper part of the trunk, while the lower (pared) limb has exhibited no diminution of sensibility whatever.

We have performed a few experiments in which we endeavoured completely to destroy, upon the same side of the brain in successive operations, both the hippocampal convolution and the gyrus fornicatus, *i.e.*, the whole of the limbic lobe. Although we cannot claim to have fully succeeded as yet in this attempt, having been foiled by the extreme difficulty of getting at all portions of this lobe, our results have not been devoid of interest. They have tended to show that, while a lesion of either the hippocampal gyrus or of the gyrus fornicatus alone produces, as the experiments of FERRIER have shown for the former convolution—and our own, just alluded to, for the latter—a more or less marked diminution in the power of appreciation of sensory impressions applied to the opposite side of the body, the part played by the gyrus fornicatus is of greater importance in this respect than that played by the hippocampal convolution and hippocampus. For when even a considerable lesion has been made in the hippocampal region the resulting hemianæsthesia is not always very well marked and is not long persistent. If, however, this is now followed by an extensive lesion of the gyrus fornicatus, the hemianæsthesia is very well marked and long persistent. On the other hand, when the operation has first been performed upon the gyrus fornicatus, the anæsthetic condition is, as we have seen, very well marked if the lesion has been considerable, and persists in a diminished form for an indefinite period. And a lesion of the hippocampal region will now produce but little increase of the anæsthesia. From which it would appear that, although the whole limbic lobe may be concerned in the perception of sensory impressions, the part played by the gyrus fornicatus, at least as respects cutaneous sensibility, is more important than that played by the hippocampal portion of the lobe. But until it has been possible entirely to destroy the whole lobe upon both sides of the brain it is impossible to determine whether it is assisted in its function by any other portion of the cerebral cortex.*

Conclusions and remarks.—The results of our experiments upon the limbic lobe seem to point to the conclusion that this portion of the cerebral cortex is largely, if not exclusively, concerned in the appreciation of sensations, painful and tactile. This is an extension of the view put forward by FERRIER, who was inclined, as the result of his own experiments, to limit that function to the hippocampal region. Dr. FERRIER, who was good enough to assist at some of our experiments upon this part, has fully accepted the conclusions to which they point.† These conclusions appear, however, completely incompatible with the views of most of our predecessors in the field of experimental cerebral research. Of these predecessors we need now refer only to GOLTZ, SCHIFF, and MUNK. With reference to the views of GOLTZ, we may remark

* It is important here to remark that the possibility of an accidental lesion of the ascending sensory tracts, which has sometimes been put forward as an objection to the anæsthesia obtained by FERRIER from lesions in the hippocampal region, is altogether absent in the case of a lesion of the gyrus fornicatus.

† 'Functions of the Brain,' 2nd edition, pp. 341 *et seq.*

that the evidence of the exact localisation, in a particular region—and that a comparatively limited one—of the cerebral cortex, of a function so universally distributed over the body as common sensation, affords the strongest corroboration of the evidence already accumulated on the question of cerebral localisation by the demonstration of the localisation of speech, of voluntary motions, and of certain special sense functions in particular parts—all of which has tended to show that, in the higher vertebrates at least, such localisation of cerebral function is carried out to a remarkable and, previously to the experiments of FRITSCH and HITZIG, an entirely unsuspected extent.

As for the view, originally put forth by SCHIFF and extended by H. MUNK, which has been already referred to (p. 16), we would merely now point out that, although this portion of our researches cannot be said to have directly disproved MUNK'S hypothesis, it must yet be admitted that it has rendered that idea unnecessary. For, as we have already endeavoured to show, the only evidence in favour of MUNK'S view is the slowness of reaction of a paresed part, and this slowness of reaction may be explained otherwise than by the assumption of a defect in sensibility. But if without any muscular paresis we can obtain by a definite and localised lesion complete tactile anæsthesia of a limb, while by a lesion in a different part of the cortex we can produce complete muscular paralysis without any perceptible anæsthesia, the conclusion that the part of the brain involved in the first lesion is alone concerned with the appreciation of sensibility in that limb, to the exclusion of the part involved in the second lesion, seems logically irresistible.

RECORD OF CASES. (See Plates 1-7.)*

1.

Lesion.—Removal of the prefrontal part of the brain (anterior fourth of frontal lobes) on both sides at one operation.

This animal was kept alive five months, during which time no abnormal symptoms of any kind were noticeable. Careful testing showed no apparent deficiency of sensibility. The animal seemed lively and intelligent throughout.

The brain is represented, as seen from above, in fig. 1, Plate 1.

2.

Lesion.—Complete removal of prefrontal region on both sides by vertical incision. The lesion extended a little further back than in the preceding case. The orbital part was included in the removal, but the olfactory tracts were left.

* With one or two exceptions, the post-mortem condition of the brain in each case is represented with the exact superficial extent of lesion marked out by darker shading. The numbers attached to the figures correspond with the numbers of the cases in the record. In some instances sections of the brain are also given to show the deep extent of the lesion. Most of the drawings were made for us by Mr. E. P. FRANCE, Assistant in the Physiological Laboratory, and we can answer for their fidelity. Mr. FRANCE has also executed casts of the brains: these casts we have deposited in the Museum of University College.

Result.—No perceptible permanent symptoms were produced. This animal was kept nearly three months. The brain is represented in fig. 2, Plate 1, as seen from above.

3.

Lesion.—The same as in the previous case.

This animal did not properly recover from the result of the operation, for death was caused on the sixth day apparently by compression of brain from accumulated serous fluid. Up to the fourth day no abnormal symptoms were presented (with the exception of the peculiar attitude before mentioned as characteristic of these lesions (p. 3), which was exhibited also for the first few days by Monkeys 1 and 2).

The brain is represented in fig. 3, Plate 1, as seen from above.

4.

Lesion.—Left ascending frontal and ascending parietal gyri removed by galvanic cautery,* except the lowermost part. The ablation includes also most of the parietal lobule and a part of the superior frontal convolution.

Result.†—Right arm is kept flexed at elbow, and adducted and rotated forwards at shoulder.‡ Hand hangs down with fingers nearly straight; no movements of hand. Slight movement possible at elbow (re-flexion after being straightened) and at shoulder joint. Right leg is kept flexed at hip, knee, and ankle; some amount of movement is possible at all these joints. Toes remain semiflexed. It is difficult to detect facial paralysis, but the right cheek pouch cannot be emptied without the assistance of the hand or by being pressed against the shoulder. No paralysis of trunk perceptible. No impairment or paralysis of head-movements was noticed. Lived four months after operation. Death from diarrhœa.

The brain of this Monkey is shown in fig. 4, Plate 1.

5.

Lesion.—Of very nearly the same character and extent as in 4, but upon the right side of the brain.

The *symptoms produced* were almost exactly the same as in 4, except that there was much less paresis of the leg-movements. When in active motion, all four limbs may occasionally be used, but the movements of the left arm are very imperfect, and

* In this and a few other experiments the cautery was used to effect the removal of the cerebral substance. In all other cases we simply cut the part away with a sharp knife.

† In all cases, unless otherwise expressly stated, the symptoms which are given are those which are manifested after recovery from the immediate effects of the operation and complete healing of the wound involved in performing it. In all cases also it may be assumed that the symptoms persisted until the death of the animal, unless the contrary is noted.

‡ This position may have been due to contracture.

ordinarily this limb remains flexed and motionless. The hand and fingers are paralysed. Very little, if any, paresis of face-muscles. No paresis of trunk or of head-movements was detected.

Lived two months after operation. Cause of death doubtful; probably chill. In this Monkey the lesion was found on post-mortem examination to involve a strip of the angular gyrus, but no symptoms affecting visual perceptions were noticed during life.

The condition of the brain is shown in fig. 5 as seen from above, and in fig. 5A as shown in section, the section passing through the middle of the lesion. It is seen from the section that the whole thickness of the grey matter was completely removed over the area operated upon. Just at this point the marginal gyrus is somewhat encroached upon by the cut made into the white matter, but in other parts it was not touched.

6.

Lesion.—In this Monkey the motor region of the external surface on the left side was touched quite superficially with the actual cautery.

Result.—The motor paralysis for the first three or four days was not nearly so complete as after excision or deep cauterisation, but afterwards became more complete. There was no perceptible difference of sensibility on the two sides of the body.

The animal only survived the operation a few days. After death the grey matter under the cauterised surface was found to be considerably disorganised, and sections through the hemisphere revealed the presence of numerous infarcts in the subjacent white substance.

The brain is represented as seen from above in fig. 6, Plate 1, and in section through the lesion in fig. 6A.

7.

Lesion.—The whole of FERRIER'S areas in front of the fissure of ROLANDO were removed in this Monkey, the lesion extending nearly to the margin above, as far as the fissure of ROLANDO behind, and in front and below as far as an oblique line connecting the antero-superior extremity of the precentral sulcus with the lower end of the ascending frontal gyrus.

Result.—The only symptom exhibited up to the 7th day after the operation, *i.e.*, previous to the occurrence of the unfavourable conditions mentioned below, was paralysis of the opposite arm muscles below the shoulder, without contracture. No paralysis could be detected in the trunk, leg, or in the face.

This animal went on well until the eighth day, when the skin began to slough, and eventually hernia cerebri occurred, producing death on the nineteenth day. This brain is not represented, as the accurate mapping out of the lesion was prevented by the occurrence of hernia.

8.*

Lesions.—In this animal a lesion had been established in the posterior part of the gyrus fornicatus on the right side, but the Monkey was at first so wild that no definite result could be obtained regarding loss of sensibility. It was therefore determined to employ it for an operation upon the motor region, and accordingly sixteen days after the first operation a lesion was effected in this part. The lesion consisted in the removal of the greater part of the motor area of the external surface on the right side.

Result.—The result of this second lesion was to cause paralysis of the left arm and paresis of the leg, with the exception of the extensor muscles of the thigh, which acted normally.

Experiments upon the sensibility of the left side were again tried, but again with very unsatisfactory results. Sometimes there was no movement caused by a stimulus applied to that side, when there would be marked movement produced on applying the same stimulus to the right side, but, on the other hand, this may well have been the result of the establishment of the motor paralysis, for on stimulation of the left side the animal, without moving away, would occasionally exhibit dissatisfaction by squeaking.

The paralysed condition was maintained until the animal was killed three-and-a-half months after the second operation.

The brain is represented in fig. 8, Plate 1.

9.

Lesion.—Excision of the middle two-thirds of the left ascending parietal gyrus, including a small portion of the parietal lobule.

Result.—The only result produced by this lesion was paresis of the fingers of the opposite hand, power of both flexion and extension being diminished.

The animal was kept two months after the operation.

The brain is represented in fig. 9, Plate 1.

10.

Lesion.—Complete removal of posterior two-thirds of right marginal gyrus.

Result.—Left foot paralysed ; the toes opposed, semi-flexed, and with hallux turned under them. Hamstrings are almost completely paralysed ; also glutæi, extension of hip being very feeble. In standing and leaping, the right leg is almost exclusively used ; when lowered towards the ground, puts down right leg, never left. Can *flex* left leg and even manage to scratch left side of trunk with it, but to scratch the left side of the neck the right hand is used. The tail tends to lie over on the right side. No other paresis observable. Can advance and flex left arm and grasp well with fingers of left hand. Can turn head to left.

* Exhibited to the Neurological Society.

This animal lived three months. The brain was unfortunately mislaid, so that we are unable to give a representation of it, but the exact extent of the lesion had been carefully noted at the time of operation.

11.

Lesion.—Removal of a longitudinal strip of grey matter on the left side of the brain along the margin of the longitudinal fissure from the anterior end of the precentral sulcus nearly to the parieto-occipital fissure.

Result.—The day after the operation there was some paralysis of both right limbs, with unsteadiness of gait. The arm, however, after a few days recovered to all appearance completely. But in the leg, although it was difficult after a time, when the animal was freely running and climbing, to obtain evidence of paralysis, yet when sitting on a perch the right leg always hangs down, and when the animal is held and suddenly lowered to the ground the right leg is not extended like the other. There also seems a deficient power of grasping in the toes of the right foot. These pareses, although not extensive, were permanent. They were not accompanied by any perceptible deficiency in sensibility.

Whilst examining this Monkey on the fourth day after the operation, on taking hold of the right arm, a fit commenced, lasting for seven or eight minutes. It began with retraction of the right arm, followed by spasmodic flexion and extension at the elbow. This was succeeded by spasmodic flexion at the hip and slight extension at the knee. Still later, the head began to turn to the right, with clonic spasms, with twisting of the body to the right, and marked arching of the spine (concavity to the right).

The animal had a similar, but shorter, fit on the morning after the operation (seen only by the attendant). None others were observed.

The brain of this Monkey is shown in fig. 11, Plate 2.

The animal lived a year after the operation.

12.

Lesion.—Ablation of the left marginal gyrus (its posterior three-fourths) and the narrow adjoining strip of the external surface extending laterally as far as the sulcus *x*.

Result.—Paralysis of right side of trunk and of right leg; partial paralysis of right arm, which seems to have a very imperfect power of extension from the shoulder.

This Monkey was attacked a few days after the operation by gangrenous œdema of the right extremities. This eventually resulted in recovery, but not before the right foot and a part of the right hand had become lost. The animal was killed six months after the operation.

The brain is represented in fig. 12, Plate 2.

13.

Lesion.—Removal of posterior two-thirds of left gyrus marginalis and a narrow adjoining strip of the external surface.

Result.—Paralysis of right leg. There also seems an inability to rotate the spine, but it is difficult to be sure of this. No other results were recorded.

This animal only lived one week, death being the result of enteritis, apparently brought on by chill (the room having been accidentally allowed to become cold). Except for the lesion, the brain was found to be perfectly healthy, without any sign of inflammation of surrounding portions.

The lesion is represented in fig. 13, Plate 2.

14.

Lesion.—Removal of the left gyrus marginalis.

Result.—Paralysis of right leg and of trunk muscles on right side, so that the upper part of the body is turned round to the left. The right arm is at first partly paralysed, but by the third day this had become scarcely perceptible. For the first three days the right side of the body and the right limbs react less readily than the left to sensory, especially to tactile, impressions, but already on the fifth day this difference is no longer to be made out.

The animal died of enteritis three-and-a-half weeks after the operation.

The mesial surface of the left hemisphere is represented in fig. 14, Plate 2.

15.

Lesion 1.—Right marginal gyrus removed from just behind the sulcus of ROLANDO as far forwards as the anterior extremity of the precentral sulcus. The lower slope of the convolution posteriorly was, however, found at the autopsy to have been left.

Result.—Paralyses not very well marked. Slight paresis of left arm; when sitting, the animal props itself up by right arm, while left arm is kept flexed and adducted. It can, however, be freely used. When standing up, the weight of the body rests chiefly on the right leg, and in springing this leg is used almost exclusively. Extension of hip is deficient (? wanting) on left side. Left toes paresed; retain some power of grasping, but greatly weakened.

Lesion 2.—Second operation, seven weeks after the first one. Ascending parietal, ascending frontal, and posterior part of first and second frontal gyri removed on same side as primary lesion. (This external part of the brain was found to be perfectly normal when exposed for operation, although in the previous operation all the veins passing from it into the superior longitudinal sinus had been tied. In most subsequent operations upon the marginal gyrus these veins were avoided and not tied.)

Result.—The immediate result of this operation was to produce *complete or absolute hemiplegia*. The right pupil was much dilated, the left contracted. The head and eyes were turned to the right, and the face was drawn over to the same side. After a few days, however, the hemiplegia appeared somewhat less complete. There was

a very slight capacity to raise the left arm, and also ability to flex the left hip, when attempting to walk. The head and eyes can now also be moved to the left. Unfortunately the skin in this case sloughed, and the wound thus became partly open and septic, with the result that the animal died the fifteenth day after the operation. The effect of the failure to maintain the antiseptic character of the wound was also apparent in the extension of the lesion, the edges and bottom of which were softened and disorganised so as to render the post-mortem condition of the brain of less value than in other cases in which no such extension occurred. We have, however, thought it worth while to reproduce the representations of it from both the outer and mesial aspects. It will be seen from these (figs. 15A, 15B, Plate 2) that the postero-parietal lobule is in part left, and also the posterior end of the marginal gyrus. The inferior border and the anterior end of the marginal gyrus also remain. Otherwise the whole of the motor areas upon the right side are destroyed.

16.

Lesion.—Removal at one operation of the marginal gyrus (its posterior three-fourths), ascending parietal, parietal lobule, ascending frontal and posterior half of transverse frontal convolutions on left side of brain. Lived seven days.

Result.—Absolute right hemiplegia, both limbs and trunk being paralysed. Head rotated to same side. Face drawn over to right. Trunk arched, with convexity to right. Right leg is dragged, right arm drops from shoulder. Can support itself only by aid of left limbs. Drinks with paralysed side of mouth immersed in the fluid. No recovery observed up to time of death, which occurred on the seventh day.

The brain is represented in fig. 16. It would appear as if part of the ascending parietal and the parietal lobule were not involved in the lesion, but in fact they were completely softened and undermined, so as to render it impossible to suppose that any part of them could have continued to perform its functions. The lesion of the marginal gyrus is very complete.

17.

Lesion.—Almost identical with that recorded of the preceding brain, but on the right side. The cortex of the whole frontal lobe, except the anterior fourth and a strip along the lower margin; the ascending parietal convolution. The lesion is more complete at the upper and lower ends of this than in the centre, where only the part next the furrow of ROLANDO appears to be involved; moreover it does not include the parietal lobule and the part of the marginal gyrus corresponding in longitudinal extent to the lesion upon the external surface.

Result.—Absolute hemiplegia, as in 16, but of course involving the opposite side of the body. The hemiplegia was absolute, although the parietal lobule and the upper two-thirds of the ascending parietal were not removed, at least intentionally. But there was a partial softening and undermining in these convolutions, probably produced by the interference with their vascular supply which was caused by the

lesion, and sufficient to account for the fact that the paralysis extended to the parts with which the convolutions in question are connected.

This animal also lived one week only.

The superficial extent of the lesion is represented in fig. 17, Plate 2.

18.

Lesion 1.—Excision of the posterior three-fourths of the left marginal gyrus. A small part of the lower edge of the convolution was, however, left, as the section of the brain shows (fig. 18A).

Result.—Partial paralysis of right leg, especially the extensors of the hip and the flexors of the knee. No determinable paralysis of trunk.

Lesion 2.—Second operation, twenty-one days later. In this operation most of the external motor areas were removed, including the anterior slope of the ascending parietal, the whole of the ascending frontal as far as the lower end of the fissure of ROLANDO, the posterior third of the superior frontal gyrus, and the part of the middle frontal gyrus included in the angle of the prefrontal sulcus. All this part of the brain was perfectly healthy when exposed for removal.

Result.—There is paralysis with contracture of both right limbs, but the hemiplegia and prostration are not so complete as in the cases previously recorded, which is no doubt due to the fact that the lesion was not quite so extensive. There is some slight ability to grasp with the fingers of the right hand, but none with the toes of the corresponding foot. There is distinct contracture at right elbow, hip, and knee; when actively climbing, the right arm and hand are occasionally employed, but not the corresponding leg. No difference of sensibility can be determined upon the two sides. The knee-jerk is normal. (These notes were made two months after the second operation.) This Monkey was kept nearly four months after the second operation.

The brain is represented from above in fig. 18, and in frontal section in fig. 18A. The section passes through the widest part of the lesion.

19.

Lesion.—Excision of both marginal convolutions (on the left side for the posterior three-fourths of the longitudinal extent, on the right side slightly less). The lesion, as shown by examination of the brain after death, does not quite reach either the upper or lower margin of the convolution, especially on the right side. It was followed by considerable shock.

Result.—Almost complete paralysis of trunk and leg muscles, but there is some ability to move, especially to flex, the legs, particularly the left leg. When placed upon the floor, the animal seizes neighbouring objects and pulls itself up into sitting posture by arms; sits propped up on both arms with feet splayed out and knees in; appears unable to extend the spine or to move the tail, but head can be flexed, extended, and rotated.

The animal died on the ninth day.

The post-mortem elicited, as is frequently the case after these lesions, the existence of dysenteric ulceration of the solitary follicles of the large intestine. The general surface of the brain was perfectly healthy, without any sign of clot or extravasation except just along the lesion.*

The hemispheres are shown, seen on their mesial aspect, with the full extent of the lesion displayed in figs. 19 R. and 19 L., Plate 2.

20.

Lesion.—Removal of posterior three-fourths of both marginal convolutions.

Result.—Complete paralysis of trunk and legs, except that the latter can be feebly drawn up under the abdomen. The Monkey assumes the attitude characteristic of this lesion (see p. 13 and fig. 20, Plate 3). Cannot sit up at all, but can drag itself about by its arms. No head or face paralysis.

Death on the eighth day, with symptoms of dysenteric diarrhoea.

The brain was sliced as a whole, so that no drawing of the superficial extent of the lesion was made, but the extent of the removal of the grey matter of the marginal convolutions is shown in section in the accompanying drawings (figs. 20A, B, C, and D), which are numbered successively from before back. It will be seen from these that it is only quite at the posterior end that any of the grey matter of these convolutions is left.

The animal itself is shown in fig. 20 (from a photograph).

21.

Lesion.—Removal of posterior three-fourths of both marginal gyri at one operation.

Result.—Paralysis of trunk and legs. The animal cannot sit up, but lies on one side, generally the right, with legs drawn up, and spine and tail stiffly flexed. This position of the trunk and limbs appears to be due to contracture of the muscles; it is most marked in the limbs of the left side. On the left side the foot is flexed, on the right it is extended; the toes are semiflexed on the right side, completely flexed on the left. When one attempts to straighten the legs or to move the tail pain seems to be caused. The arms and hands are not paralysed, and are used in progression as before described (pp. 13–14). Appetite good throughout.

Death from dysenteric diarrhoea on the twenty-seventh day. The solitary follicles of the large intestine were found after death to be extensively ulcerated.

On removing the brain a considerable clot, more or less organised, was found resting against the injured surface of the marginal convolution of the right side. Perhaps the

* Although we have only actually mentioned the healthy aspect of the rest of the brain in one or two instances, it is right that we should state once for all that in all the cases we have here recorded, unless the contrary is directly mentioned, all parts of the brain other than those destroyed in the operation presented on post-mortem examination a perfectly normal aspect.

irritation caused by this may have conduced to the strongly marked contracture of the muscles of the opposite side.

The brain was sliced as a whole, and four sections through the lesion are represented in figs. 21A, B, C, and D. These serve to illustrate the localisation and completeness of the removal.

22.

Lesion.—Removal of both marginals in two operations.

Results.—The first operation (on left side) produced the usual paralysis of the opposite hind-limb, which was dragged in progressing and hung down when the animal perched upon a bar. All the other symptoms distinctive of this lesion are also observed (see p. 14).

The second operation was performed on the eighth day after the first, the wound in the meantime having completely healed and the Monkey being perfectly well. The result of the second operation was to produce, as usual, paralysis of trunk and legs, except that the hips could be flexed and the knees extended (feebly on both sides, but more on the right side than on the left). The tail was rendered motionless. The body was propped upon and dragged forward by the fore-limbs. No deficiency in sensibility could be determined. Later, rigidity developed in both legs and in the tail, which was stiffly flexed over the spine. This Monkey was kept three months. Although its movements became much more active after some time than at first, this was due to the exercise of the unaffected muscles; there was no recovery in those in which paralysis had been produced by the operation.

The brain of this animal, which died in Long Vacation time, was injured on removing it from the skull, so that no drawings could be made to show the extent and depth of the lesion; but there is no doubt, from the notes made at the operations as well as from the symptoms, that it involved the posterior two-thirds of both marginal gyri, and was somewhat less complete on the left side than on the right.

23.*

Lesion.—Excision of both gyri marginales† at one sitting.

Result.—The usual symptoms produced by this lesion, *i.e.*, complete paralysis of trunk and almost complete of legs, but with power to flex hips. Drags itself about by arms. Unable to sit up, but props itself up by aid of arms.

The animal lived four weeks after the operation.

The lesions are represented in figs. 23 R. and L., Plate 3.

24.

First Lesion.—The whole of the left occipital lobe was removed by an oblique incision along the parieto-occipital fissure. The piece removed included the extremity of the posterior cornu of the lateral ventricle, which was thus freely opened. No

* Shown to the Neurological Society.

† That is, that portion of them shown to be excitable.

ill consequences resulted from this, however, and when on the 5th day the dressings were removed the wound was found to be completely healed.

Result.—No muscular paresis. The animal seems to have some disturbance of visual consciousness of the images of objects which fall upon the left side of the retinae, for an object, such as a raisin, presented to it on the right side of the visual line is either not noticed or its nature is not readily recognised. This condition, which was very well marked at first, gradually improved, until three months after the operation it could be no longer determined.

Second lesion.—Four months after the first operation the anterior half of the frontal lobe, including the orbital lobule, was removed upon the same side (the left) by a nearly vertical incision. The recovery was again rapid and complete.

Result.—The only noticeable symptoms which were produced by the second lesion were (1) some paresis in the opposite arm; and (2) an inability readily to turn the head to the opposite side.

Third lesion.—Ten weeks after the second operation the whole of the left temporo-sphenoidal lobe was cut away, with the exception of the hippocampal gyrus, which was, however, injured considerably. In this operation the descending cornu of the lateral ventricle was freely exposed, and the hippocampus major was excised in the greater part of its extent.

Result.—Immediately after the operation was completed there was some paralysis of the opposite limbs and defective sensibility on the opposite side of the body. But these results may well have been due to the temporary disturbance caused in the remainder of the hemisphere, by the loss of the support yielded by the temporo-sphenoidal lobe, and by the disturbance of the circulation in that half of the brain produced by the section and occlusion of many of its vessels. For, the next morning, on carefully testing for sensibility in various ways, no difference was determined upon the two sides of the body, and the paralysis of the limbs had disappeared, with the exception of the slight paresis of the upper limb, which had been left from the second operation. Vision for the images of objects falling upon the left half of the retinae was again impaired, and this impairment lasted some time, but how long was not accurately determined. Experiments devised to test the consciousness of auditory sensations reaching the opposite ear gave no definite results.

The *permanent* result of these three ablations was, it will be seen, almost *nil*, although so much of the cortex of one hemisphere had been removed by them.

Fourth operation.—Of the remaining part of the cortex, which included the angular gyrus, the parietal lobule, the central gyri, parts of the transverse frontal gyri, the marginal gyrus, the gyrus fornicatus, and the hippocampal gyrus, all but the two last-mentioned gyri were removed three months after the third operation.

Result.—The result was the production of absolute hemiplegia with severe shock, from which the animal failed to recover, dying in the course of a few hours.

The brain is represented in figs. 24A and B, Plates 3 and 4, but the representations

are mainly of interest as showing the completeness of removal of the frontal and occipital lobes, and the limits of the lesion upon the under-surface of the hemisphere.

25.

Lesion 1.—Left occipital lobe removed. The hemiopia (imperfect visual perception of objects on right of mesial plane) which resulted was accompanied by partial hemiplegia and œdema of the opposite foot (so that there was probably some hæmorrhage into the ventricle). The paralysis was, however, in great part gradually recovered from, but the hemiopia persisted, although in a diminished form, until three weeks after, when (*Lesion 2*) the right occipital lobe was removed. This was also followed by imperfect visual perception (of objects on left of mesial plane), but the animal was attacked by gangrenous cellulitis of the feet, and had to be killed sixteen days after the second lesion. In this interval of time there was little or no recovery from the visual imperfection.

The brain is represented in fig. 25. From this it will be seen that the removal of the occipital lobes has not been quite complete, especially upon the right side, not more than half of which has been excised.

26.

Lesions 1 and 2.—In this Monkey both occipital lobes (external and posterior surfaces and a part of the under-surface) were removed, with an interval of fourteen days between the two operations. A little of the external surface was, however, left intact.

Result.—The first lesion (on the right side) was followed by left hemiopia, which had not been recovered from when the second (on the left side) was established. The immediate result of the double lesion was to produce almost complete blindness. This was gradually recovered from to a certain extent, so that, although small objects did not appear to be distinctly discerned, larger ones were seen and obstacles were avoided. There seemed after a time to remain a general impairment of visual perceptions, without, so far as could be made out, absolute blindness in any part of the field of vision, but of this we cannot speak with any certainty.

Lesion 3.—Two months after the removal of the left occipital lobe, and with the animal in the condition just described, the angular gyrus of the right side was cut away.

Result.—This operation was followed by complete hemiopia, the right side of both retinæ being perfectly blind. A threatened blow coming from the left side was not avoided, no objects appeared to be seen, nor was any food picked up if placed on the left side of the mesial plane of vision. This condition lasted without recovery until the animal's death (from dysentery) three months later.

The brain, viewed from behind and somewhat from above, is shown in fig. 26.

27.

Lesion 1.—Removal of the whole of the external and posterior surface of the left occipital lobe. The upper part of the angular gyrus was also to some extent involved in the lesion.

Result.—Right hemiopia apparently complete; objects on the right of the mesial plane are not seen. This condition lasted some weeks, but gradually improved, so that after five months the most careful testing failed to elicit any imperfection of visual perception.

Lesion 2.—Six months after the first operation the cortex of the quadrate lobule of the same side (the left) was removed. The result of this second operation, so far as could be determined, was entirely negative.

The brain is represented in figs. 27A and B, Plate 4.

28.

Lesion 1.—The greater part of the left temporo-sphenoidal lobe was cut away, the descending cornu of the ventricle opened, and the hippocampus major removed. The lesion included all but a small part of the hippocampal gyrus.

Result.—We could detect no difference of sensibility on the two sides, nor was there any other noticeable symptom either on the day after the operation or on any subsequent occasion.

Lesion 2.—A nearly equal extent of the right temporo-sphenoidal lobe was removed three weeks later, but on this side the gyrus hippocampi remained almost untouched. The ventricle was again opened and the hippocampus major cut away.

Result.—The result was again negative; again we could detect no deficiency in sensibility on the opposite side.

This animal contracted pneumonia and died on the fifth day after the second operation. The occurrence of this illness prevented any accurate testing of the other special senses.

The brain is represented in 6 figures on Plate 4, both right and left hemispheres being shown as seen (1) from without, (2) from below, and (3) in section.

29.

Lesion.—A large part of the left temporo-sphenoidal lobe was removed, the ventricle (descending cornu) opened, and a considerable piece of the hippocampus major excised. The superior temporo-sphenoidal gyrus, the anterior extremity of the lobe, and the hippocampal gyrus were only in part involved in the lesion.

Result.—We could detect no difference of sensibility upon the two sides. There was no muscular paralysis, nor any other obvious loss of function. We did not test this animal's hearing, intending to reserve the tests for this until the operation should be repeated upon the other side. This second operation was performed three weeks after the first (the wound caused by the first operation having completely healed,

and the animal being to all appearance well on the third day), but was not followed by recovery, death being the result of shock.

The left side of the brain of this Monkey is represented as seen from below in fig. 29, Plate 4.

30.

Lesion.—Ablation of right temporo-sphenoidal lobe and hippocampus major.

The lesion involves only the middle of the hippocampal gyrus.

Result.—As regards sensibility, we could detect no difference on the two sides. As regards hearing, when the ear on the same side as the lesion is stopped the animal seems unable to hear slight sounds.

No other result was obtained. The animal was kept seven weeks.

The lesion is shown in fig. 30A (Plate 5) as seen from the outer aspect, and the extent to which the hippocampal gyrus is involved is exhibited in fig. 30B.

31.

Lesion.—In this animal the greater part of both temporo-sphenoidal lobes was removed in four successive operations, with an interval of rather more than a month between the first and second, about twelve days between the second and third, and a little more than a month between the third and fourth. The first two operations involved all but the superior gyri, but the hippocampal convolution was not reached by the lesion except at its middle part on the right side, where at one point only the injury extended quite to the edge of the hemisphere. Upon the left side the apex of the lobe was left intact, but on the right side it was almost entirely destroyed. In the third operation both the superior temporo-sphenoidal gyri were cut away; but on the right side the superior extremity of the gyrus for about three-eighths of an inch also remained intact, and on the left side the lower extremity. In the fourth operation the hippocampus on the right side, which had not been reached at the first operation, was exposed and excised along a considerable extent.

Result.—The extensive lesions in the brain of this Monkey produced no discoverable symptoms, with the exception of a temporary diminution of sensibility, lasting about a week, or rather more, upon the left side, following the operation for removal of the right hippocampus major. There was no motor paralysis, no diminution of sensibility, even for tactile impressions, and hearing was to all appearance quite acute even the day after the destruction of both temporo-sphenoidal gyri (the remainder of the temporo-sphenoidal lobes having, as we have seen, been previously removed).

This animal was kept alive for nearly five months after the first operation.

The brain is represented in figs. 31A, B, C, and D.

32.

Lesion.—Ablation of the greater part of the right temporo-sphenoidal lobe (a small (postero-superior) part only of the superior gyrus, the posterior extremity of the

second gyrus, the tip of the lobe anteriorly and the posterior part of the hippocampal gyrus being left intact). The hippocampus major was removed in the greater part of its length.

Result.—We could not detect any deficiency of cutaneous sensibility on the left side of the body, nor was any defect of vision perceptible. As regards the other special senses, we were unable to arrive at any satisfactory result. The animal was kept under observation seven weeks after the operation.

The brain is represented as seen from below and the right side in fig. 32A, and in section in fig. 32B.

33.

Lesion.—Complete removal of the left temporo-sphenoidal lobe, including the hippocampus major. The lesion also involved the under-surface of the occipital lobe.

Result.—This Monkey survived the operation only two days, so that the results are very imperfect, and, owing to the collapsed condition of the animal during that time, observations upon the special senses could not be properly conducted. It was, however, clearly ascertained that marked diminution, if not complete loss, of tactile sensibility was produced upon the opposite side of the body, together with diminished sensibility to painful impressions.

The condition of the brain is illustrated by figs. 33A, B, and C (Plate 5).

34.

Lesion.—Removal on the right side of the whole of the lower part of the temporo-sphenoidal and part of the lower surface of the occipital lobe. The hippocampus major and minor were also excised. The superior temporo-sphenoidal gyrus was left, as well as the postero-superior part of the second gyrus. After death it was found that there had occurred softening and destruction of the whole of the lower surface of the occipital lobe, and a patch of softening also extended round the posterior extremity of the hemisphere to the upper surface of this lobe, reaching along the mesial edge nearly to the parieto-occipital fissure (fig. 34B).

Result.—Next day there was no response to tactile impressions applied to the left side of the body and left limbs, and lessened response to painful impressions was also observed, although both produced a ready response when applied to the right side. The day after, the response to painful impressions was somewhat quicker, but tactile impressions still produced no reaction on the left side. The defective sensibility of the left side was found, however, to undergo gradual improvement from day to day; but even three-and-a-half months after the lesion there was still a difference of sensibility upon the two sides, that of the left side being distinctly lessened.

Hemiopia was also produced by the lesion, or by the subsequent changes. This was of such a character that the right side of both retinae was blind, *i.e.*, no objects were seen which were on the left side of the mesial plane of vision. This hemiopia

was permanent; lasting, that is to say, until the animal was killed three-and-a-half months after the operation.

Experiments upon the other special senses, as is usually the case with unilateral lesions, gave no definite results.

There was no muscular paralysis.

The brain is represented as seen from below (right hemisphere) in fig. 34A (Plate 6), and in section in figs. 34C, D, E. The posterior aspect of the right hemisphere is given in fig. 34B.

35.

Lesion 1.—Removal of a large part of the left temporo-sphenoidal lobe, with the exception of the superior gyrus. The hippocampus major was included in the removal, but the gyrus hippocampi only partially (see fig. 35B, Plate 6).

Result.—No difference could be detected on the two sides as regarded sensibility. Hearing was not tested.

Lesion 2.—One month later the gyrus fornicatus and the quadrate lobule of the same side were removed as completely as was possible.

Result.—In testing the next day, it is found that there is complete insensibility to tactile impressions over the whole of the right side, although on the left side these produce a marked reaction. Even to a prick, hard pressure, or the contact of a hot wire, there is only a slow reaction on the right side. The animal was completely recovered from the operation by the third day, but retained the same condition, the right side becoming every day, however, somewhat more sensitive to impressions. But this recovery proceeded only to a certain extent. Even three-and-a-half months after the second operation (when the animal was killed) there was still a distinct difference in sensibility on the two sides of the body.

No hemipia was noticed in this Monkey, nor could any definite results be arrived at regarding the other special senses.

The lesions are shown in figs. 35A, B, and C.

36.

Lesion.—Removal of a considerable part of the left gyrus fornicatus. During the operation there was much venous hæmorrhage, and several of the veins passing from the outer surface into the longitudinal sinus had to be tied. The marginal gyrus and the motor region of the outer surface of the hemisphere were also somewhat compressed in the endeavour more completely to expose the gyrus fornicatus, and, as the post-mortem examination of the brain showed, they did not escape permanent injury, especially the gyrus marginalis (see fig. 36, Plate 6).

Result.—On testing for sensibility the next day, "it is found that the right upper limb, and the whole of the right side of the body as far as the level of the iliac crest, is almost completely insensible to touch, to the prick of a pin, and to a jet of cold water suddenly applied. A heated wire is felt when applied to the back of the fore-

arm, but produces no reaction elsewhere upon the right arm and hand unless heated to excess. The ear and the right side of the head are apparently as sensitive as on the left side, but the right leg, although by no means anæsthetic, is distinctly less sensitive than the left. The leg, trunk, and arm muscles appear weakened, although the right limbs are still freely used. The animal is to all appearance quite well and lively.

“Two days later (on the third day) the condition as regards sensibility is exactly the same, but the pareses, especially of the leg, are less marked.

“During the rest of the week following the operation the symptoms are much the same, but the right side seems to be slowly recovering. It requires, however, a considerable stimulus to produce any response, and the interval between the stimulus and the response is much lengthened; the reaction, when it does appear, being often of the nature of a sudden start. There is also some failure to localise the seat of irritation, and the left limb is often scratched by the animal each time that the right limb is irritated (condition of *allochiria*). The right arm and leg are still paresed.”

The animal was kept for seven weeks, at the end of which time the difference of sensibility was still apparent upon the two sides, both for tactile and painful sensibility (prick, heat, induction shocks), although it had distinctly diminished.

An attempt was then made to remove the gyrus fornicatus of the other side, but the animal succumbed to the shock of the second operation.

The left hemisphere is represented on its mesial aspect in fig. 36. From the superficial view, the lesion of the gyrus fornicatus appears less extensive than is actually the case, for sections showed that this convolution, although imperfectly removed, was undermined by the incision that was made along it preparatory to its ablation.

37.*

Lesion 1.—The anterior part of the left gyrus fornicatus was removed from about the level of Y forwards.

Result.—The external ear of the opposite side gives no reaction either to tactile impressions or to impressions producing pain elsewhere (prick, heat, electric shocks). It could not be determined whether any other parts were as completely insensible.

Lesion 2.—One week later the greater part of the remainder of the convolution was cut away.

Result.—“There is great diminution of sensibility over the whole of the right side. Tactile impressions are not perceived, or at least produced no reaction; painful impressions, such as a prick or a burn, are only slowly perceived and are then not localised. To every such stimulus, no matter to what part of the right side it is applied, the animal responds in the same manner, viz., by scratching the right fore-arm.” This phenomenon (a form of *allochiria*) was exhibited for about a week after the second operation; it then disappeared.

* This animal was exhibited to the Physiological Society.

“ Tested on the tenth day after the operation, there is no reaction produced on pricking any part of the right arm, and only a very slow reaction on applying a similar stimulus to the right side of the trunk and to the right ear. The leg reacts more readily, but is distinctly less sensitive than the left leg.”

After this time the condition as regards sensibility began slowly to improve, especially in parts. “ Reaction is now obtained on stimulating the right hand and arm below the elbow, but none from the upper arm, and very little from the upper part of the trunk down to the level of the iliac crest. The right ear is still quite insensitive, but the side of the face is sensitive. The right foot is rather more sensitive than before, and indeed the whole lower limb reacts, although more slowly and less markedly than on the left side, both to tactile and painful impressions.”

Three months after the second operation the whole of the right side still showed a great diminution of sensibility as compared with the left. The difference was least marked in the arm at and below the elbow. The animal was then killed and the brain examined.

It appears that the lesion involves the greater part of the gyrus fornicatus and the anterior portion of the quadrate lobule, but for a small extent, about 5 mm. in length, near the anterior end of the corpus callosum the convolution is almost intact. The gyrus marginalis is injured at two places, viz., to a small extent posteriorly, and also anteriorly in the prefrontal region. Close to the latter lesion there is a small patch of softening on the external surface.*

The mesial surface of the left hemisphere is shown in fig. 37A (Plate 6), and four sections through the same hemisphere in figs. 37B, C, D, and E. The sections are taken at about the situation of the lines which are lettered correspondingly in fig. 37A.

38.†

Lesion.—The posterior part of the left hippocampal gyrus was scooped away, the occipital lobe being raised from behind and the scoop introduced beneath it. The result of this *modus operandi*, as shown on post-mortem examination, was to cause extensive softening of the occipital lobe. Whether from this destructive process going on in the brain, or from some other unknown cause, the animal did not survive the operation more than seven days. During the whole of this interval there was considerable diminution of sensibility upon the right side as compared with the left, without any sign of motor paralysis.

The superficial extent of the lesion is shown in fig. 38A, Plate 6, and the deep extent in the sections in figs. 38B, C, D, and E.

* There was no perceptible paresis produced by the operation in this Monkey. The right hand was used much less than the left, but many Monkeys are left-handed, and we had not previously determined whether this was such an one. Even had it not been so, the diminished use of the right hand might well have been produced by the loss of tactile sensibility of that limb.

† This animal was exhibited to the Physiological Society.

39.

Lesion 1.—Partial removal of the left gyrus fornicatus. A sharp scoop was carried along the convolution with the intention of removing the grey matter as completely as possible; but the post-mortem examination of the brain showed that, as is so often the case in these cerebral ablations, the amount removed was far less than was anticipated. At two places only was there much destructive lesion of the convolution, viz., in front near the anterior extremity of the corpus callosum, and behind near the quadrate lobule. The remainder of the gyrus between these points is almost intact, except along its upper margin, near the calloso-marginal sulcus. The instrument must have been carried along the line of this sulcus, for the lower border of the gyrus marginalis is destroyed to a corresponding extent.

Result.—The next day the animal does not react to tactile impressions applied to the right side of the trunk as far down as the flank, and also all over the right arm, and hardly reacts to a prick or jet of water on those parts, but the head and the hind-limb of the right side seem fairly sensitive. There is some muscular paresis of the whole right side.

The loss of sensibility upon the right side was maintained, but in a gradually lessening degree, during seven weeks, when a further operation was performed, viz.:—

Lesion 2.—Removal of the posterior part of the limbic lobe as it bends round the splenium of the corpus callosum.

Result.—“It is doubtful if there is any difference produced by this second lesion. It is still the right arm and right side of the trunk which show diminished sensibility.”

Lesion 3.—Two weeks after the second operation the skull was removed over the left occipital region, the occipital lobe raised, and the posterior part of the hippocampal convolution scooped away from behind.

Result.—Our impression is that the anæsthetic condition of the right side of the body was better marked as the result of this third ablation, although we cannot positively affirm this. We will content ourselves with giving the results of a careful mapping out of the anæsthetic region which was made a fortnight after the third operation. So far as we could determine, the symptoms then recorded persisted without perceptible change until the animal was killed three months later. The testing was performed mainly by gentle and repeated prickings with a small pin, but the difference upon the two sides was also tested by induction shocks.

“On the right side of the head, neck, and trunk no reaction is obtained until the flank is reached, when there is immediate manifestation of sensibility. The right leg reacts at once to a prick, but not to gentle scratching with the pin point, sufficient to produce marked reaction upon the left side. Of the right arm the elbow and palm of the hand react readily, the back of the fore-arm hardly at all, the back of the upper arm only slightly. Reaction is also obtained by stimulating in the axillary and pectoral regions.

“There is distinct muscular paresis of both right limbs, but more of the arm than of the leg.

“There is hemiopia; objects on the right side of the mesial plane not being seen.” This is accounted for by the fact that the interference with the occipital lobe which occurred in the two later operations produced, as the post-mortem examination showed, extensive softening of that portion of the brain.

The superficial extent of the lesions is represented in fig. 39.

40.

Lesion.—A cut was made along the anterior two-thirds of the right gyrus fornicatus, and the grey matter of the convolution was completely scooped away. The post-mortem examination showed that the marginal gyrus was also slightly injured, especially in the prefrontal region, and there were some small patches of softening on the external surface which had probably been caused by the drawing aside of the brain in endeavouring the better to reach the gyrus fornicatus.

Result.—There was at first some paresis of the limbs and of the facial muscles on the left side. For ten days or more no reaction whatever was obtained either by tactile or painful impressions (pricks) applied to the left side, although the reaction was marked on the right side. “Even a hot wire causes very slow reaction, and the impression is apparently not localised.” After this time there was some return of sensibility so far as painful impressions were concerned, the improvement being most marked at the back of the fore-arm.

A month after the operation “reaction to painful impressions is manifested over the whole of the left side, but much less markedly than on the right side; but there is still no reaction to tactile impressions applied to the left side. After a time, however, tactile impressions begin to produce reaction upon the left side also, but they are responded to far less markedly than on the right side.” This was still the case ten weeks after the operation, when a second lesion, viz., the removal of the left gyrus fornicatus, was attempted, but proved fatal.

The lesion in the right hemisphere is shown superficially in fig. 40A, Plate 7, and in section in fig. 40B.

41.

Lesion 1.—Destruction of the middle and posterior part of the right hippocampal gyrus from behind by raising the occipital lobe.

Result.—The immediate result produced by this operation was to cause almost complete loss of reaction to tactile impressions in the left limbs and on the left side of the trunk, and greatly diminished reaction to painful impressions. The left ear and the left side of the head and face did not participate in this condition, which persisted for a few days, becoming gradually less marked, so that ten days after the operation the difference of reaction upon the two sides of the body was only slight.

Seven weeks after the establishment of the first lesion, by which time no difference of sensibility could any longer be detected upon the two sides, a second operation was performed upon the same animal. This consisted (*Lesion 2*) in the attempted

destruction of the gyrus fornicatus upon the same side as the hippocampal lesion, but the post-mortem examination showed that the destruction of that convolution was not complete. Only about the middle third of the gyrus fornicatus was involved in the lesion, and even here at places the part next the corpus callosum remained undestroyed. On the other hand, an equal extent of the marginal gyrus along the calloso-marginal sulcus was injured.

Result.—This second lesion again produced a very considerable deficiency of reaction to tactile impressions and a certain amount of deficiency of reaction to painful impressions over the whole of the left side of the body. There was also some paresis of the left leg. This condition persisted until the death of the animal ten days after the second operation.

The lesions are shown in figs. 41A to D.

42.*

Lesion 1.—Removal of the anterior two-thirds of the left gyrus fornicatus.

Result.—The immediate result was the production of a great diminution of sensibility over the whole of the right side of the body. The insensibility was for the first two or three days complete, even to pricking and a hot wire, on the right side of the trunk and in the right upper limb. A slight reaction is obtained on pricking the root of the tail on the right side, and more on applying the same stimulus to the right leg. There was also at first some muscular paresis on the right side, especially of the leg.

A week after the operation the condition was much improved.

There is now reaction over the whole of the right side to painful impressions, but often want of localisation of the seat of these impressions, a totally different part being scratched from that which is stimulated.† The muscular paresis is now scarcely, if at all, apparent.

Recovery proceeded gradually, so that after a time the difference of sensibility of the two sides is hardly perceptible, except about the arm and shoulder and in the foot.

Lesion 2.—Eleven weeks after the first operation, this last condition being still maintained, the right gyrus fornicatus was exposed, and injured by scratching its surface with a needle. This, however, produced no perceptible result, and after a fortnight the animal was killed and the brain examined, when it appeared that the permanent injury caused by the needle operation was so slight as to be almost imperceptible.

The lesion of the left hemisphere is shown in fig. 42, Plate 7.

43.

Lesion.—The posterior part of the left hippocampal gyrus was destroyed from behind by raising the occipital lobe.

* Exhibited to the Physiological Society.

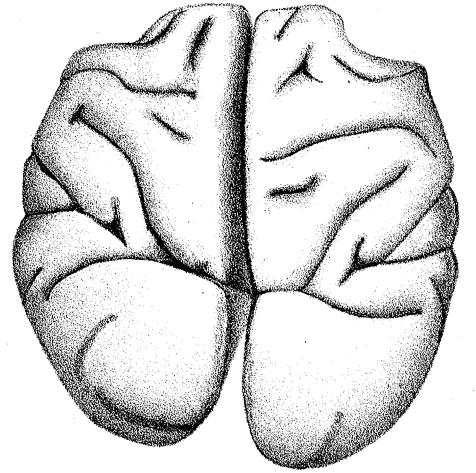
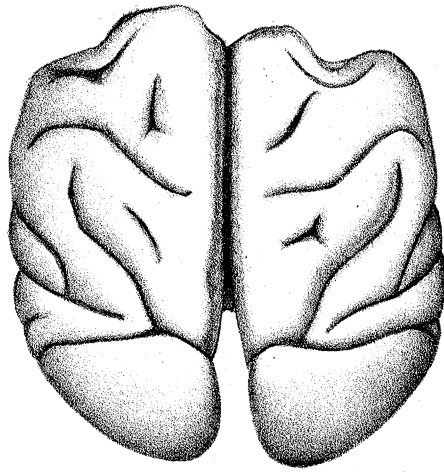
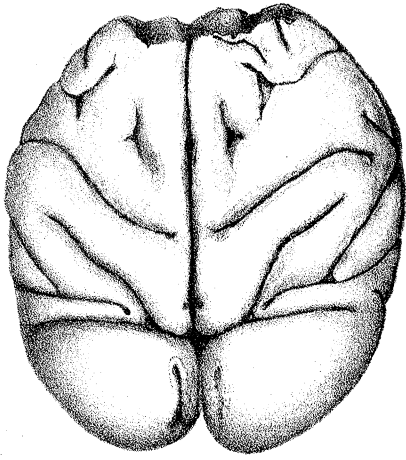
† Compare Nos. 36 and 37.

Result.—The immediate result produced was great diminution of reaction both to tactile and painful impressions over the posterior part of the right side of the body, with slight diminution over the whole side, the reaction being slower than on the left side.

This animal was accidentally strangled by its cord on the fifth day, so that the further progress of the symptoms could not be followed.

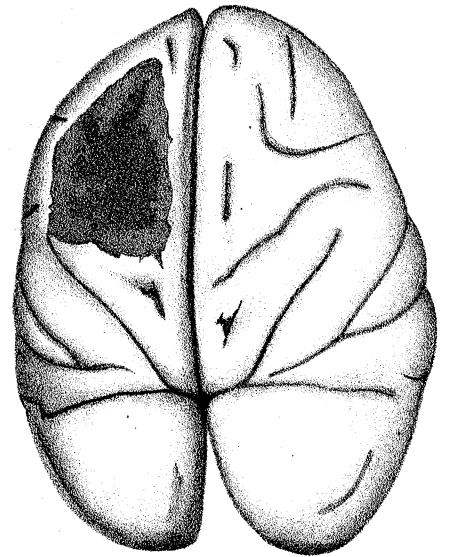
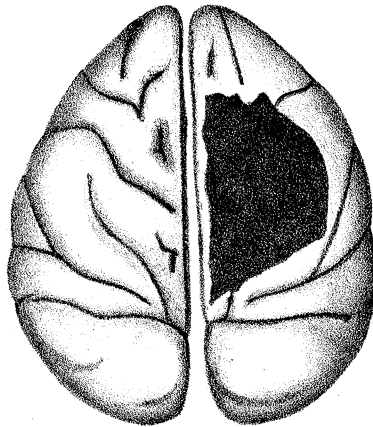
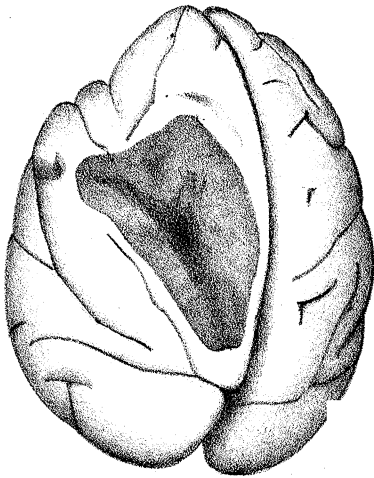
The lesion is represented in fig. 43.

The expenses of this investigation have been chiefly defrayed by aid of a grant from the Association for the Advancement of Medicine by Research.



2.

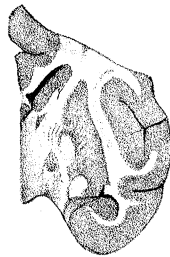
3.



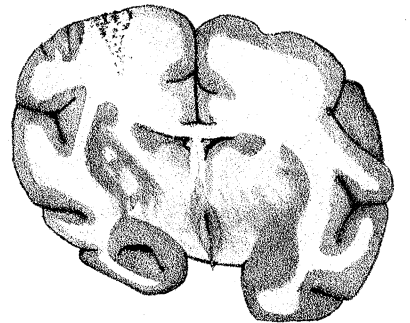
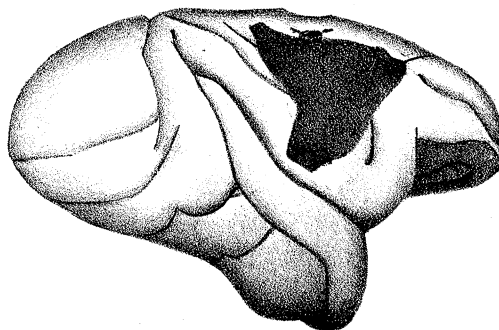
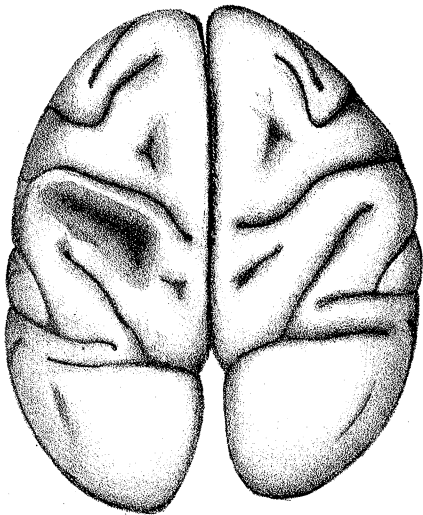
4.

5.

6.



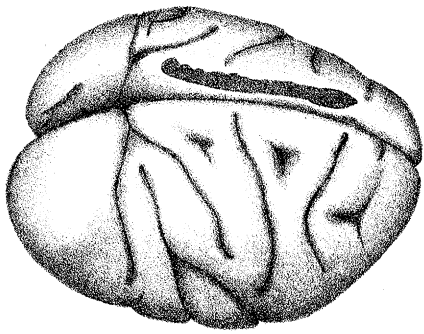
5A



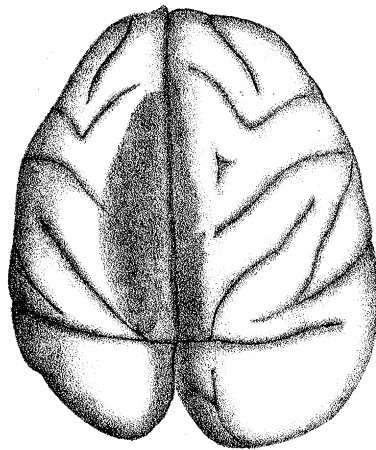
9.

8.

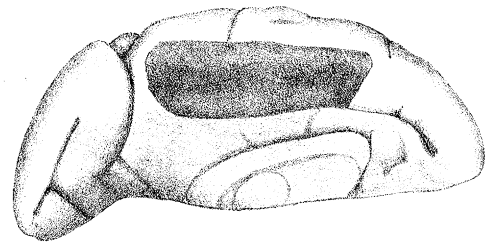
6A.



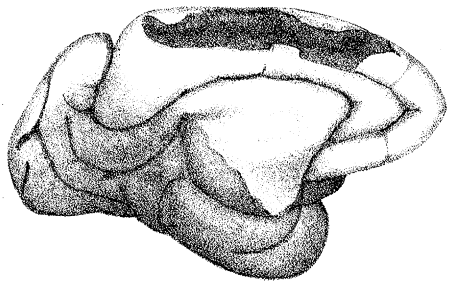
11.



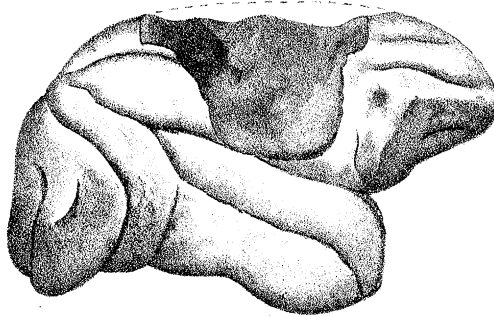
12.



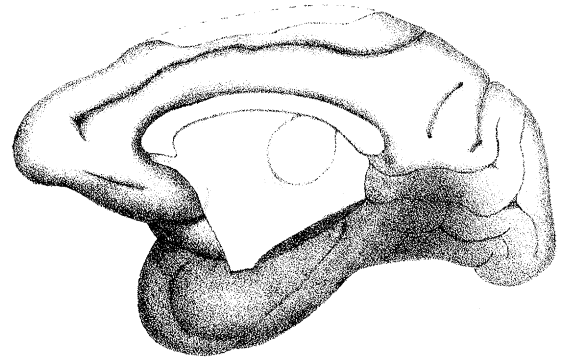
13.



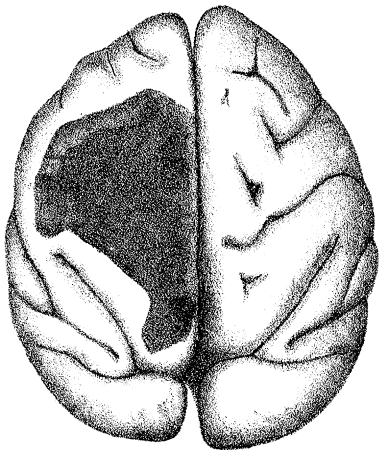
14.



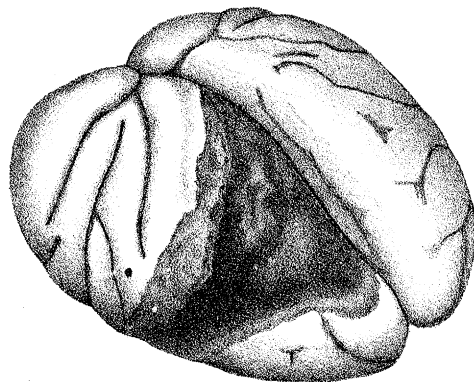
15A.



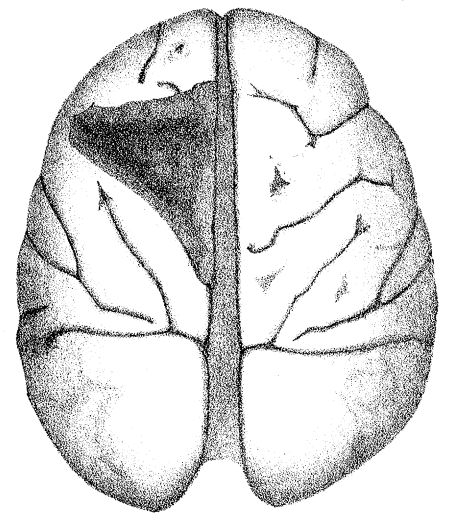
15B.



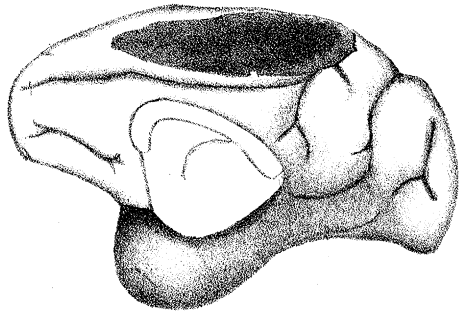
16.



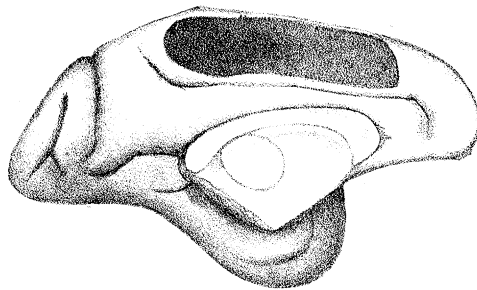
17.



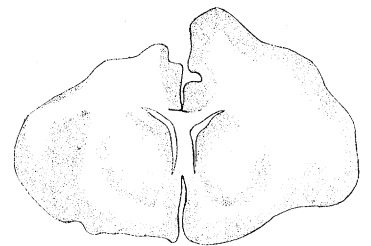
18.



19R.



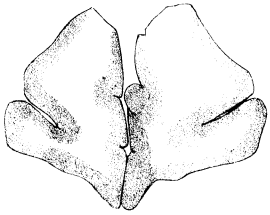
19L.



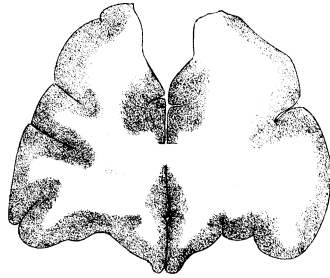
18A.



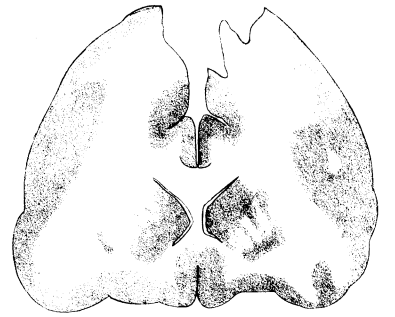20



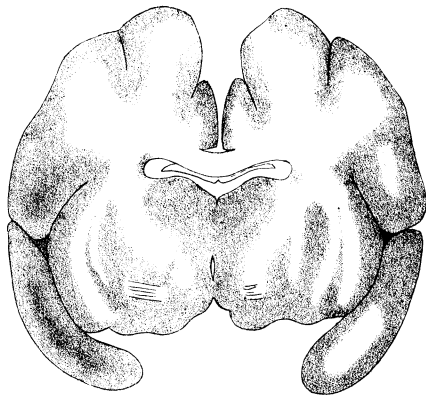
20A.



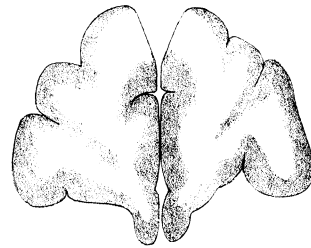
20B.



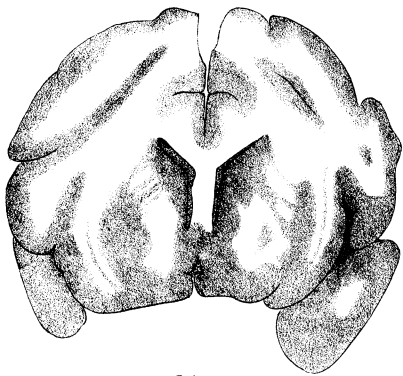
20C.



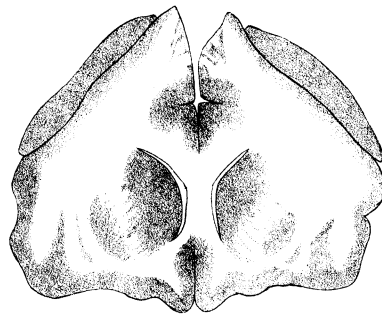
20D.



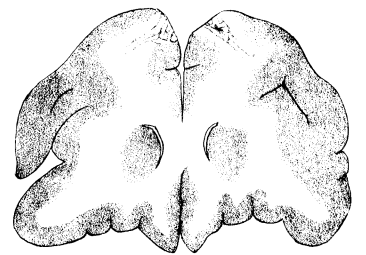
21A.



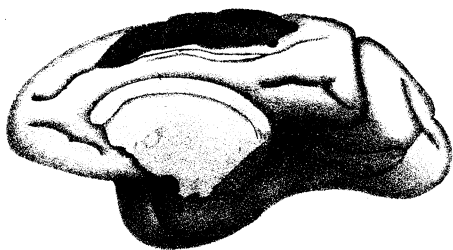
21B.



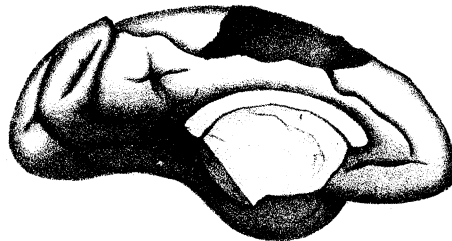
21C.



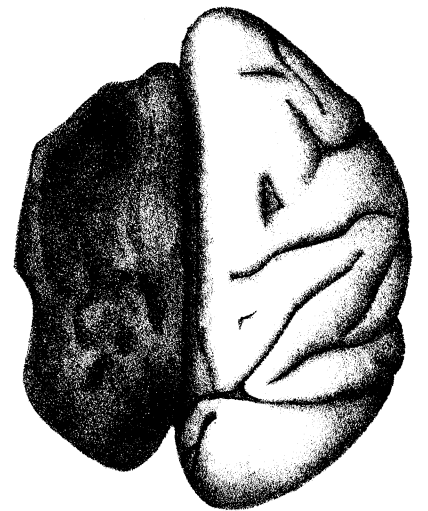
21D.



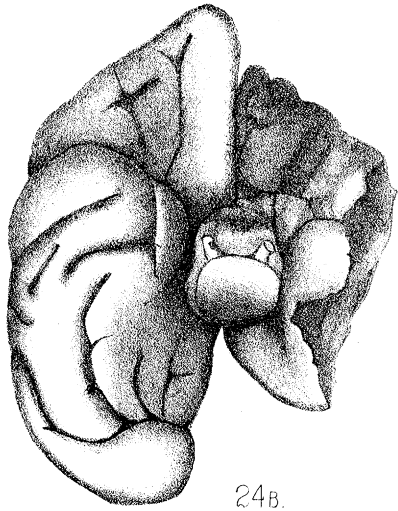
23R.



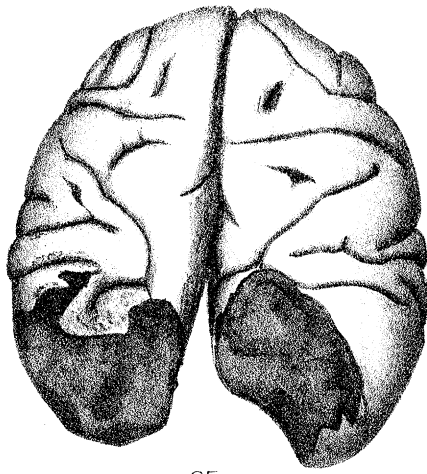
23L.



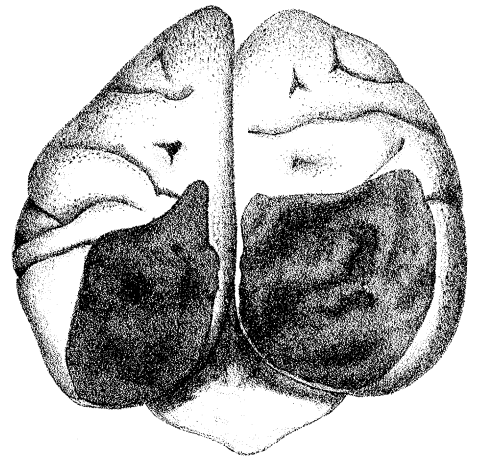
24A.



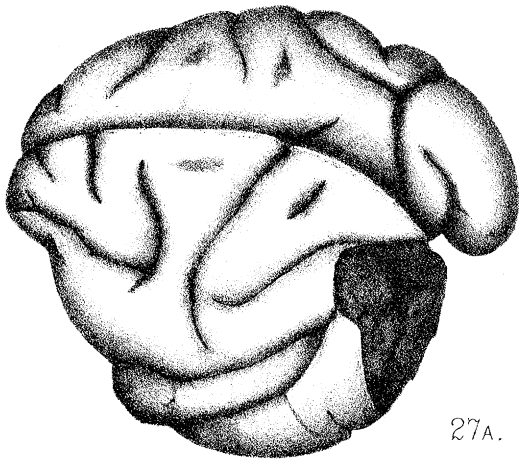
24B.



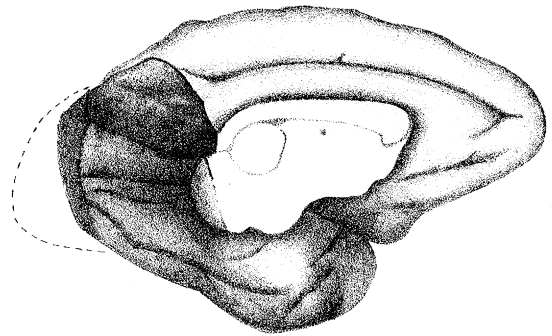
25.



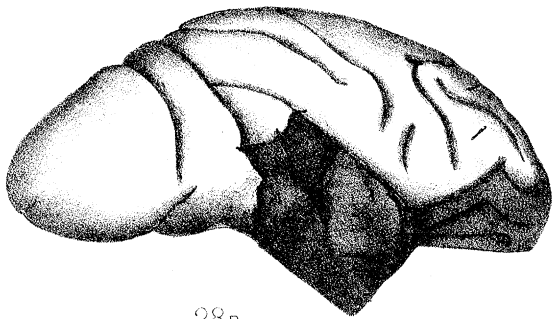
26.



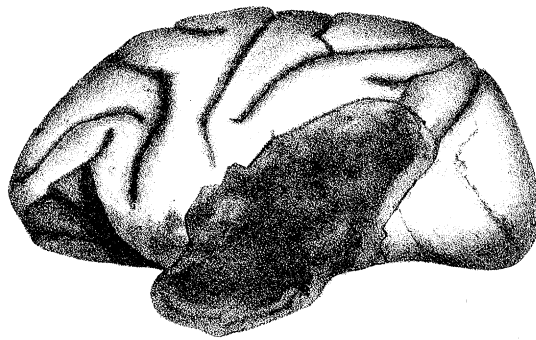27A.



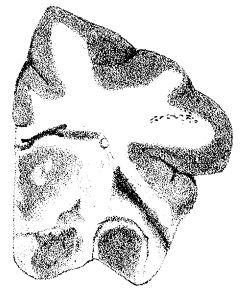27B.



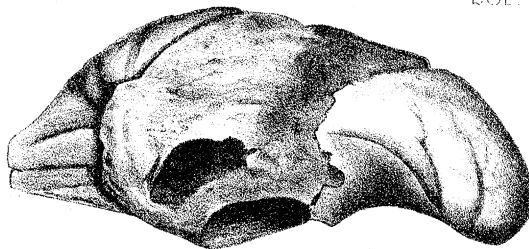28R.



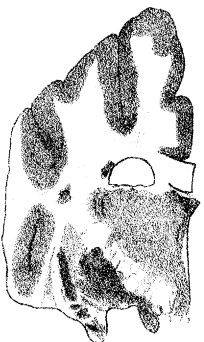
28L.



28R'

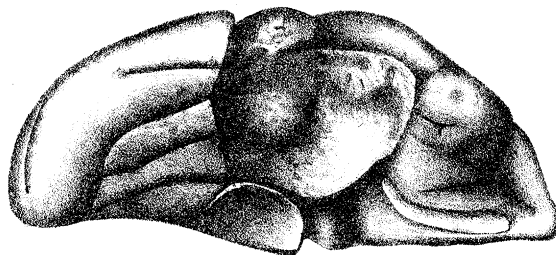


28L'

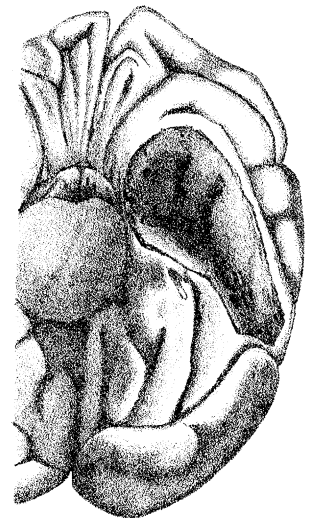


28L''

E. P. France del.

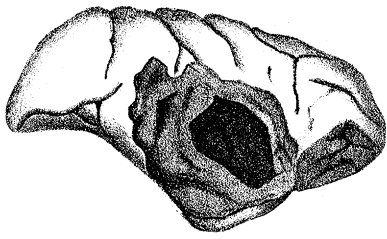


28R''

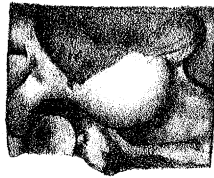

29.

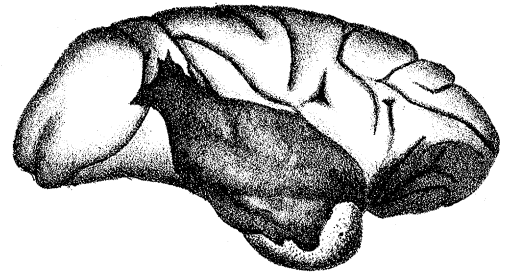
Lith. & Imp. Camb. Sci. Inst. Co.



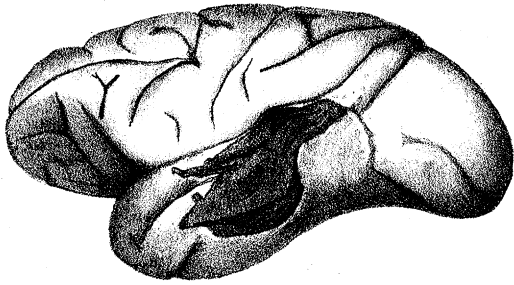
30A.



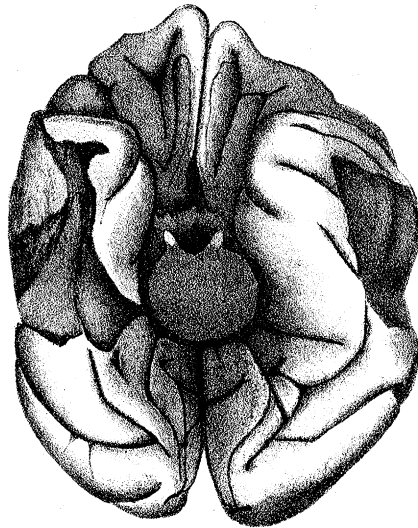
30B.



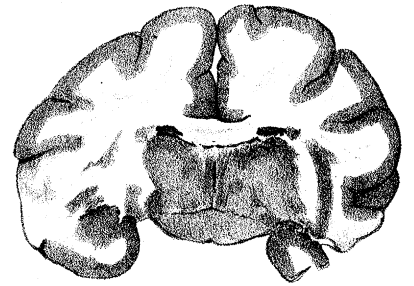
31A.



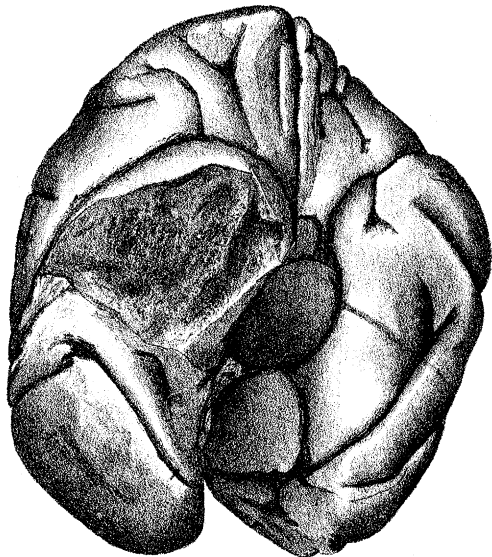
31B.



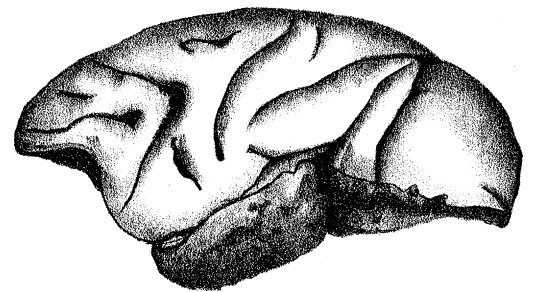
31C.



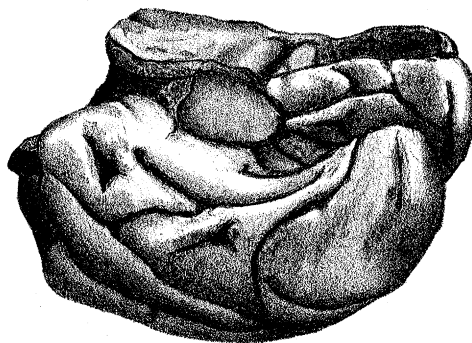
31D.



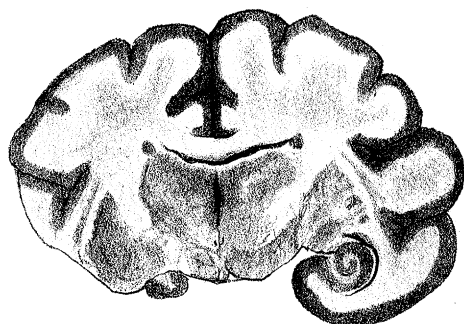
32A.



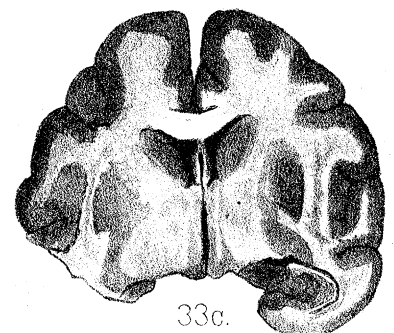33A.



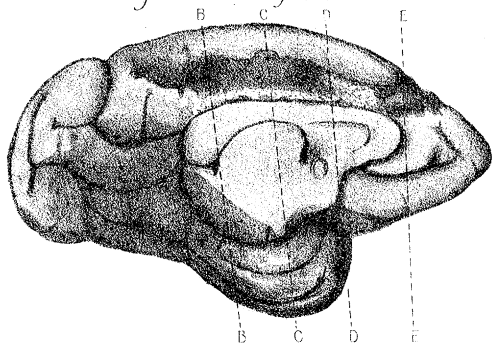
33B.



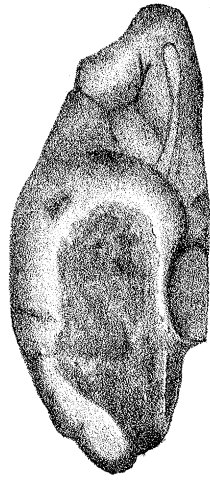
32B.



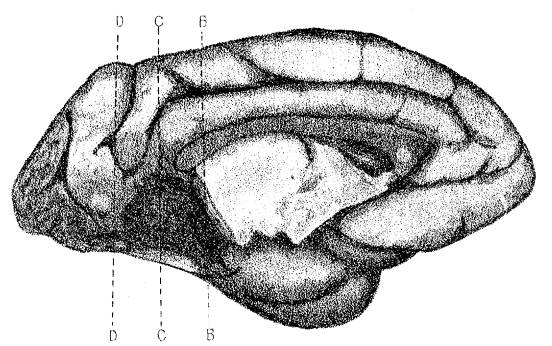
33C.



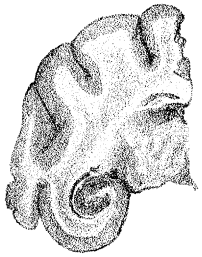
37A.



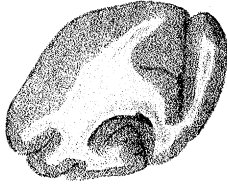34A.



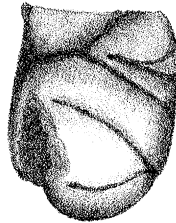
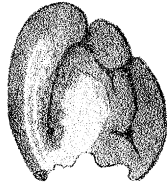
38A.



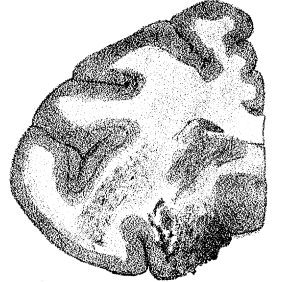37E.



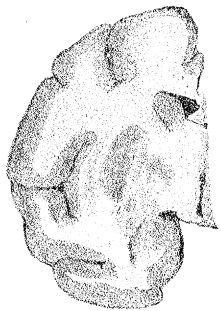
34E.



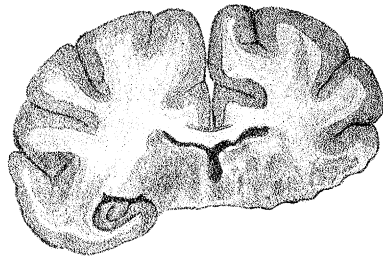
34B.



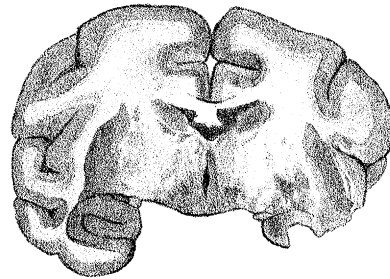
38B.



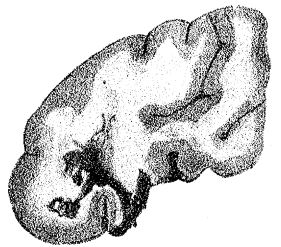
37D.



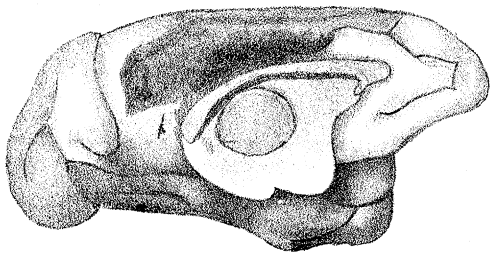
34D.



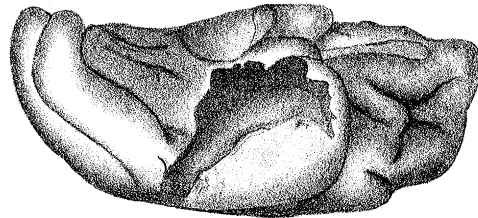
34C.



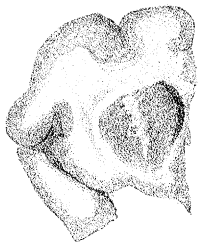
38C.



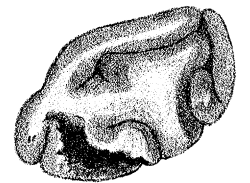
35A.



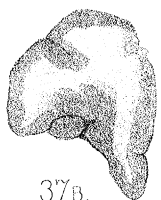35B.



37C.

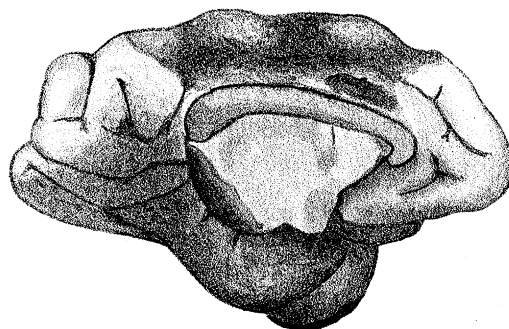


38D.

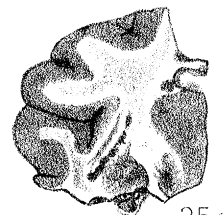


37B.

F.P. France. del.

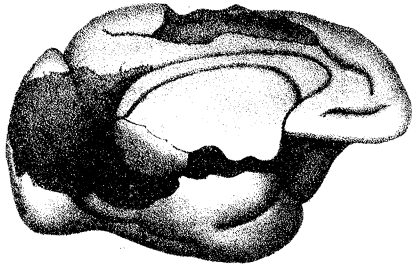


36.

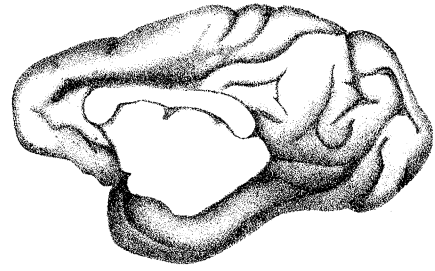


35C.

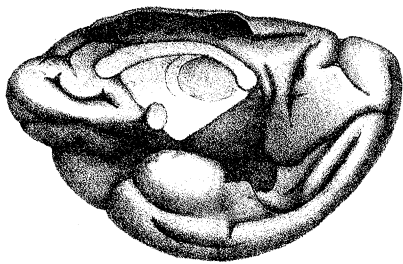
Lith & Imp. Camb. Sci. Inst. Co.



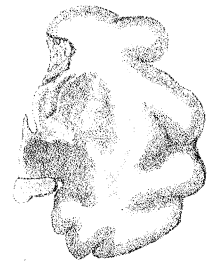39.



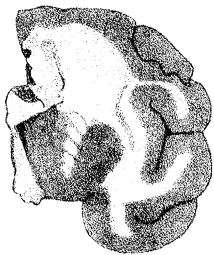
40A.



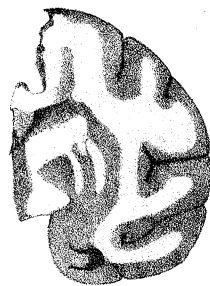
41A



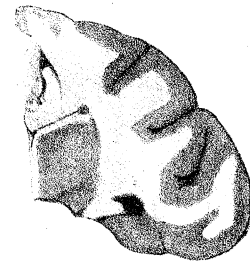
40B.



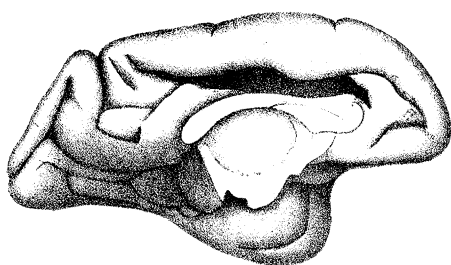
41B.



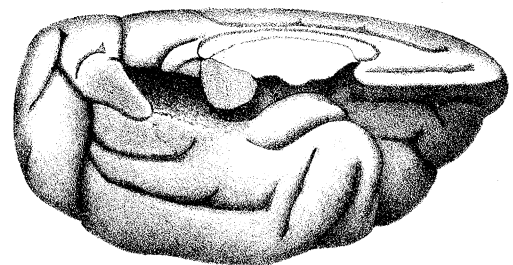
41c



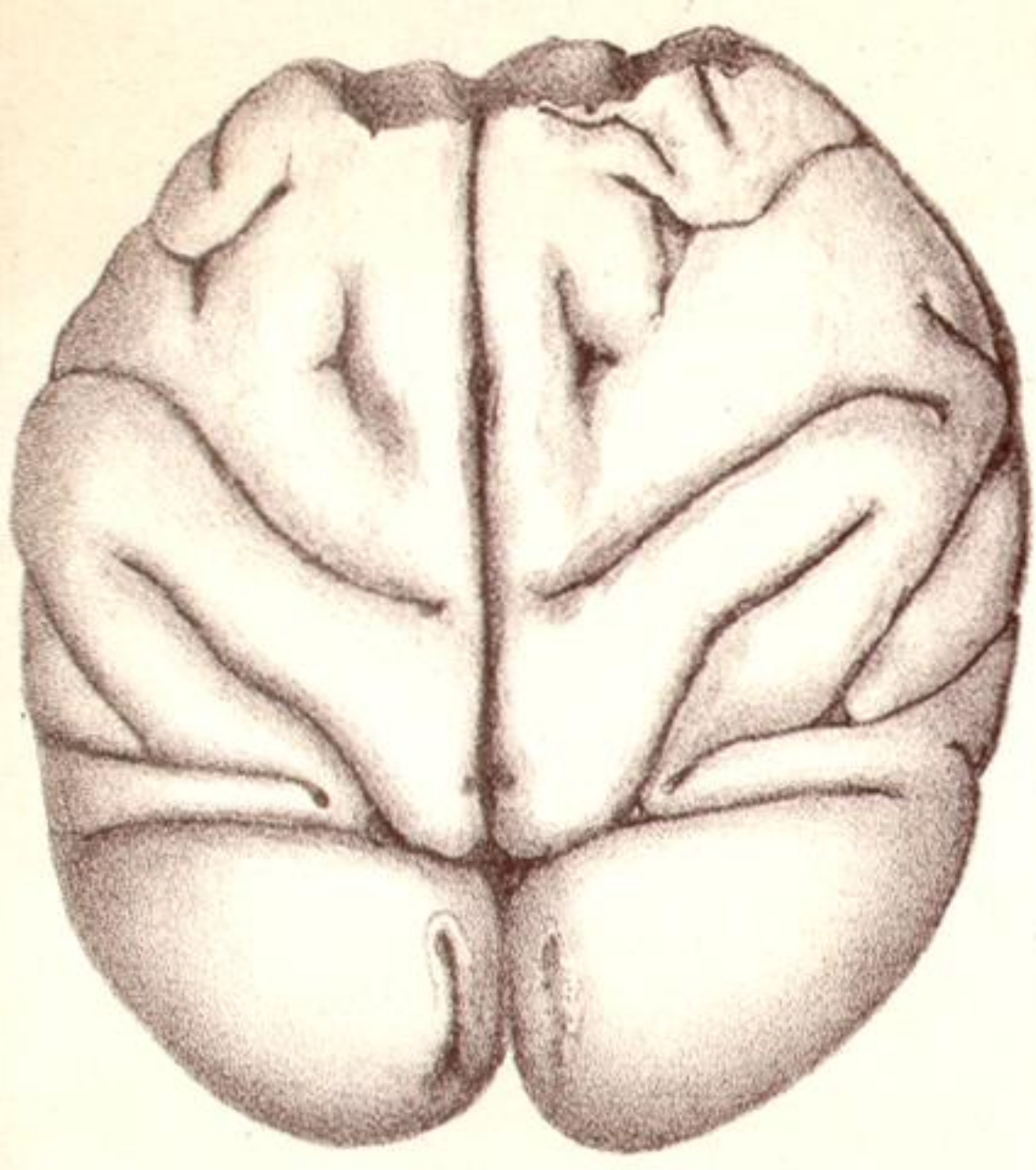
41D



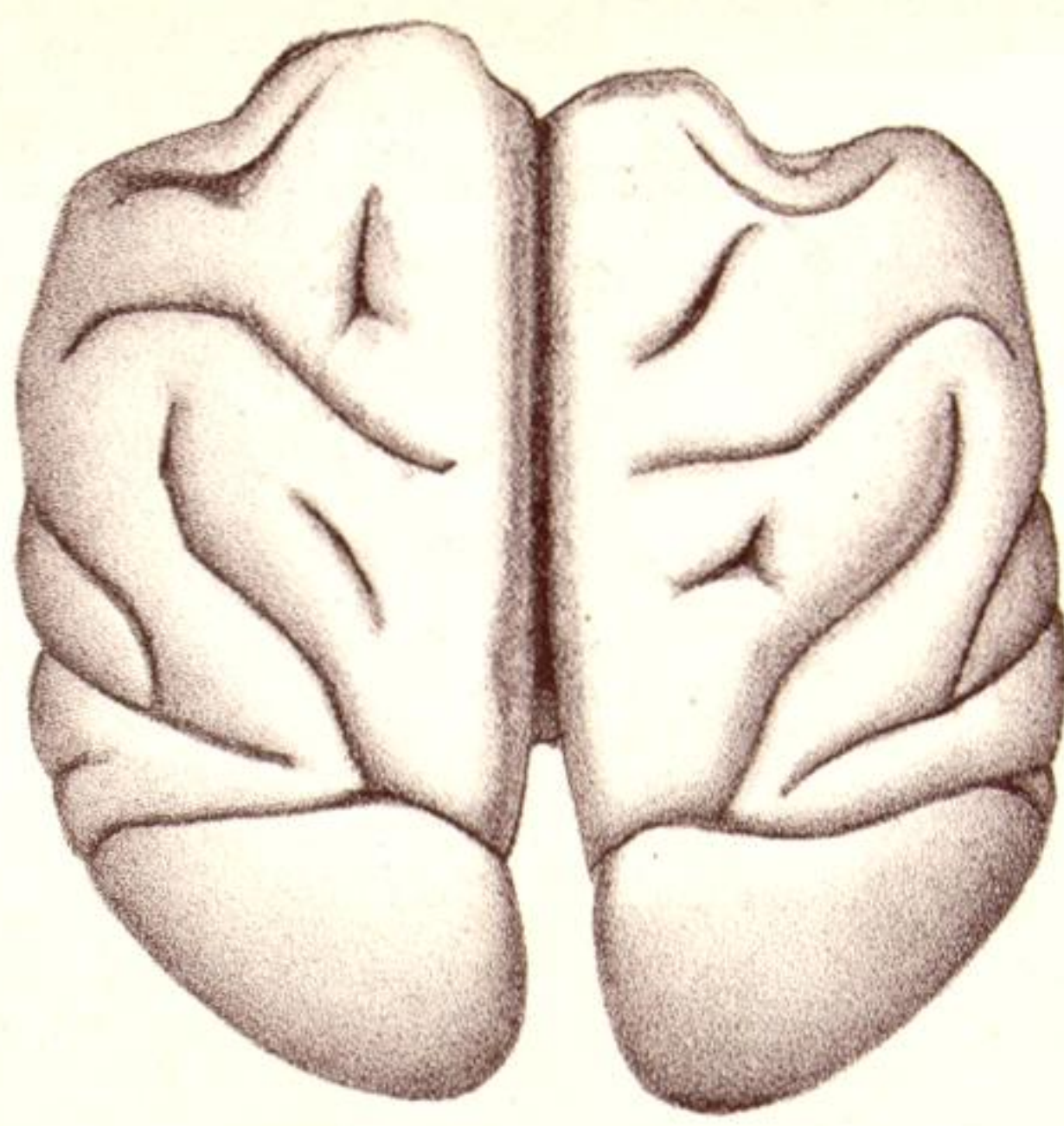
42



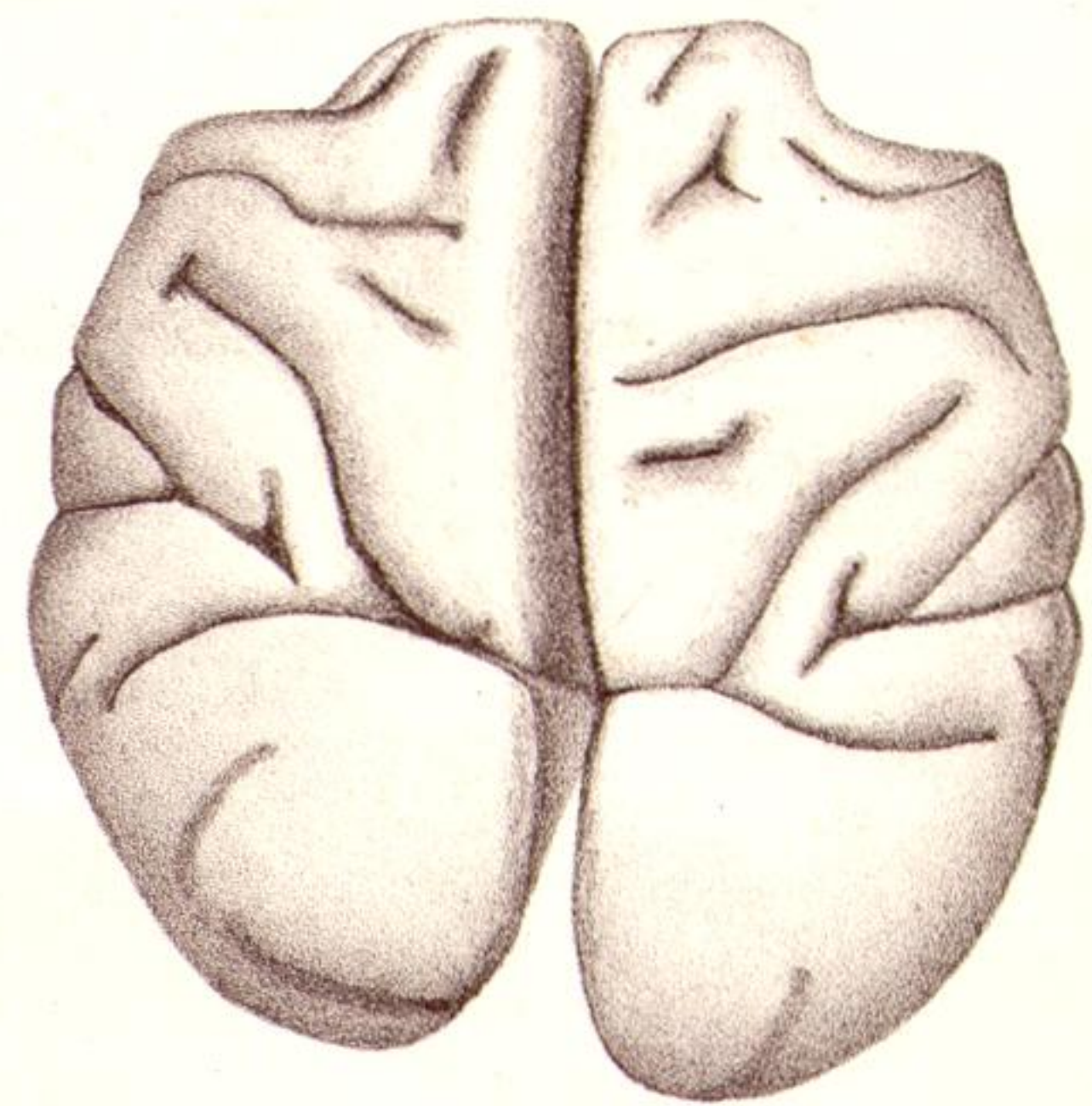
43



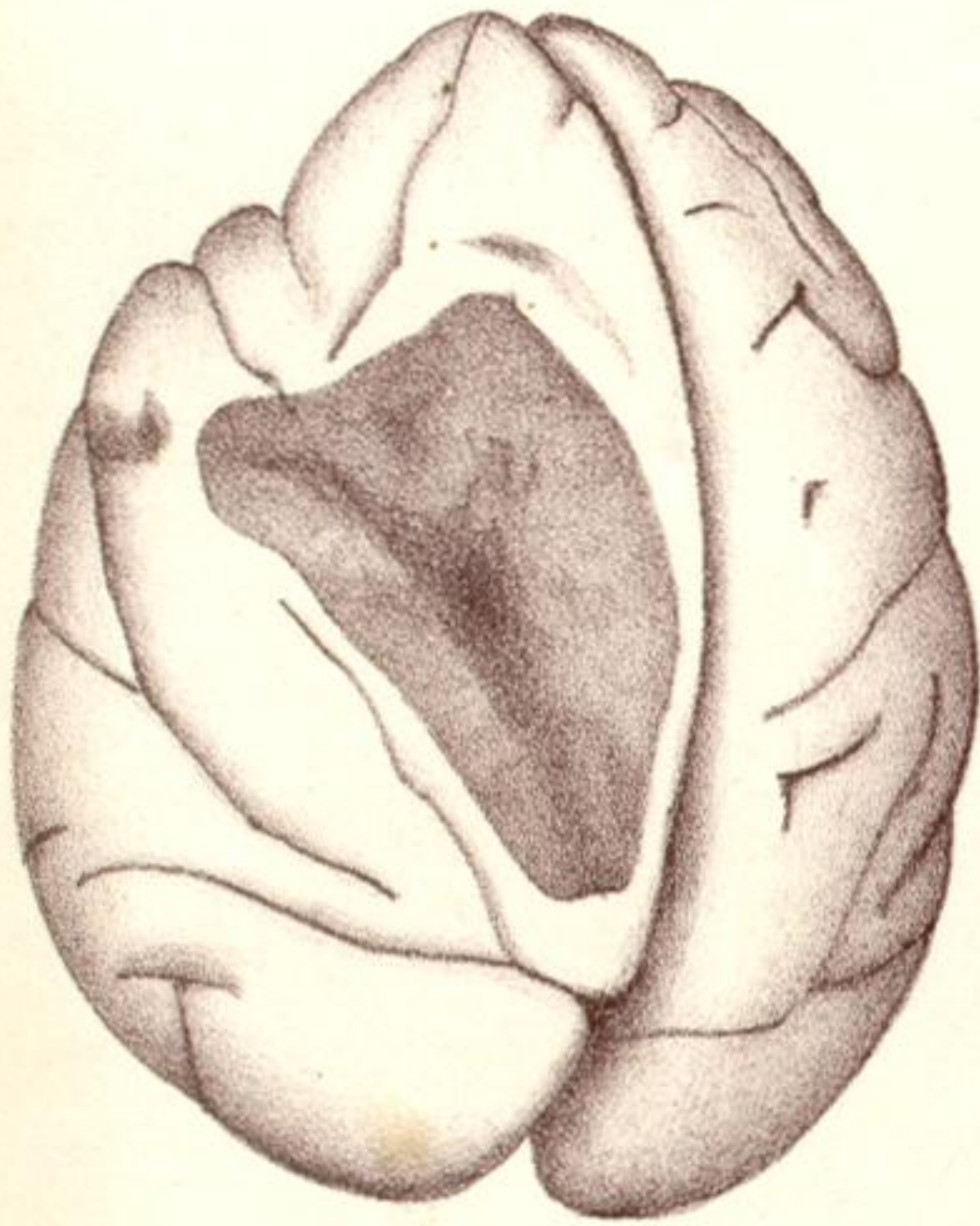
1.



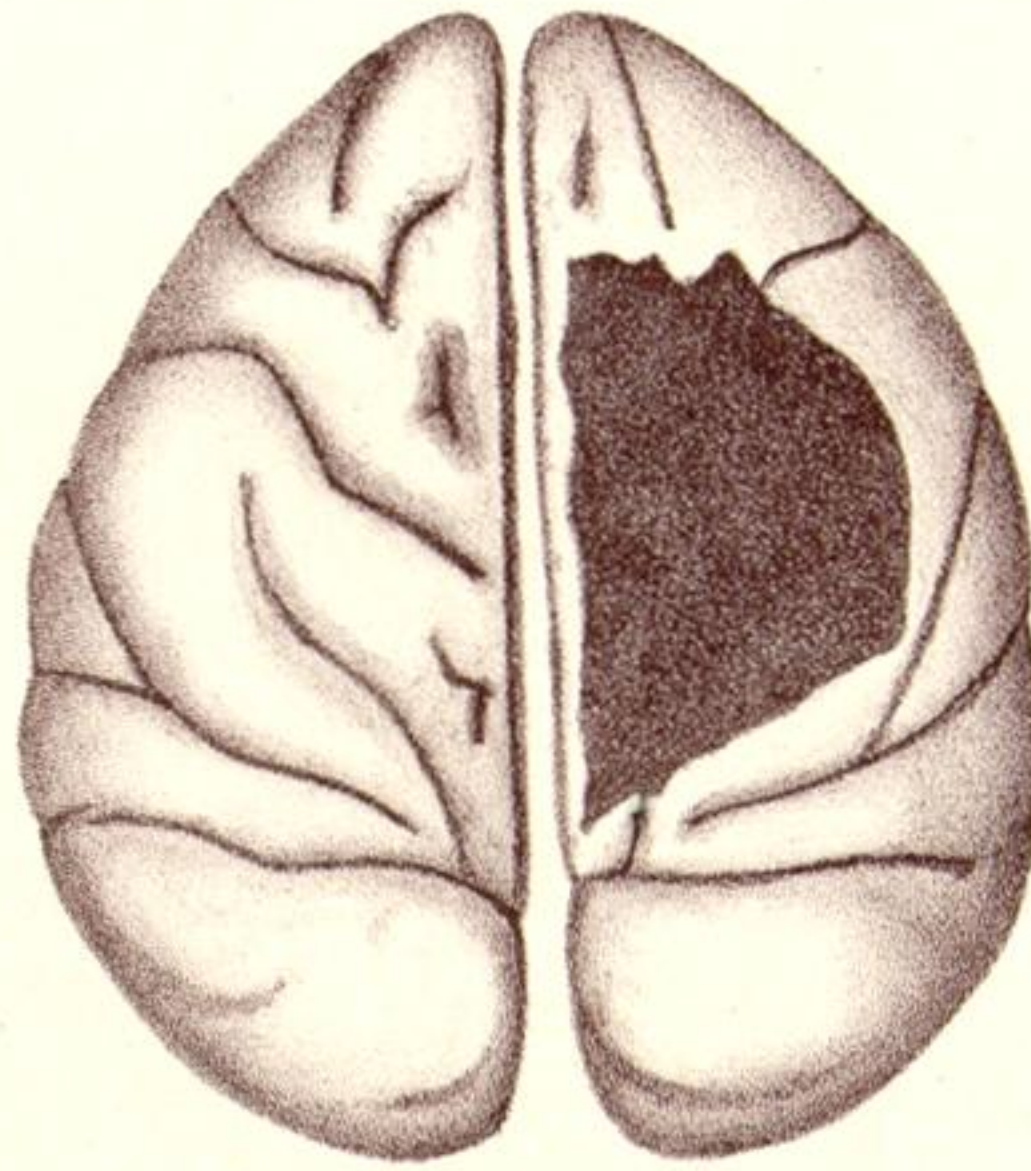
2.



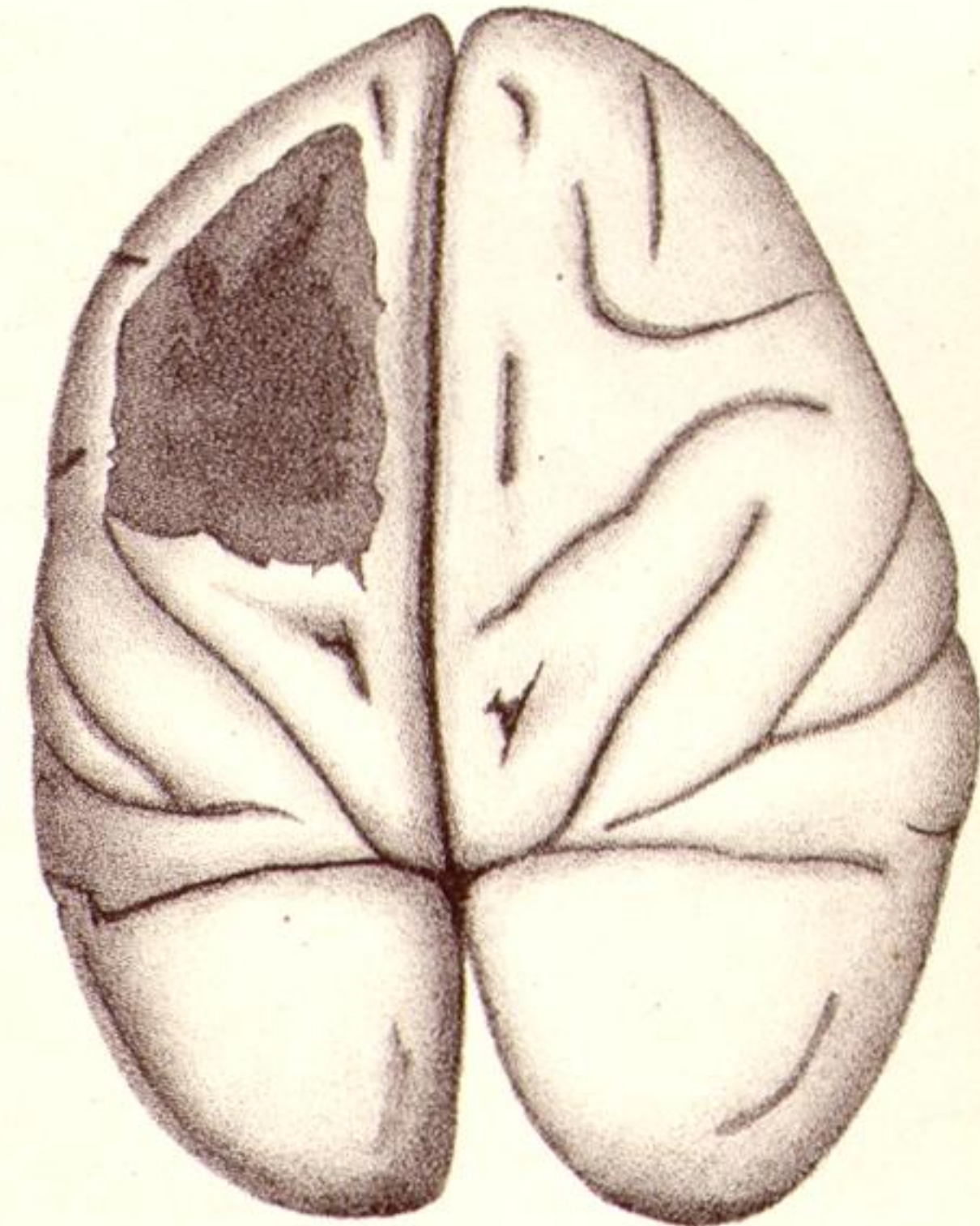
3.



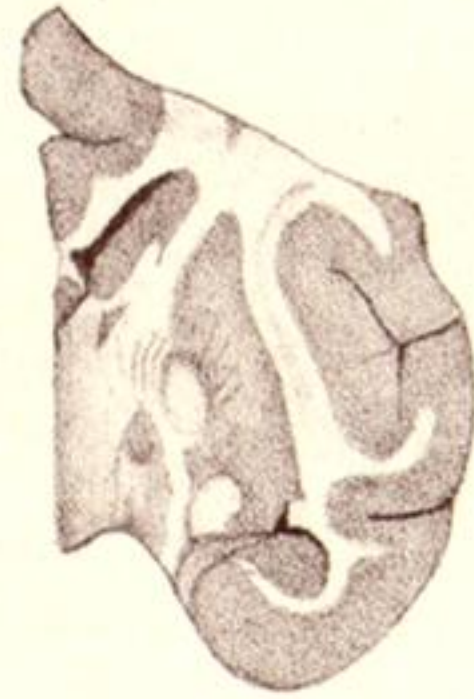
4.



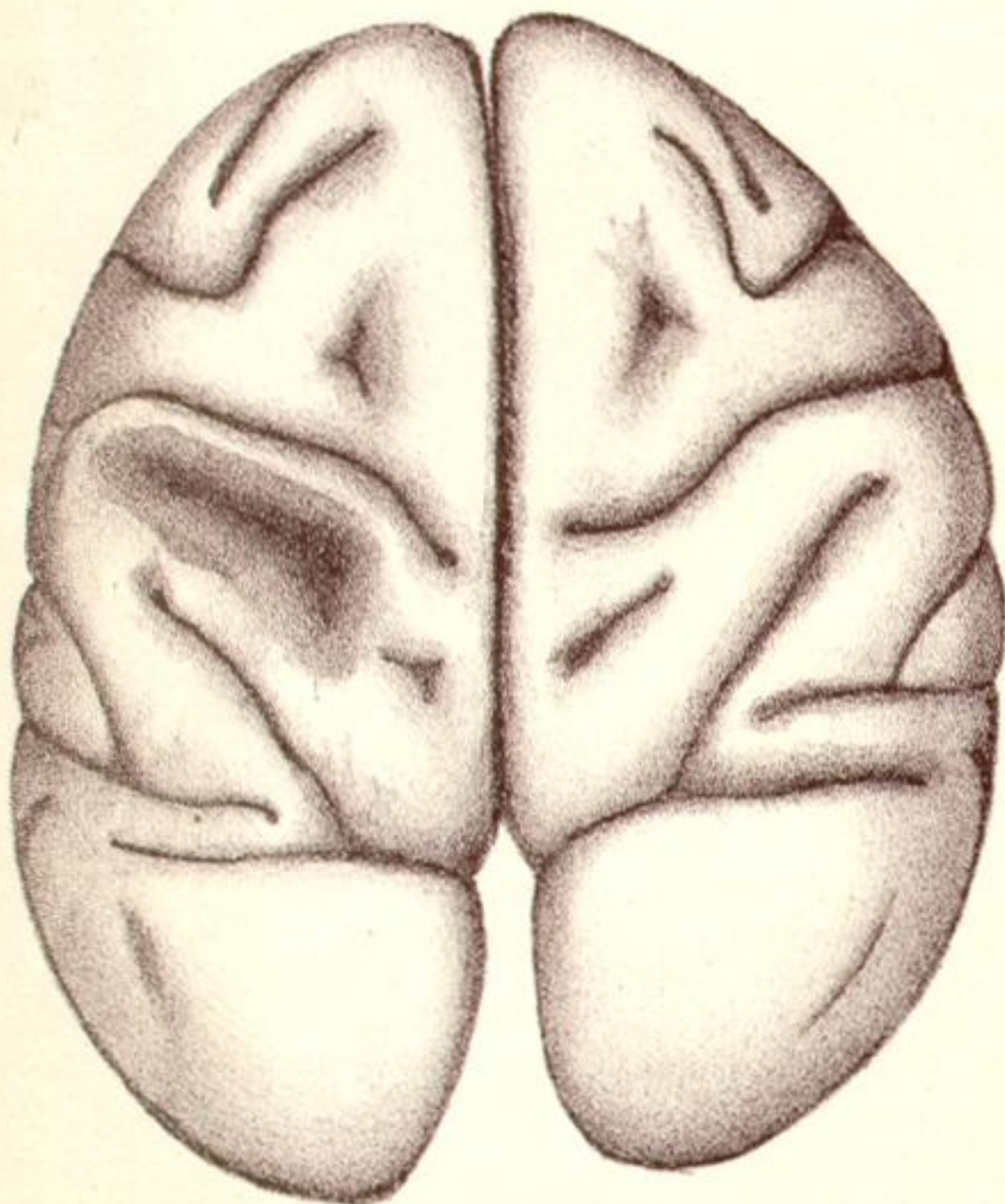
5.



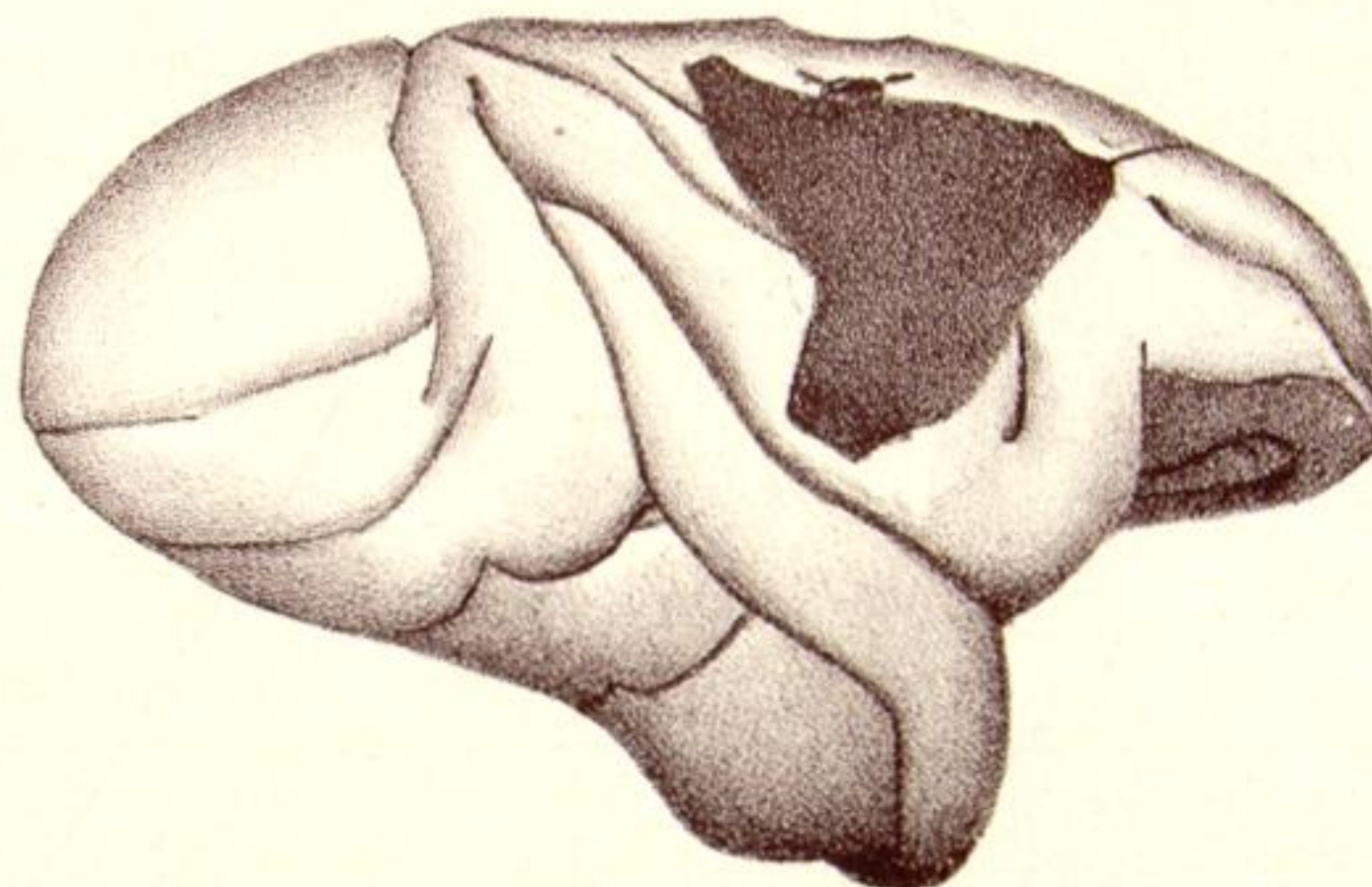
6.



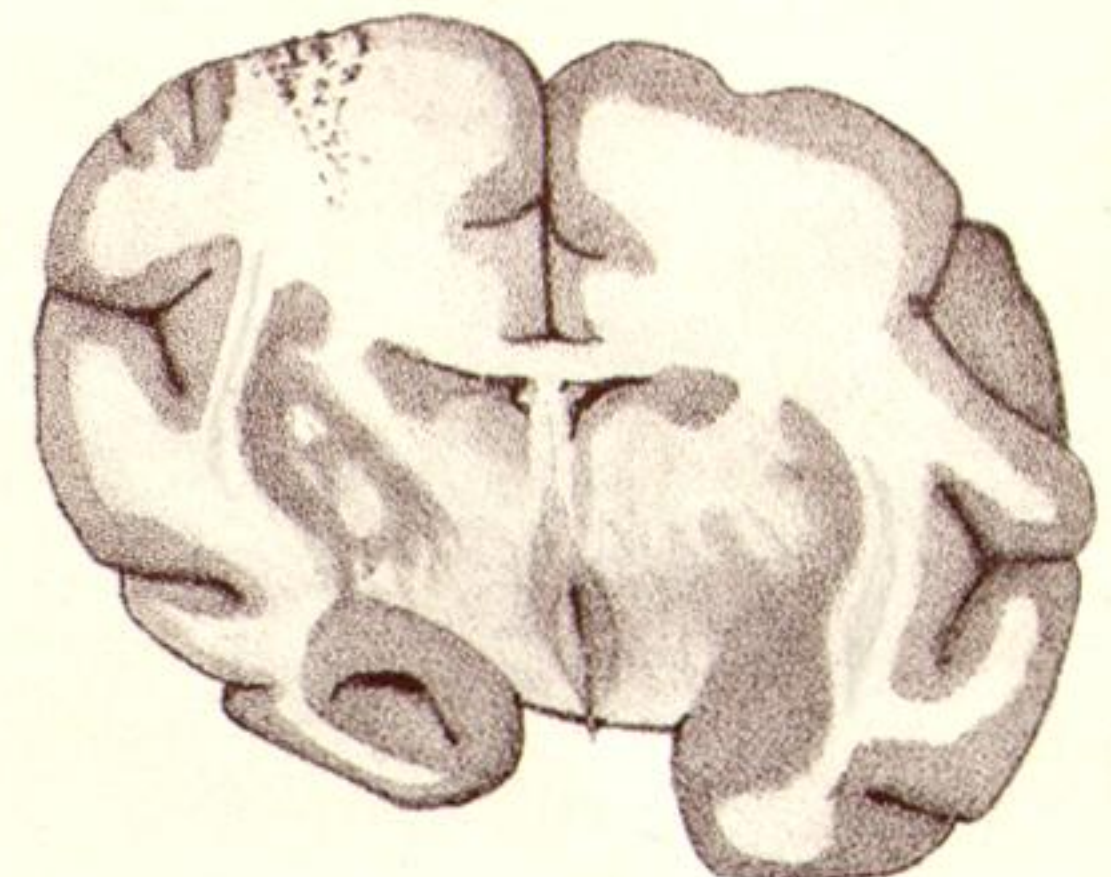
5A



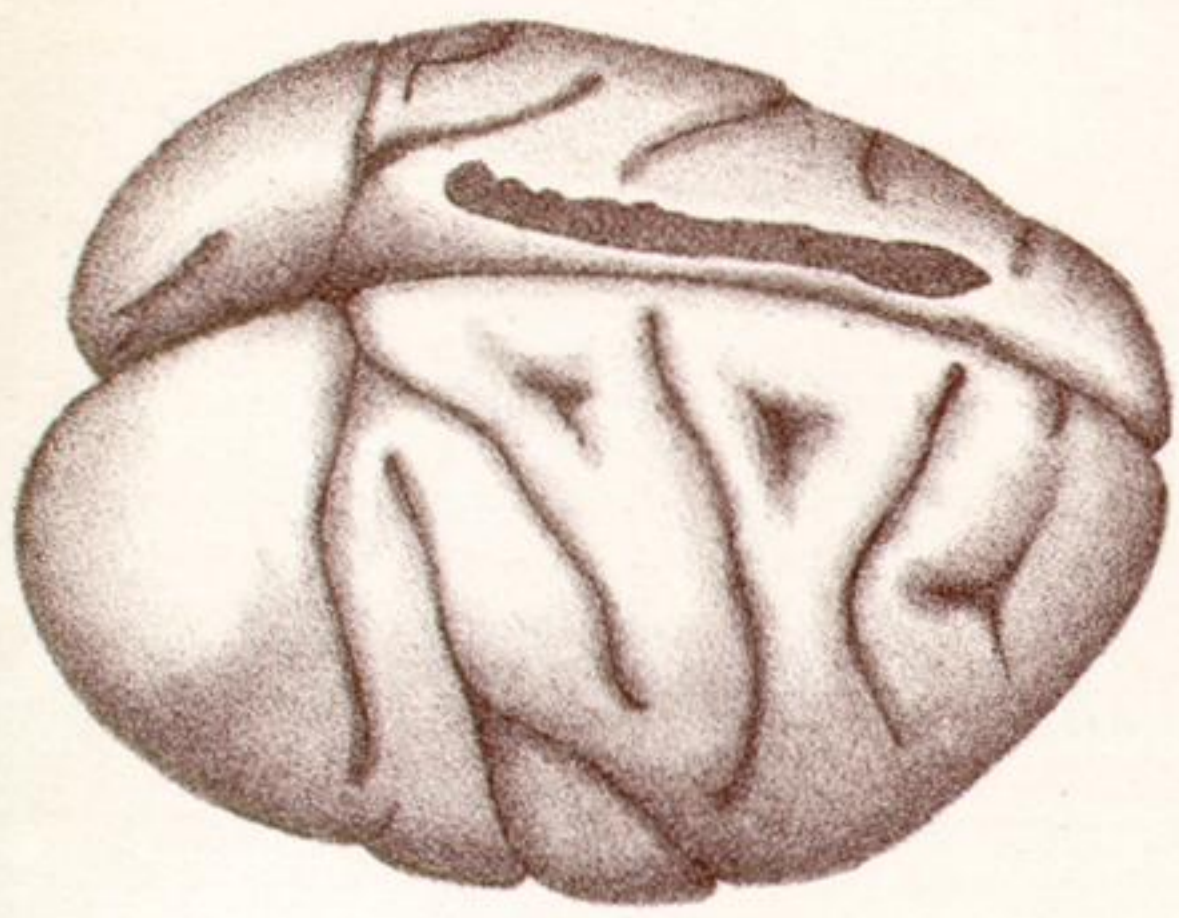
9.



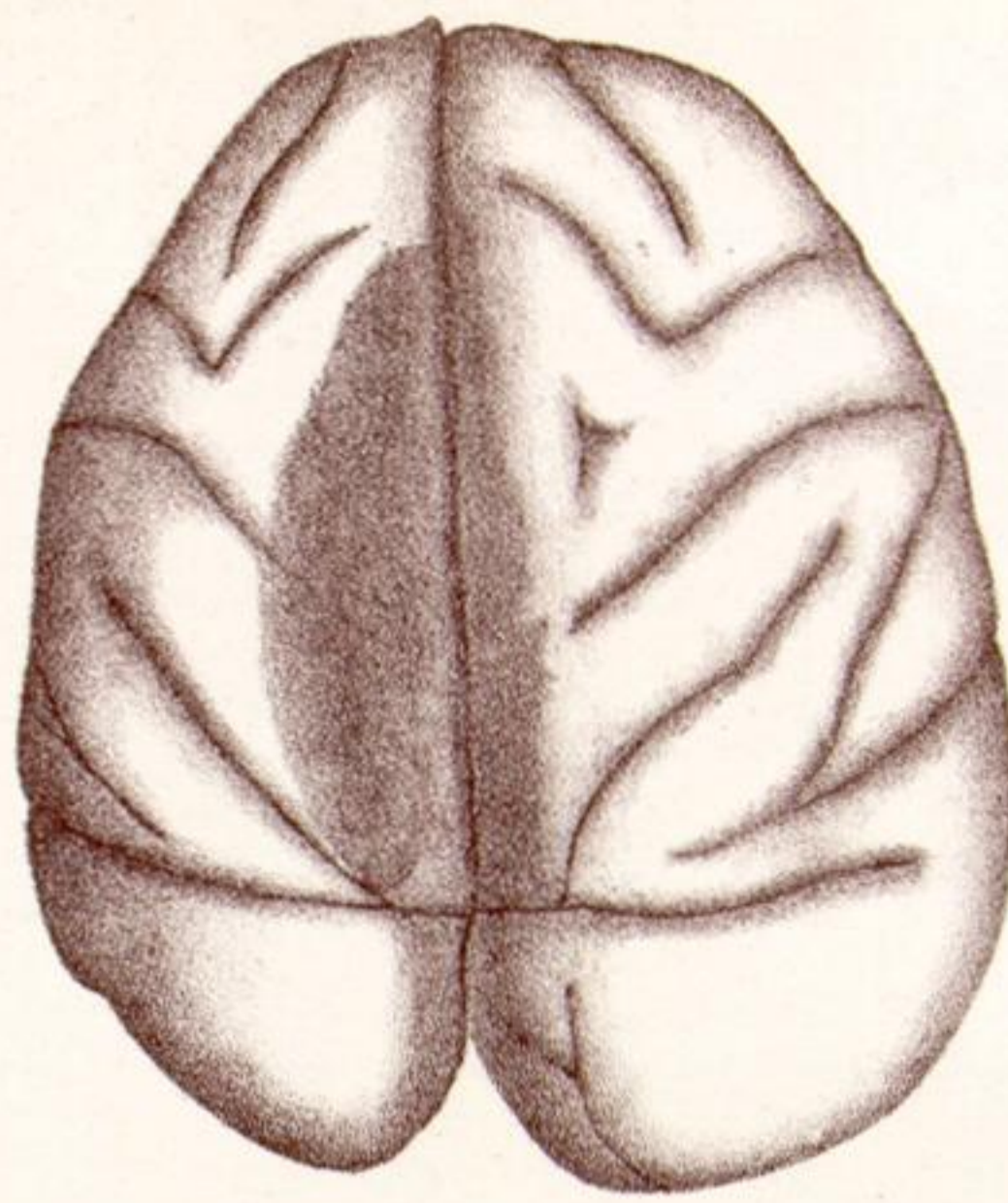
8.



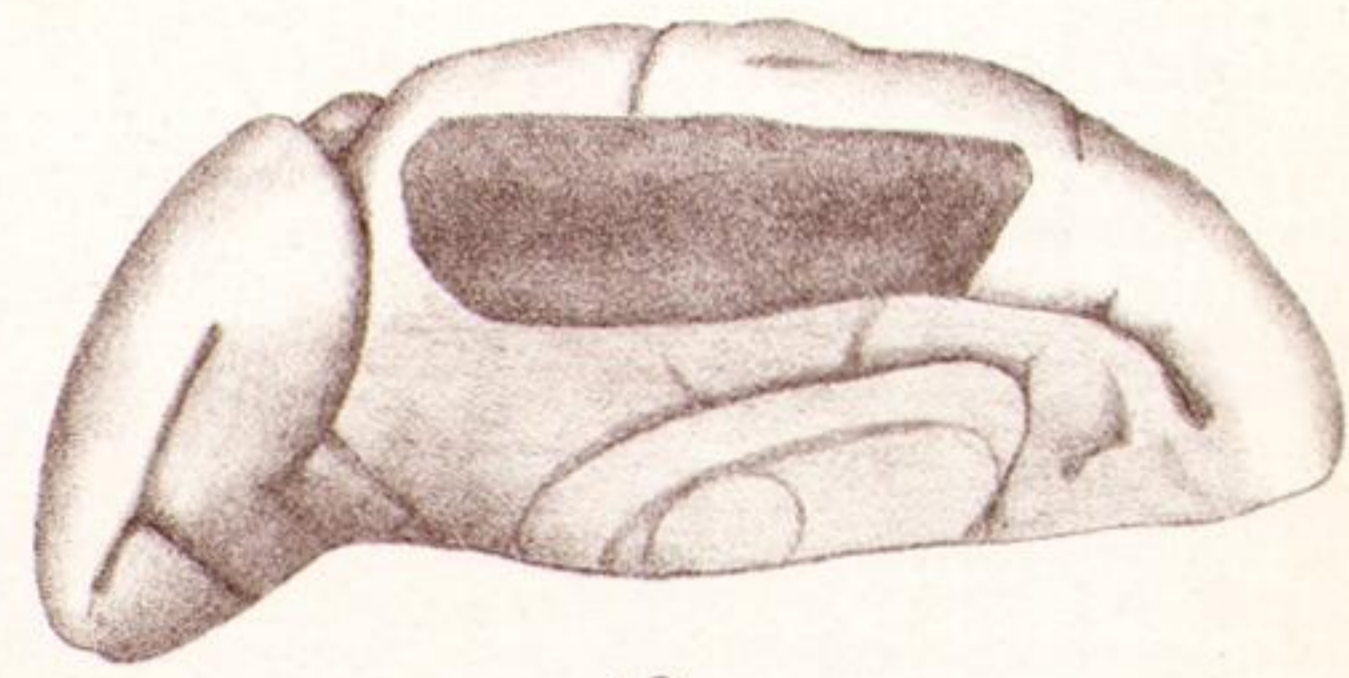
6A.



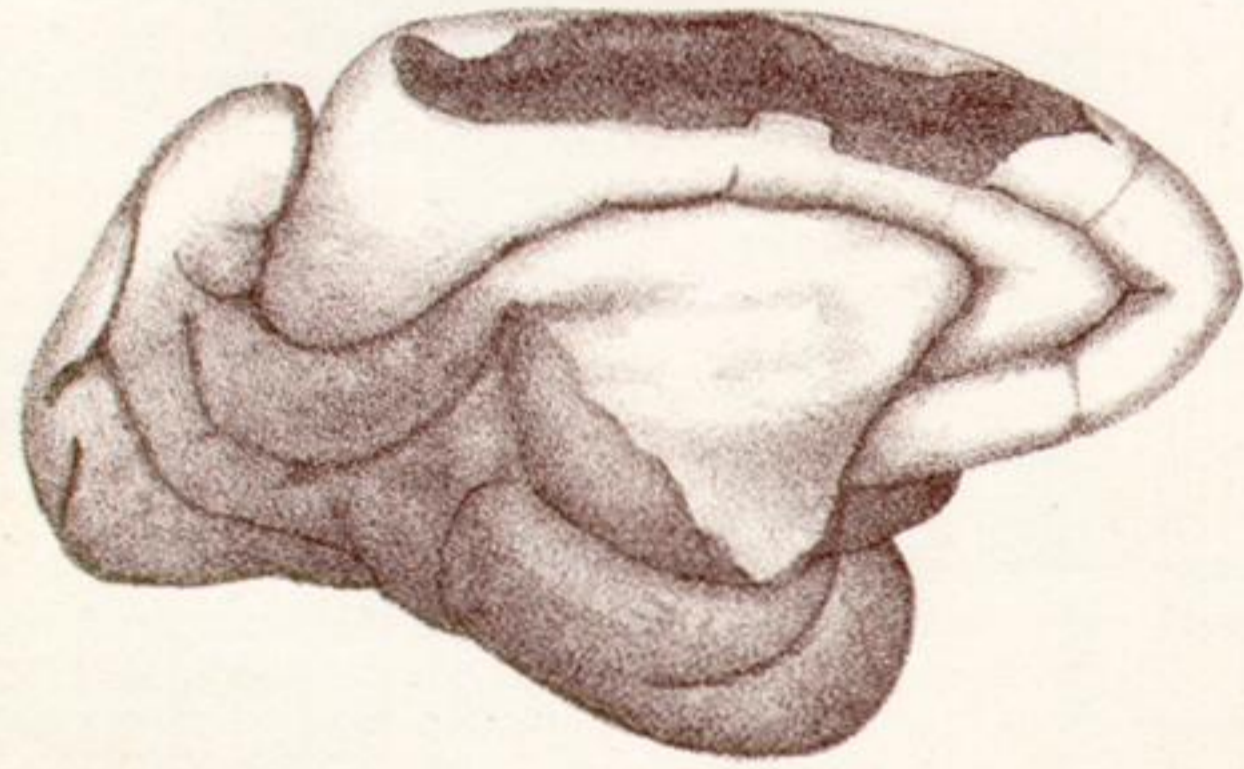11.



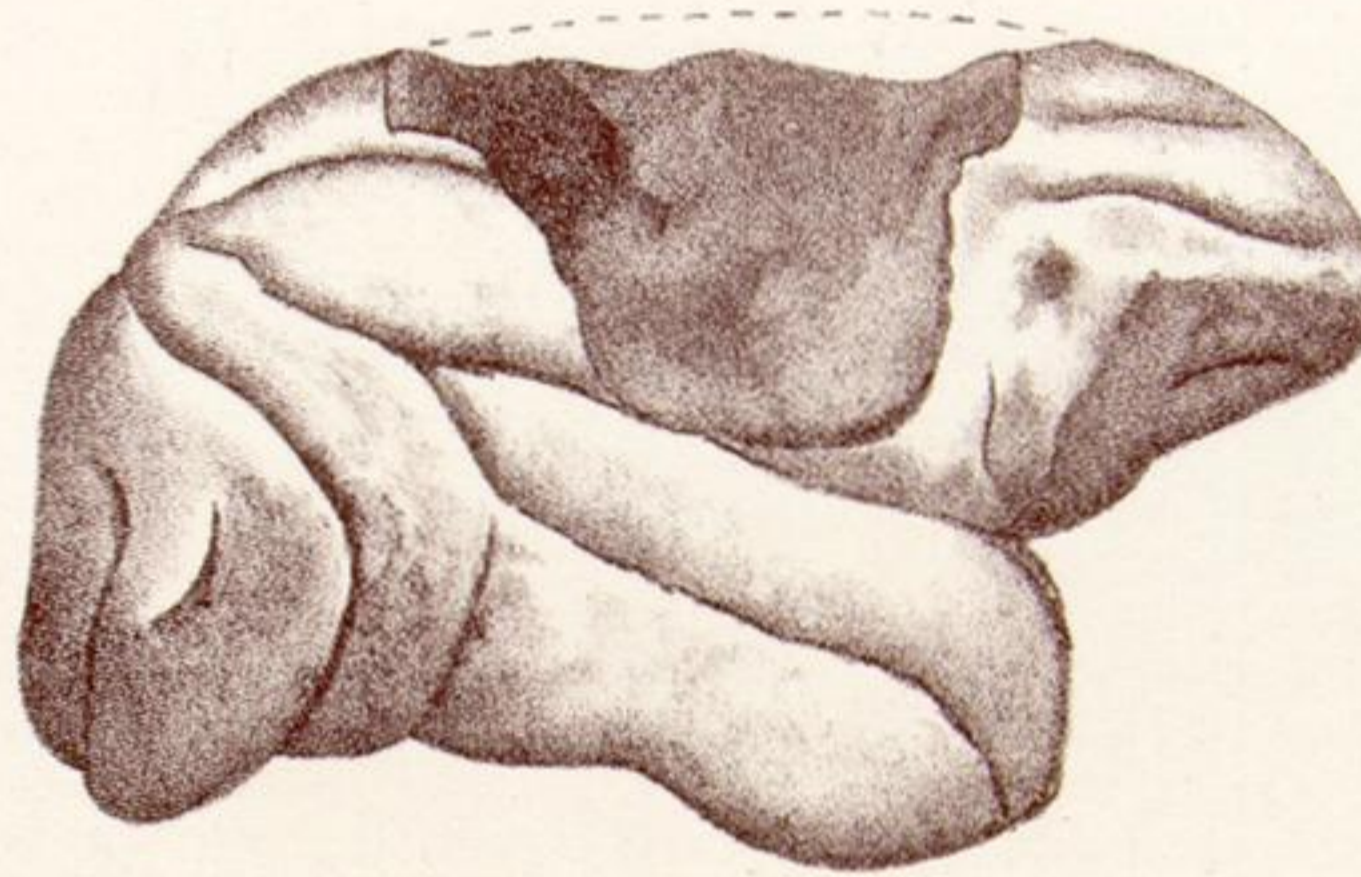
12.



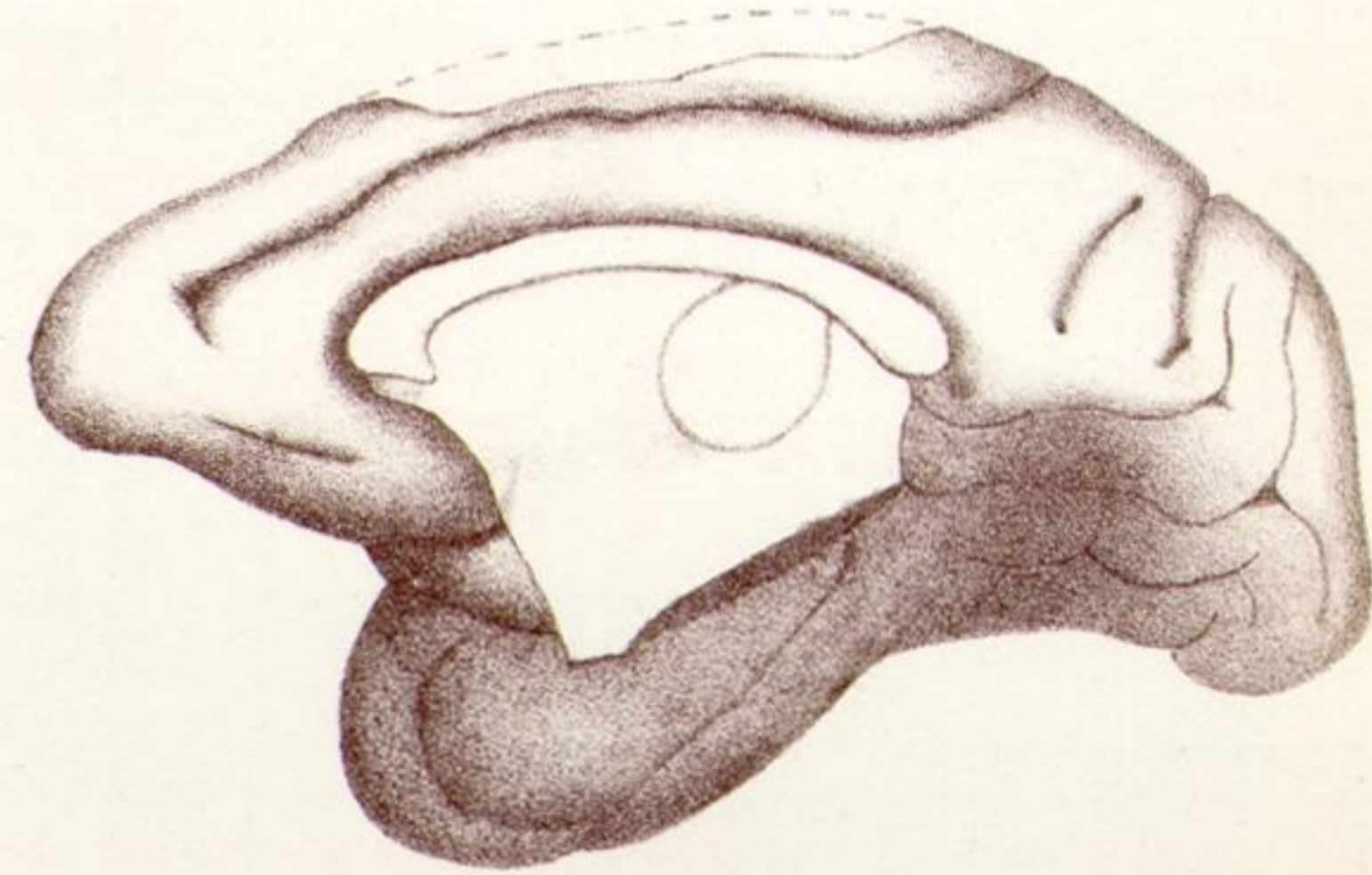
13.



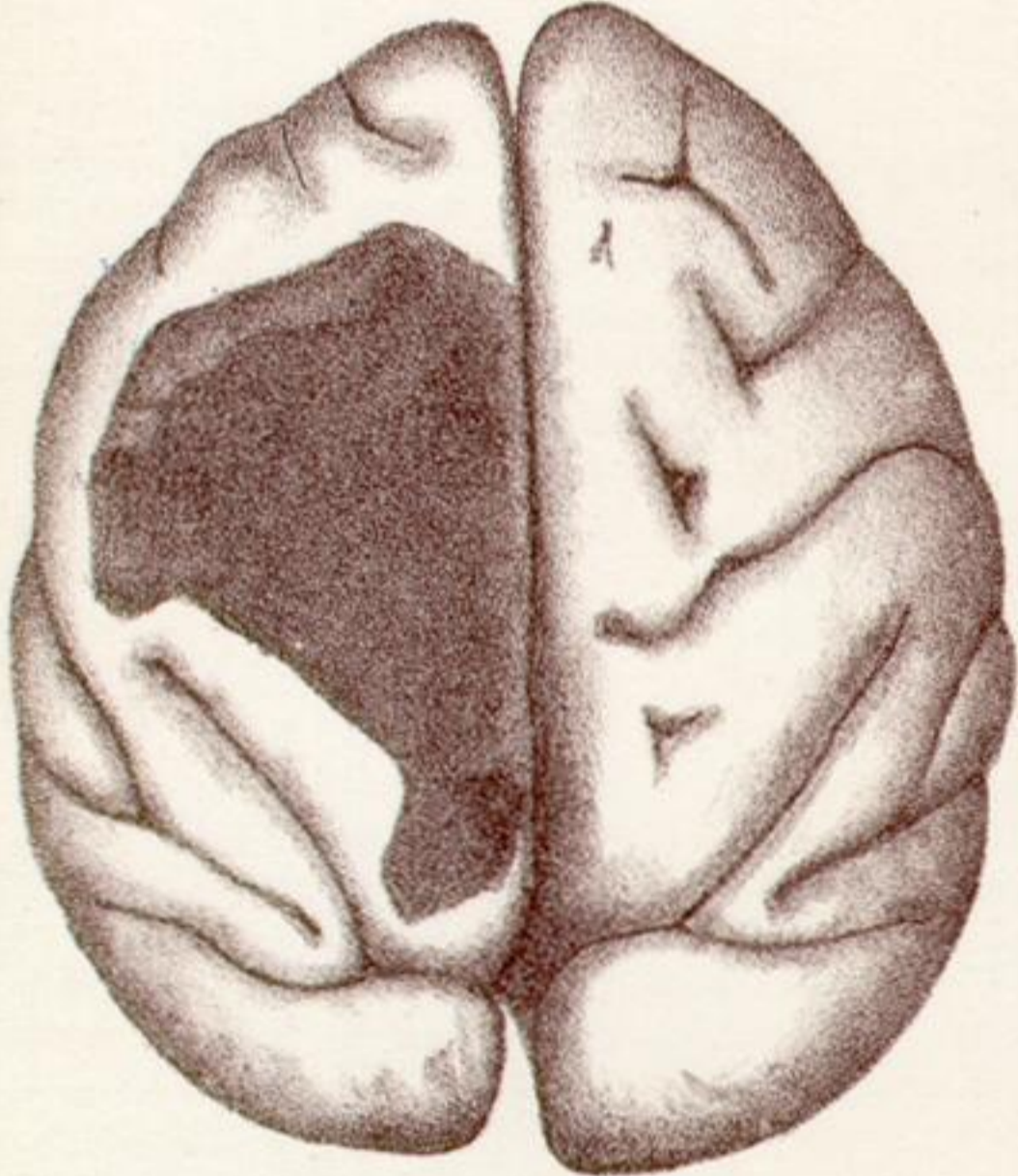
14.



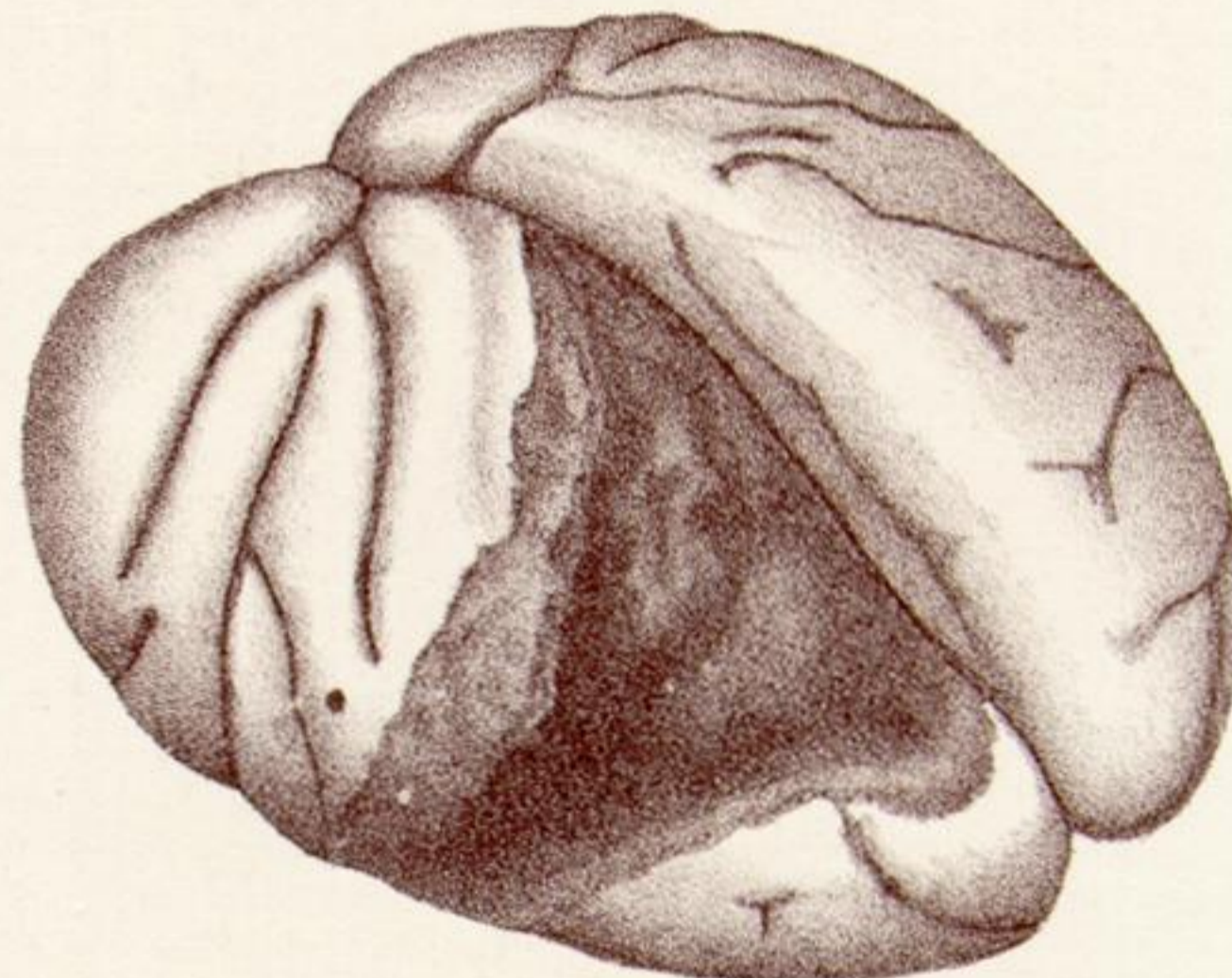
15A.



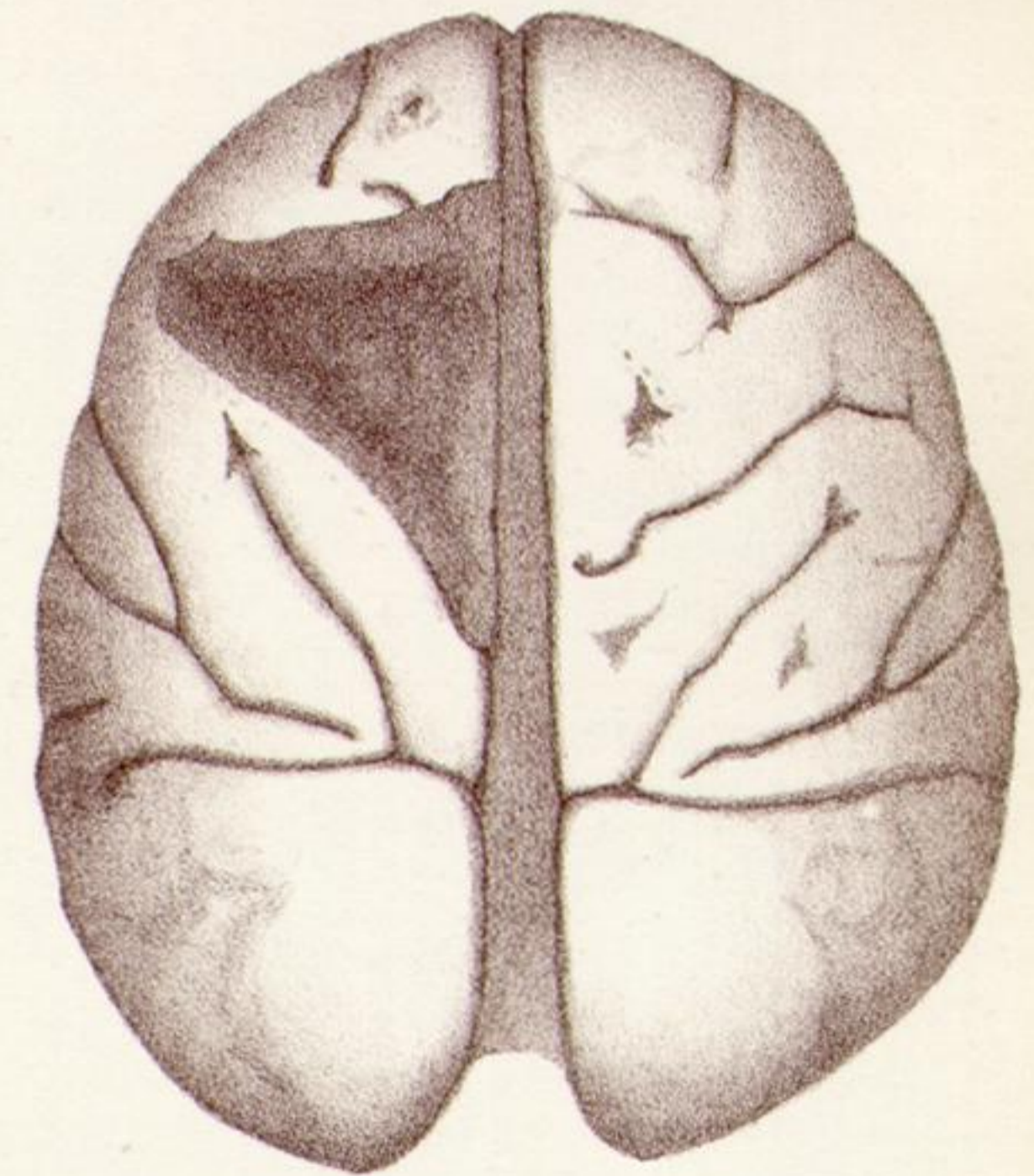
15B.



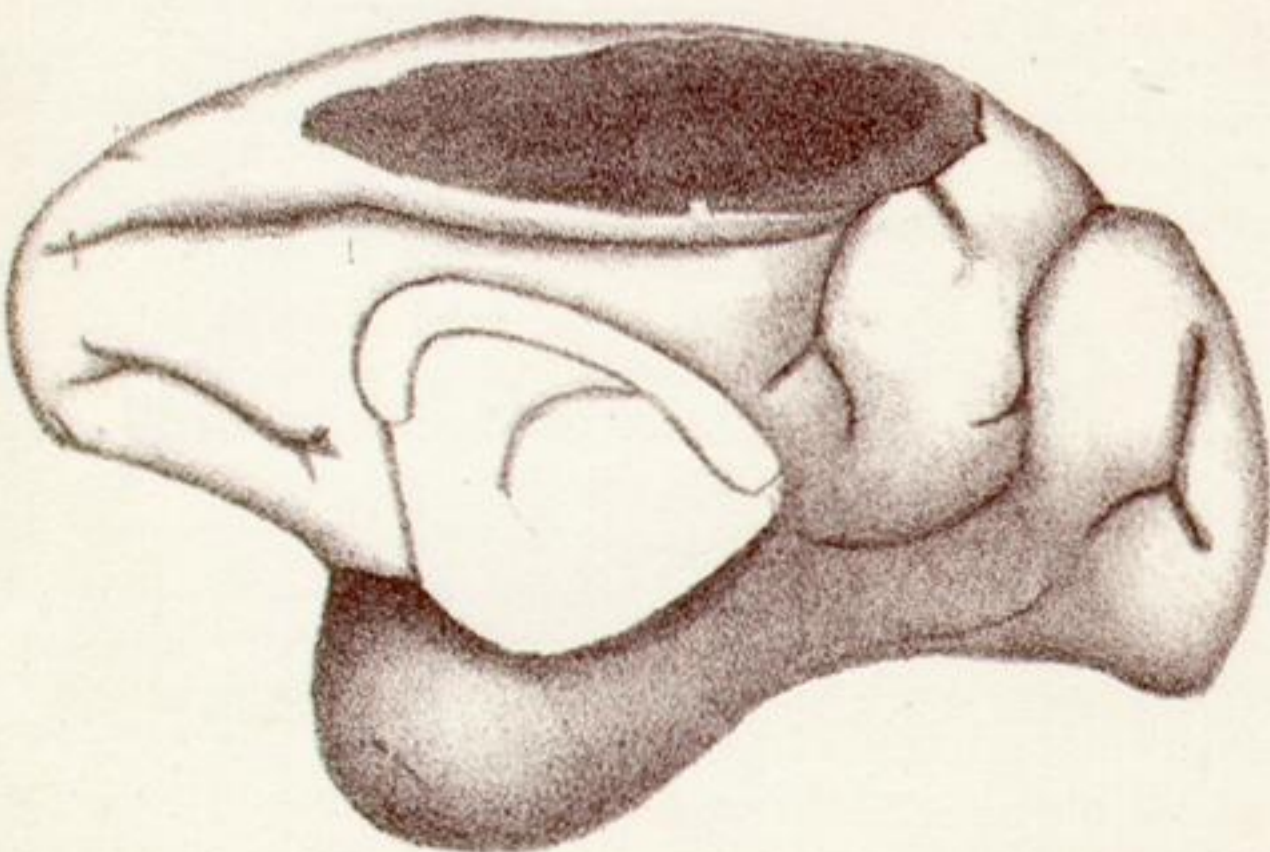
16.



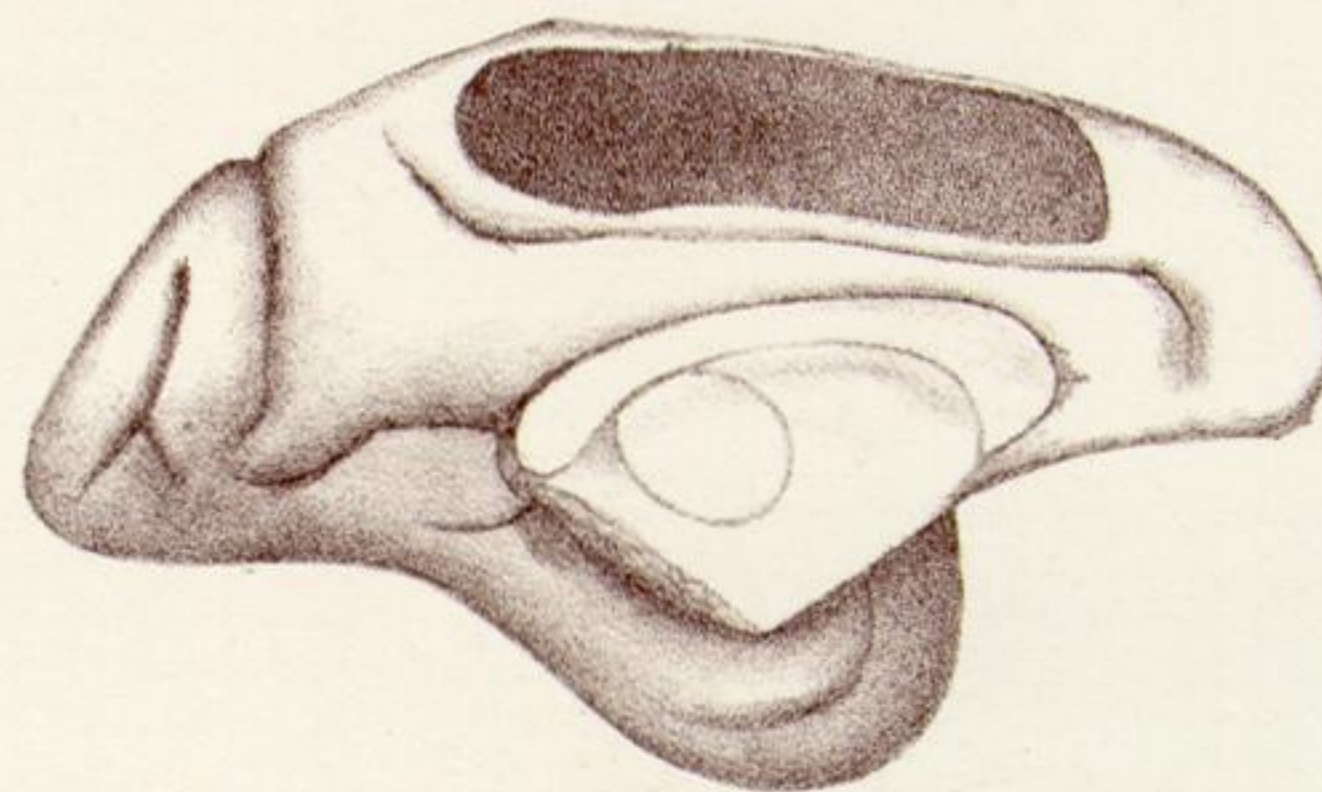
17.



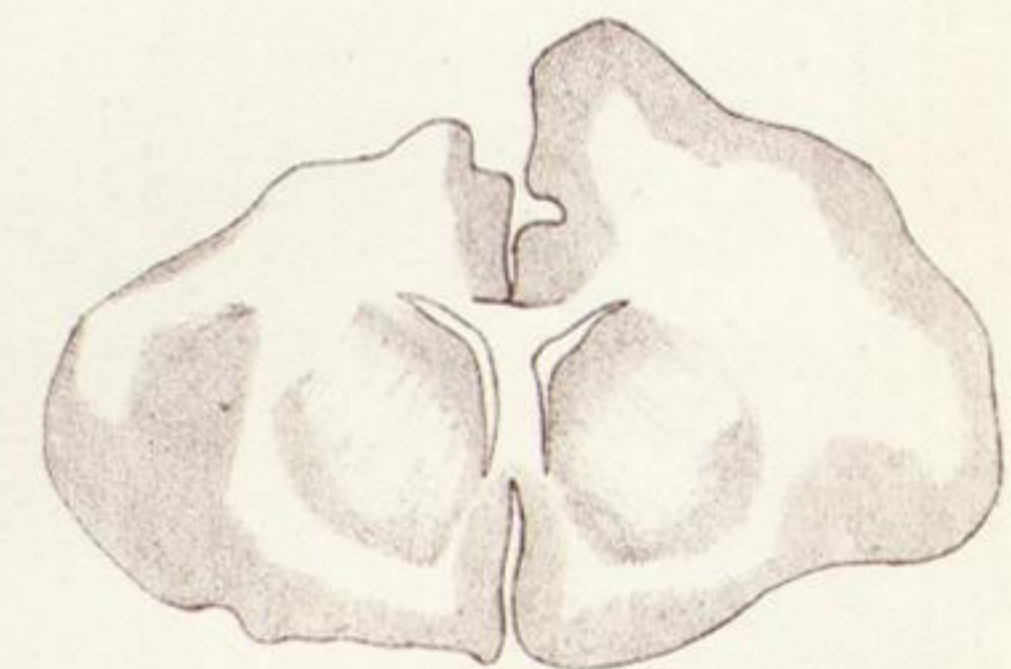
18.



19R.



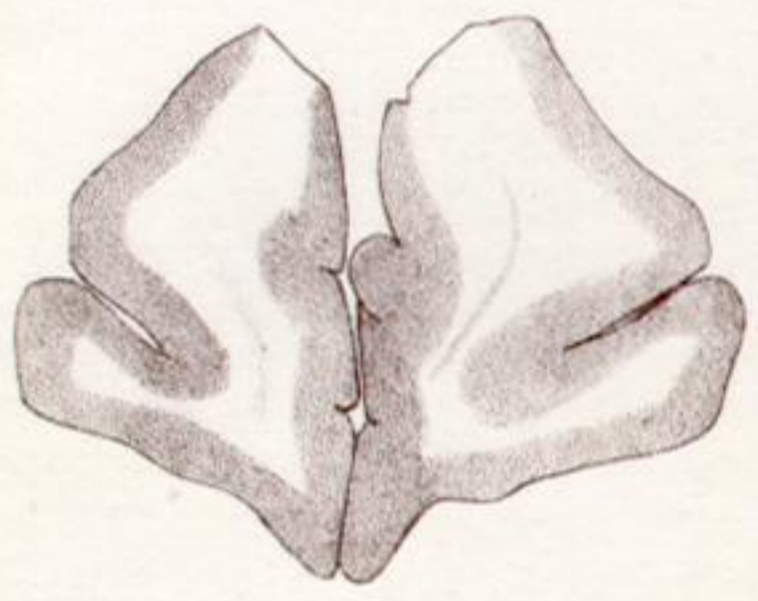
19L.



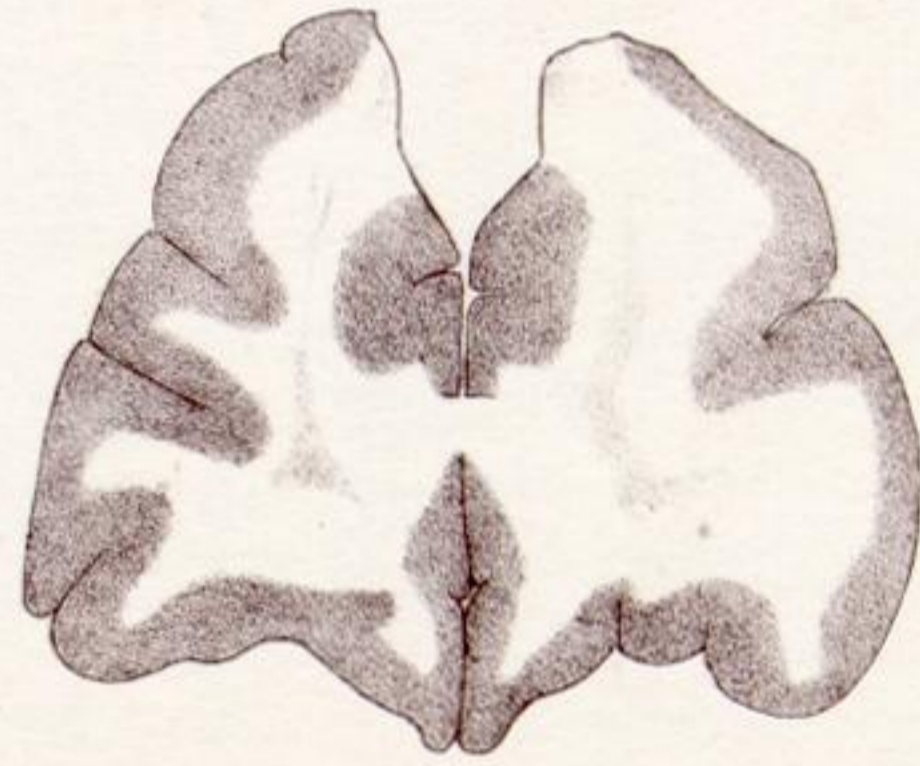18A.



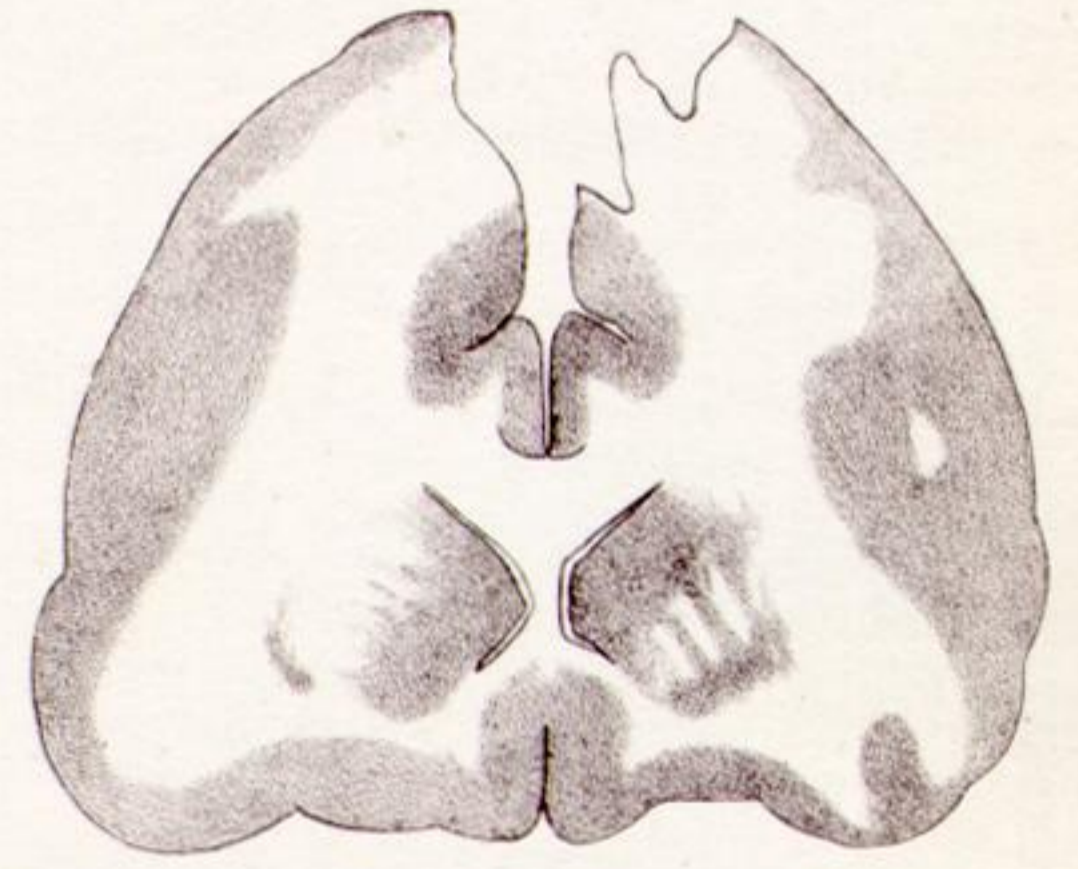20



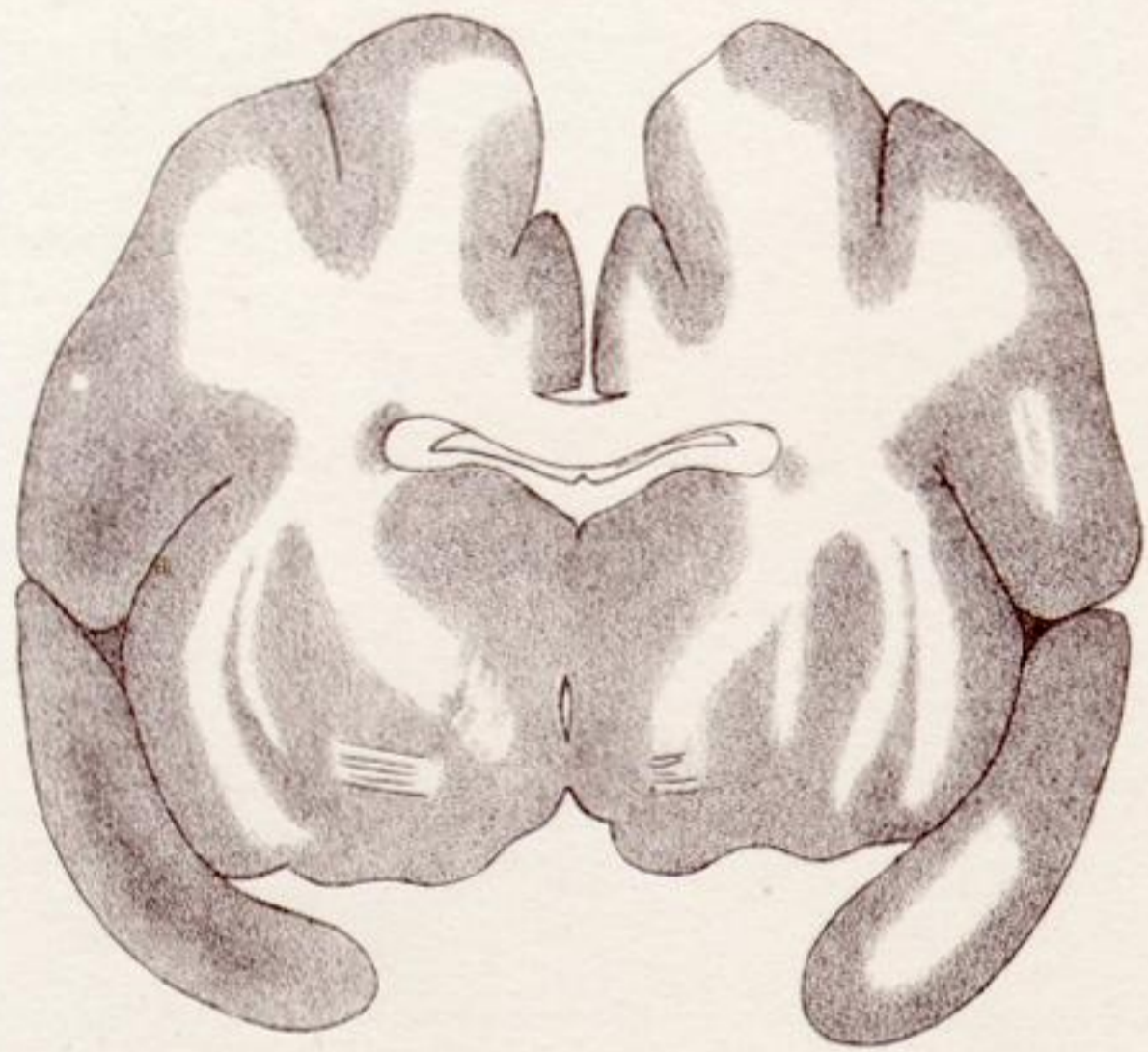
20A.



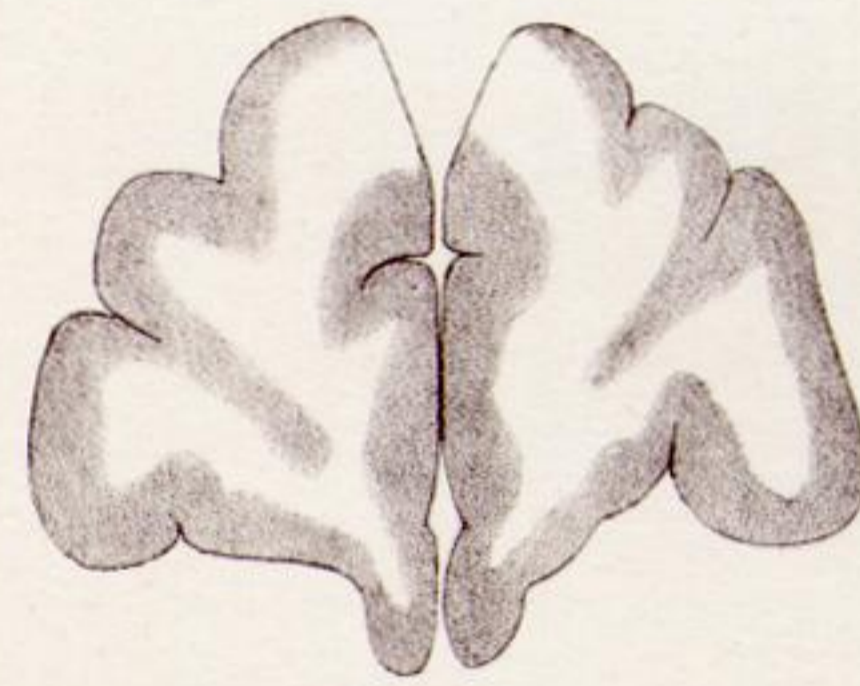
20B.



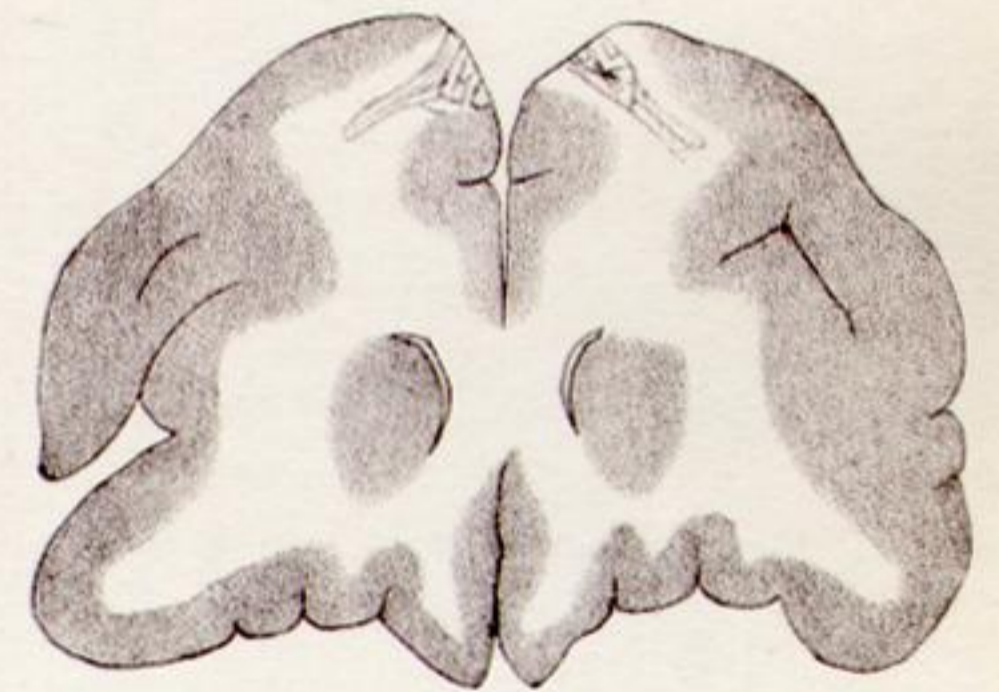20C.



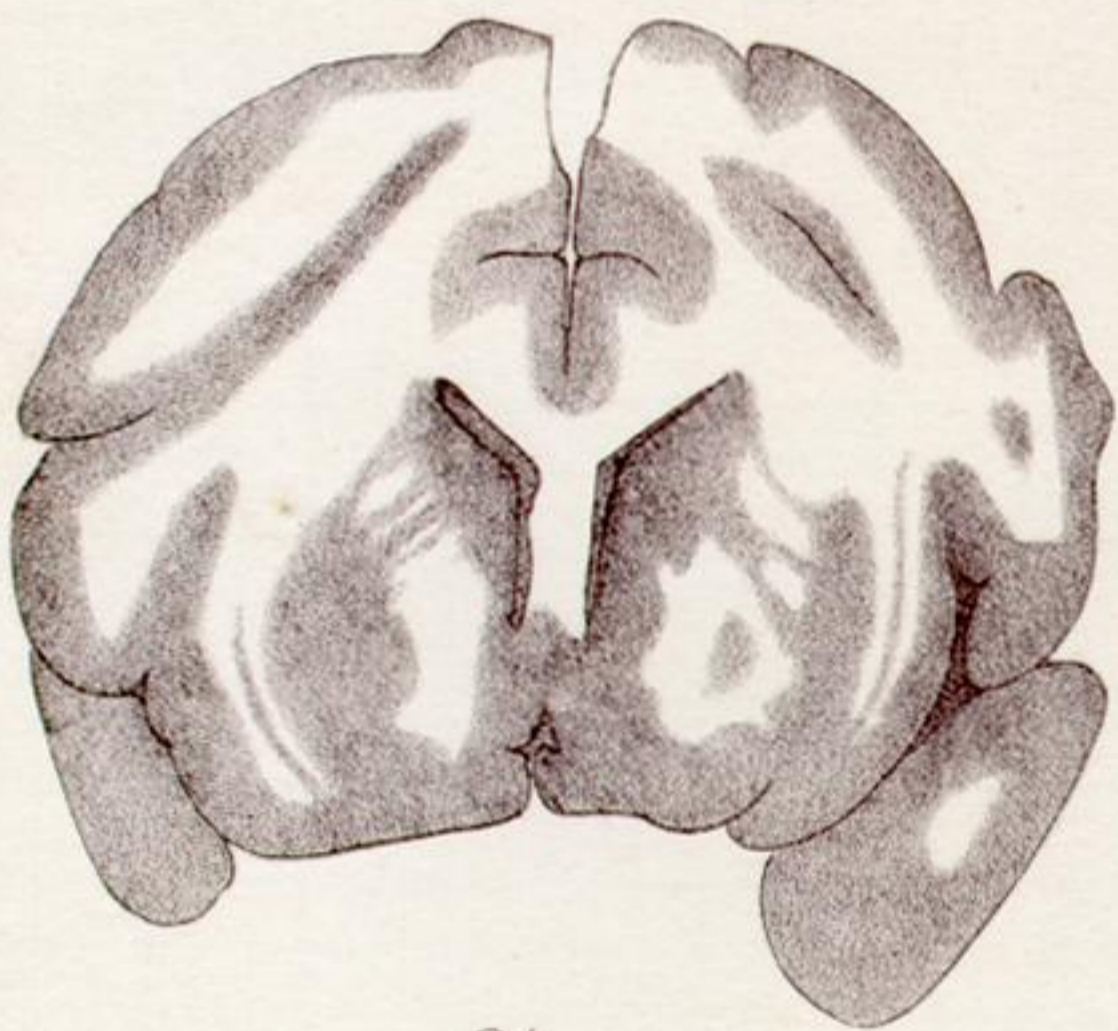
20D.



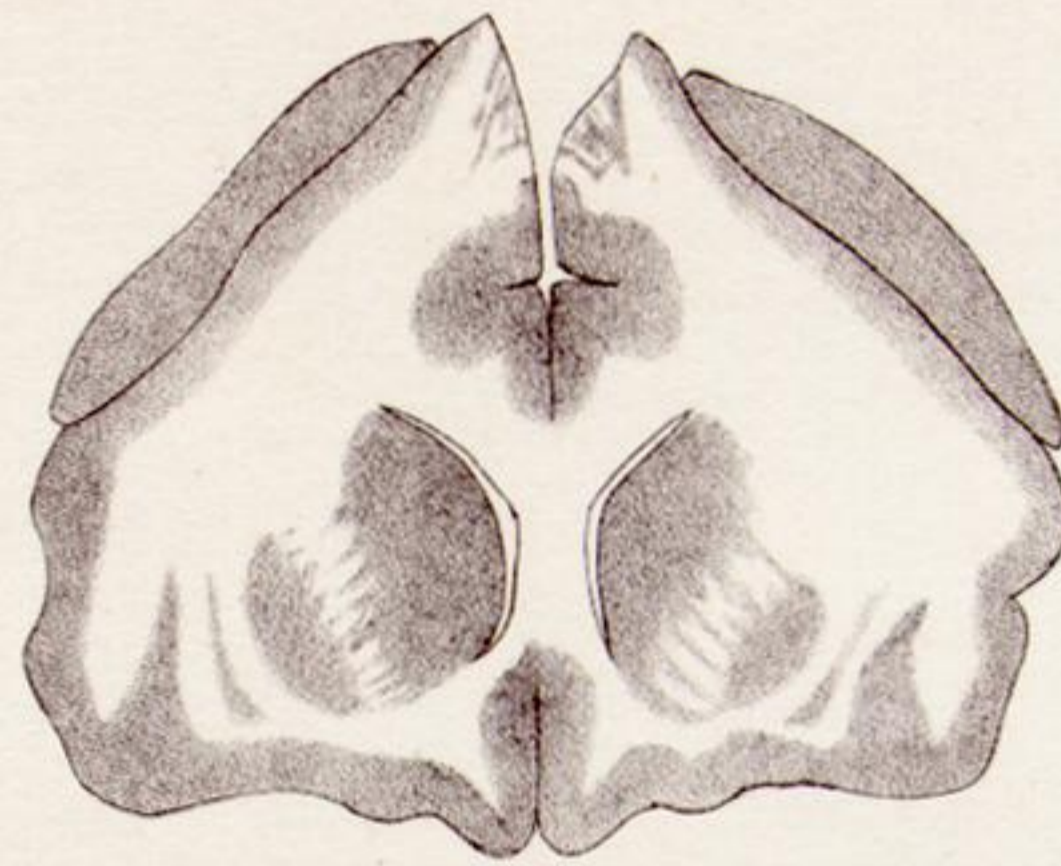21A.



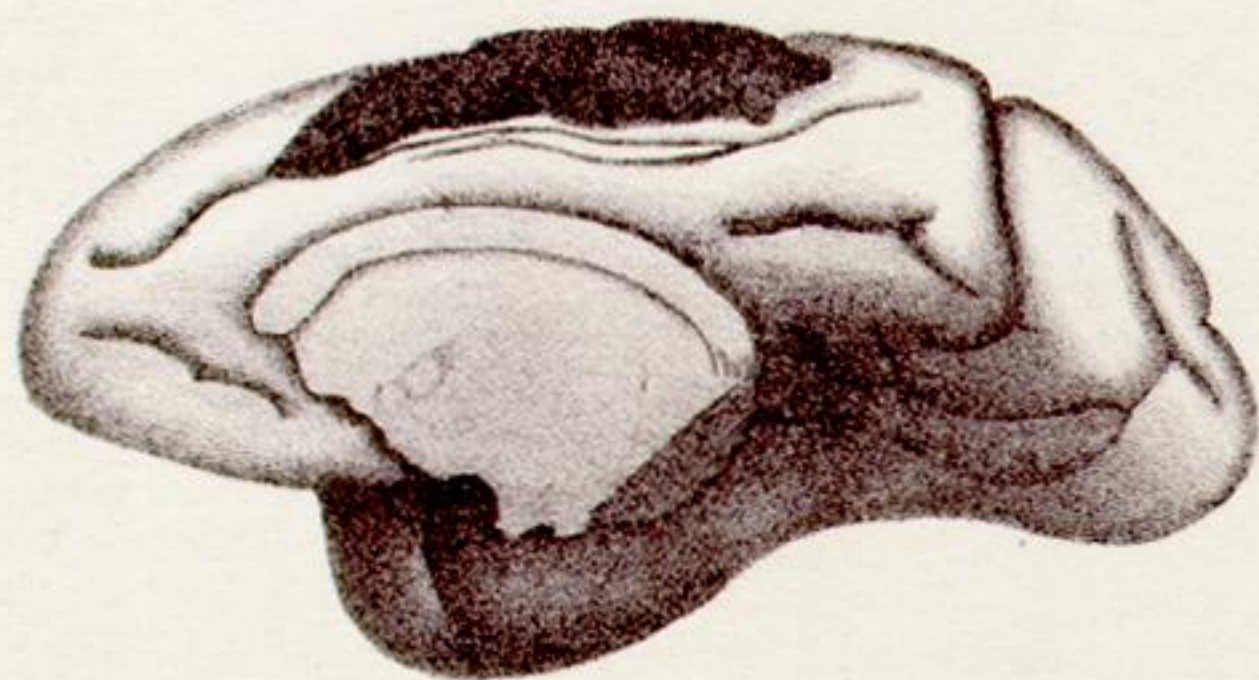
21B.



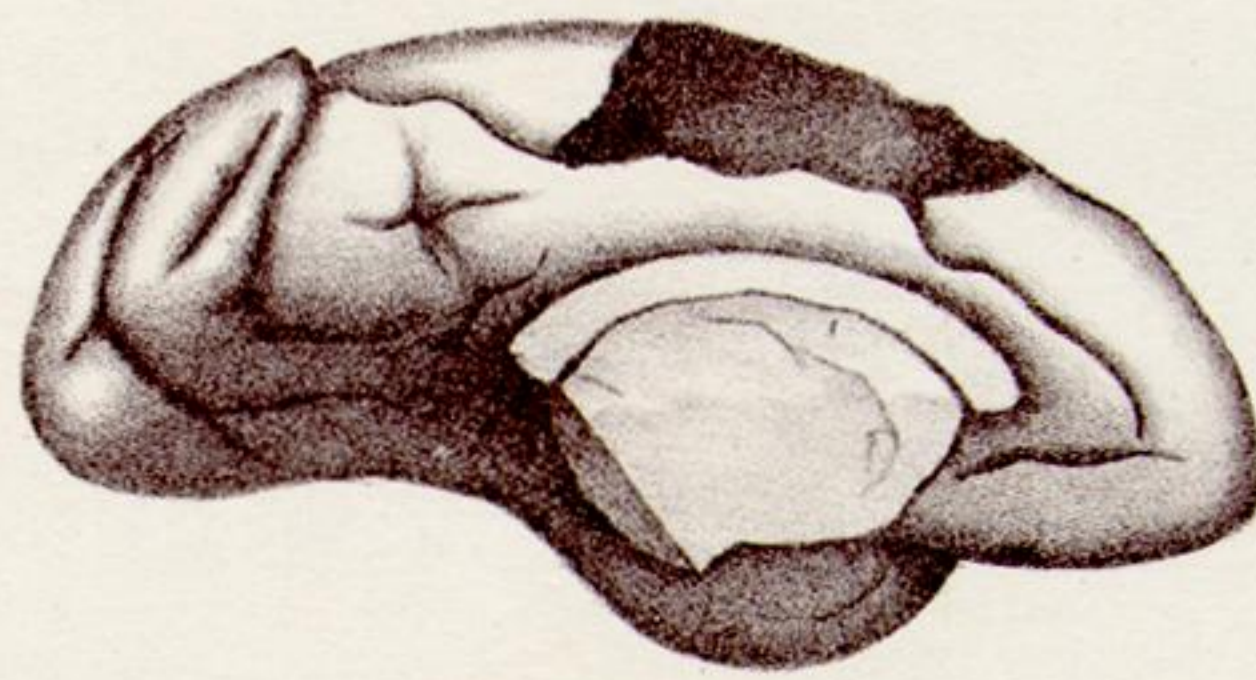
21D.



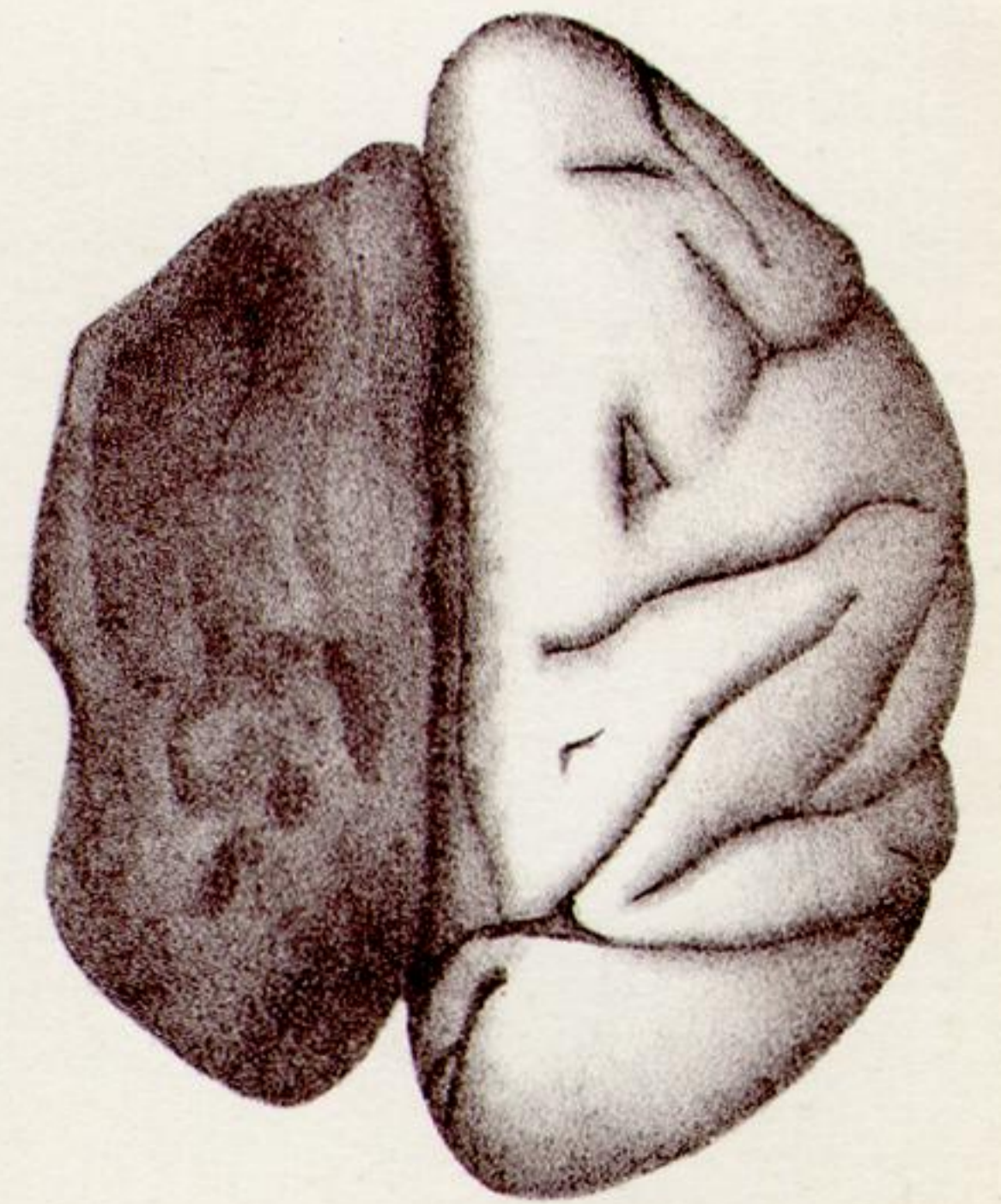
21C.



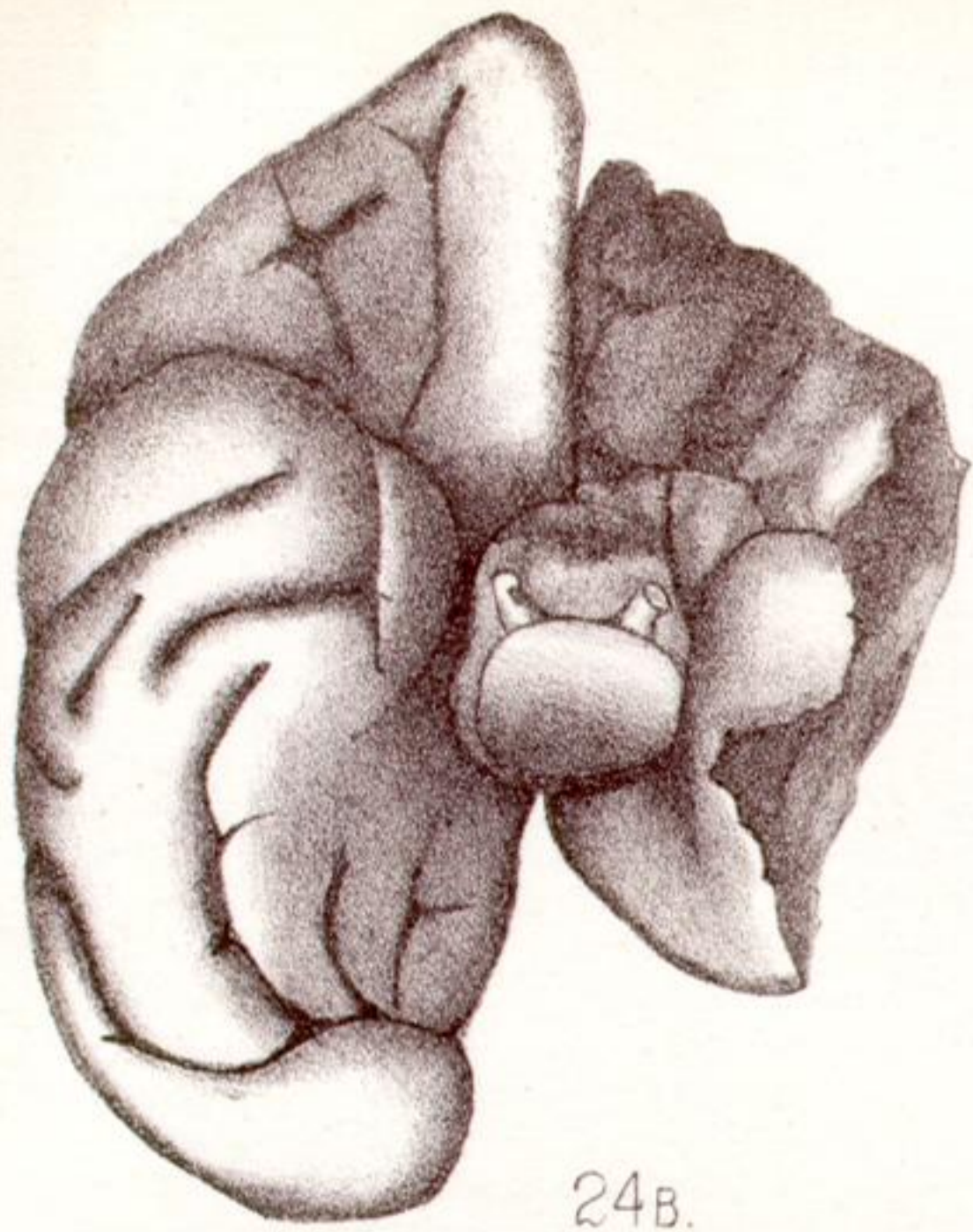
23R.



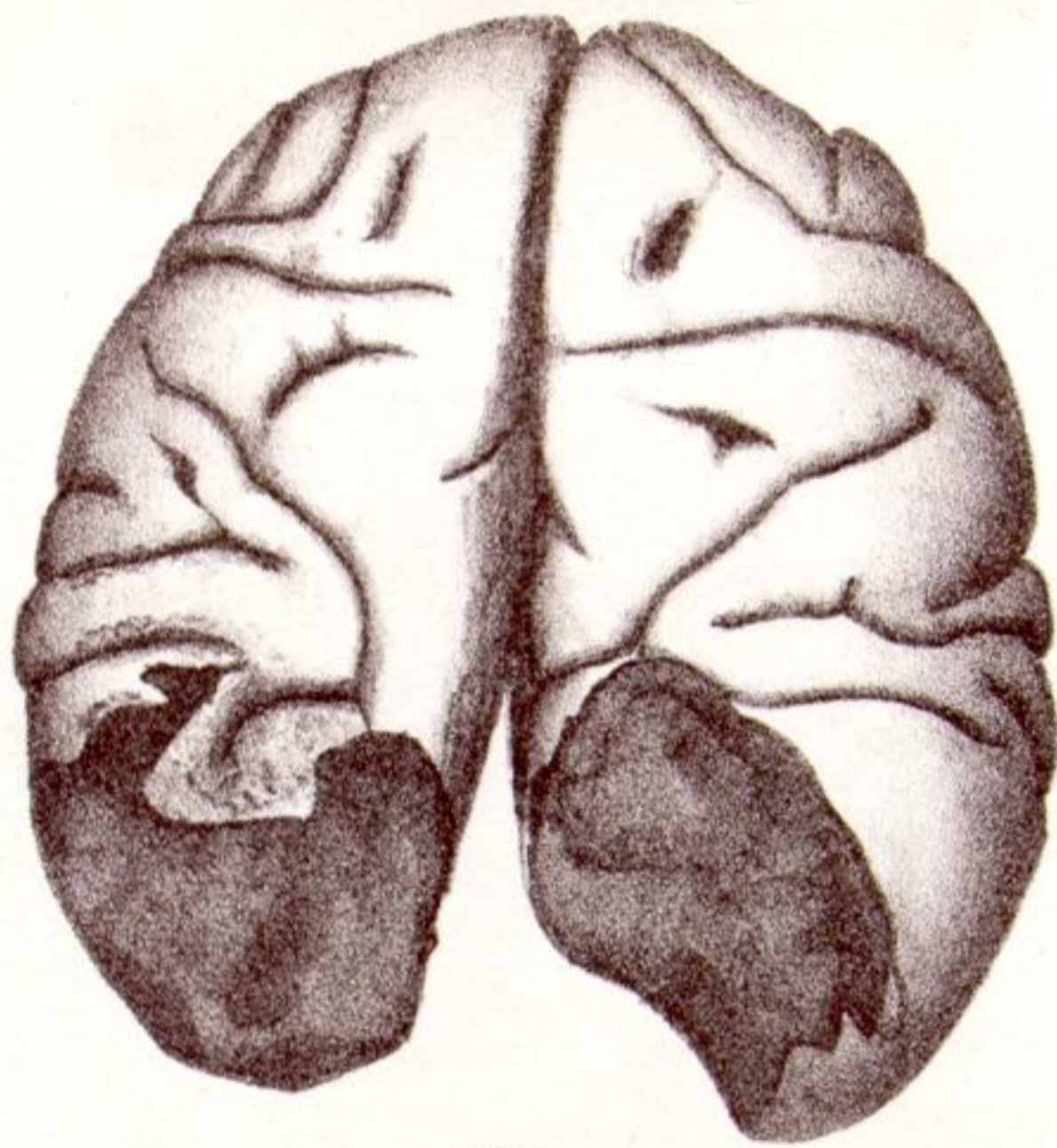
23L.



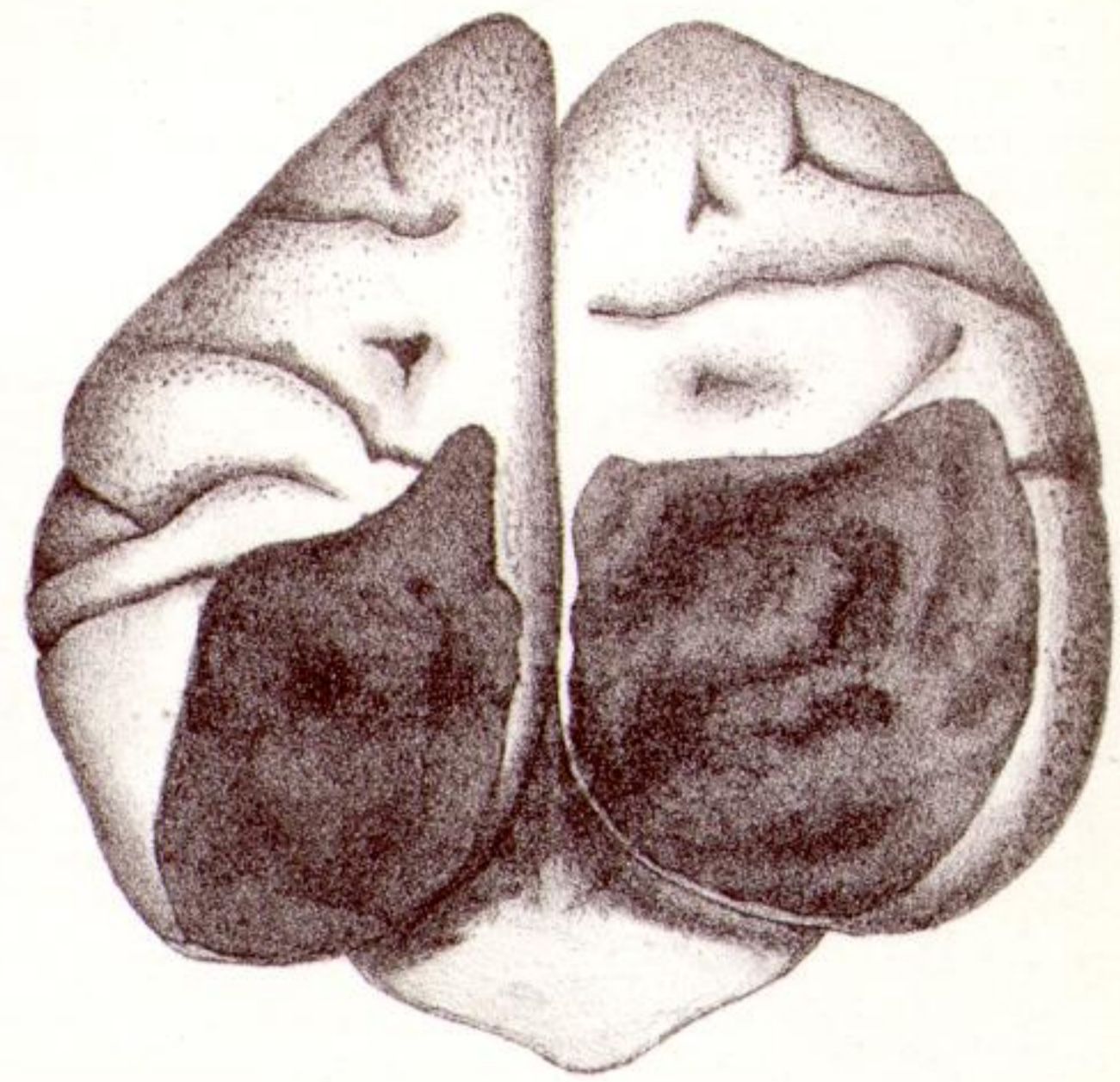
24A.



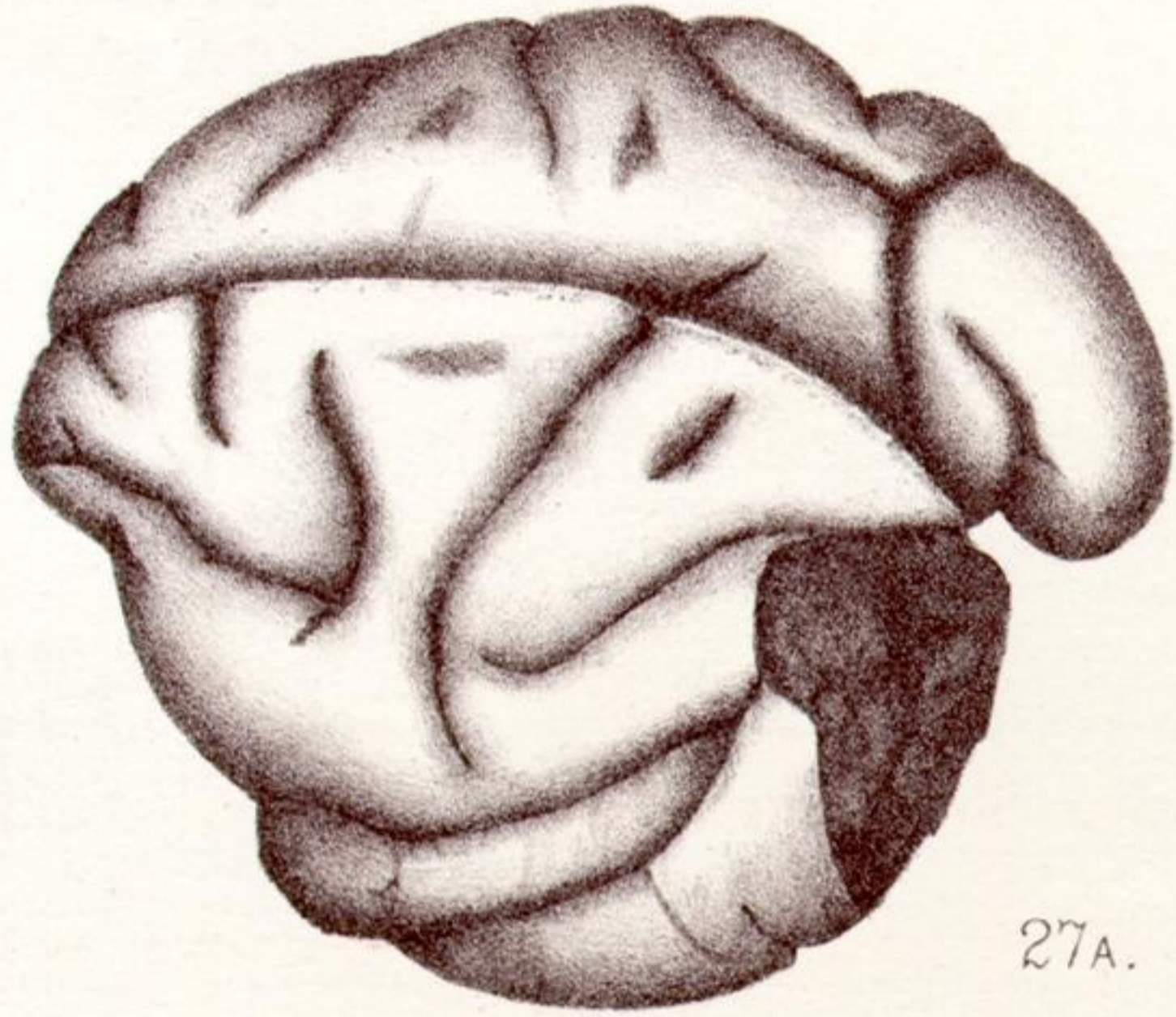
24B.



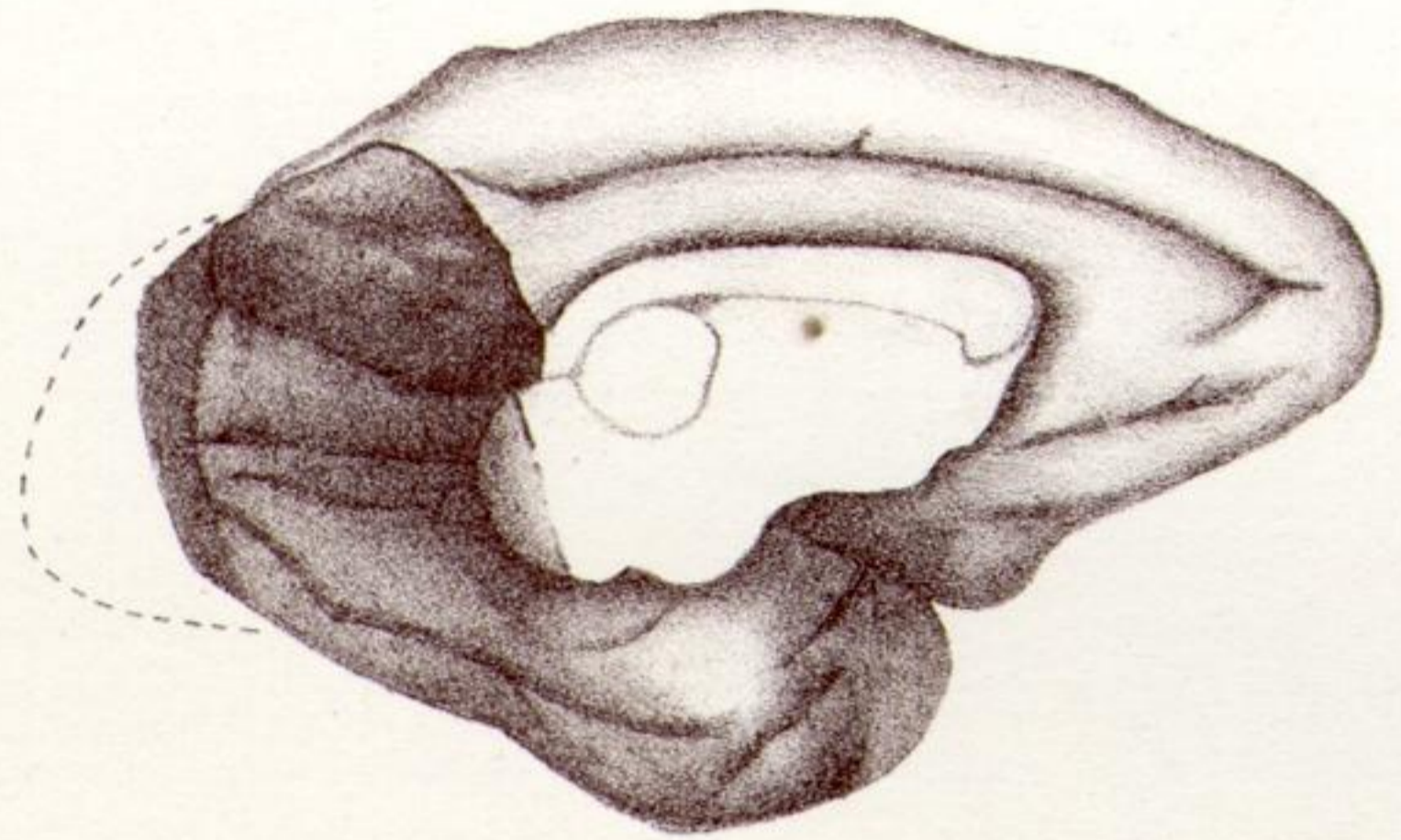
25.



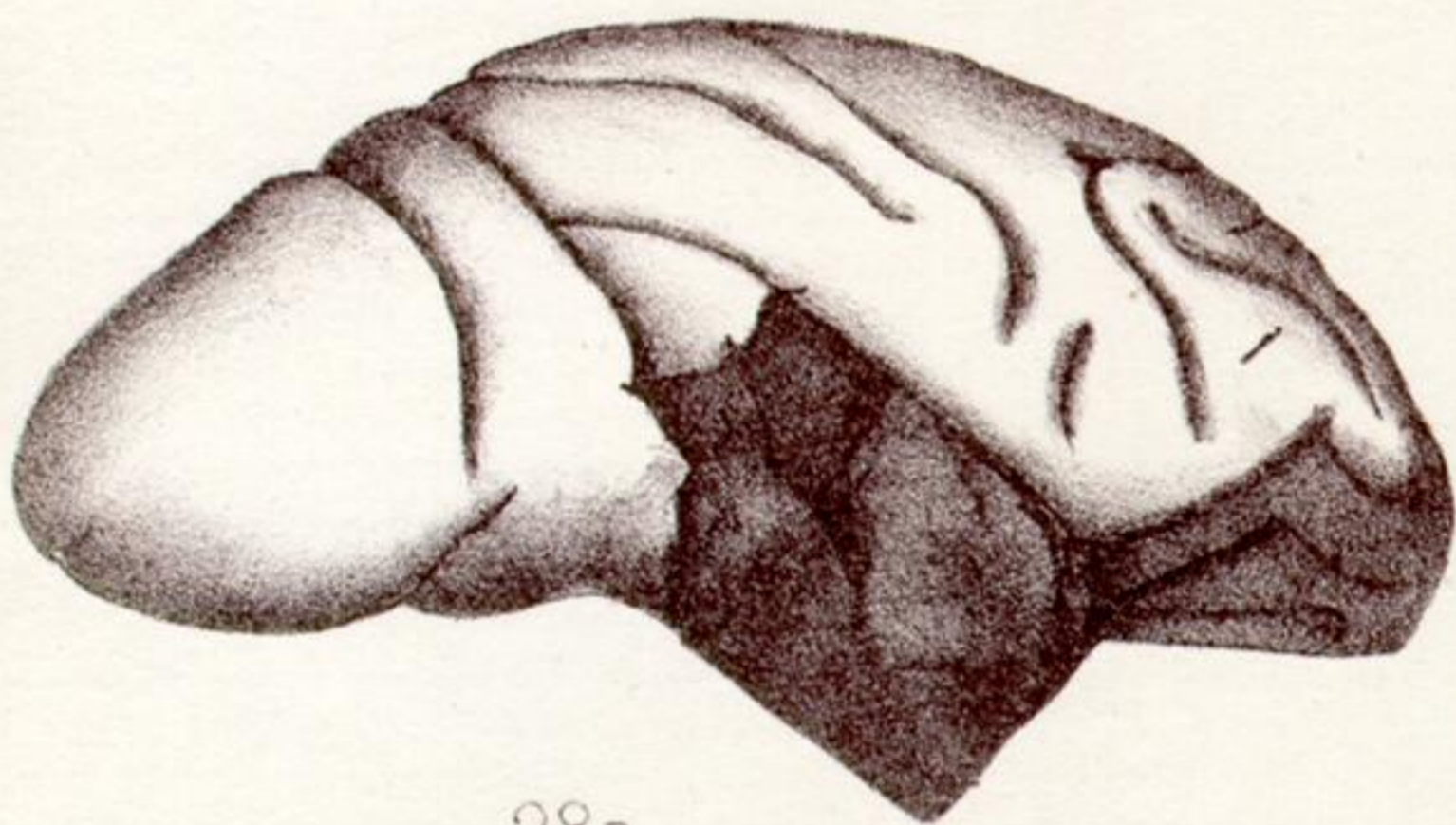
26.



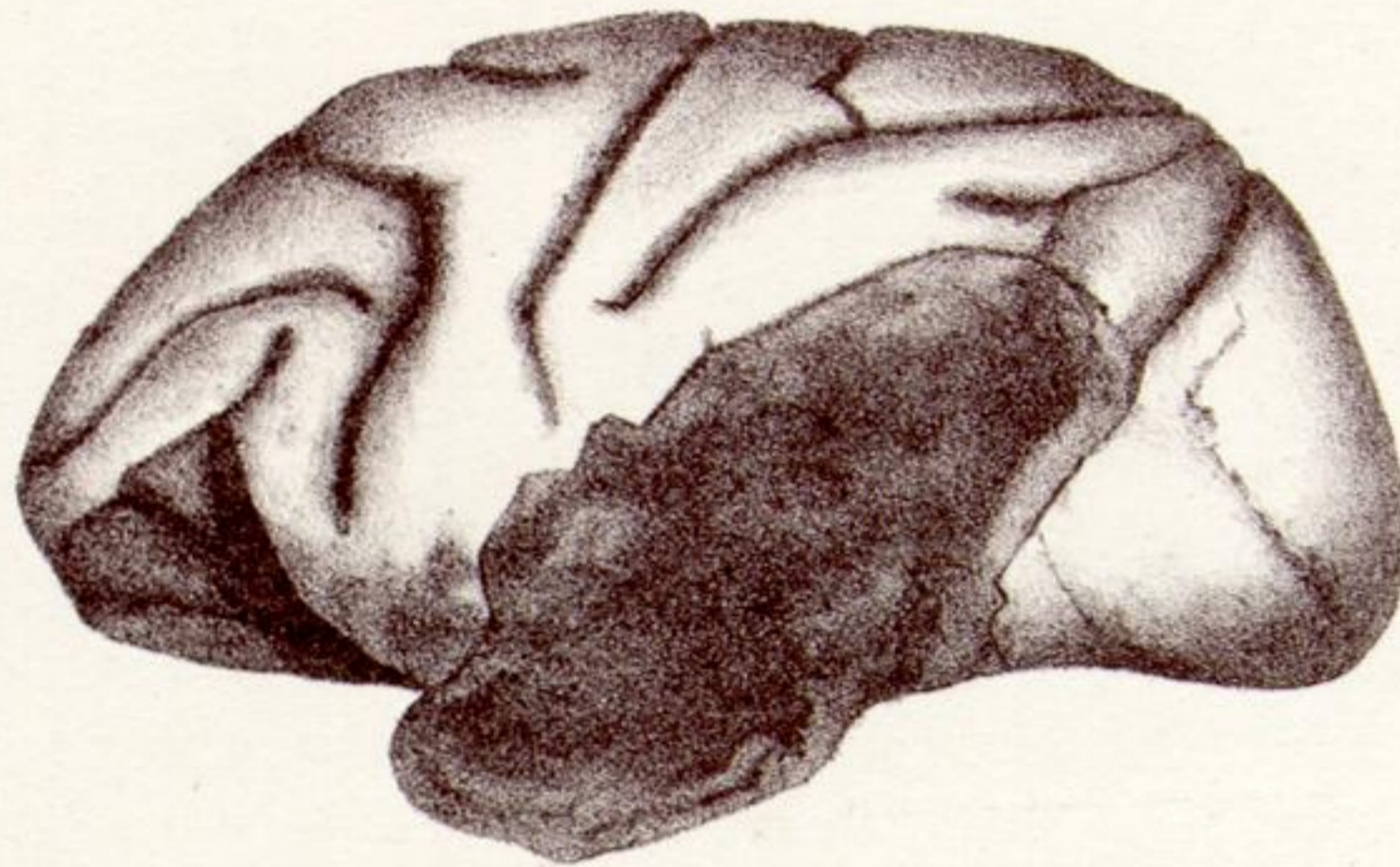27A.



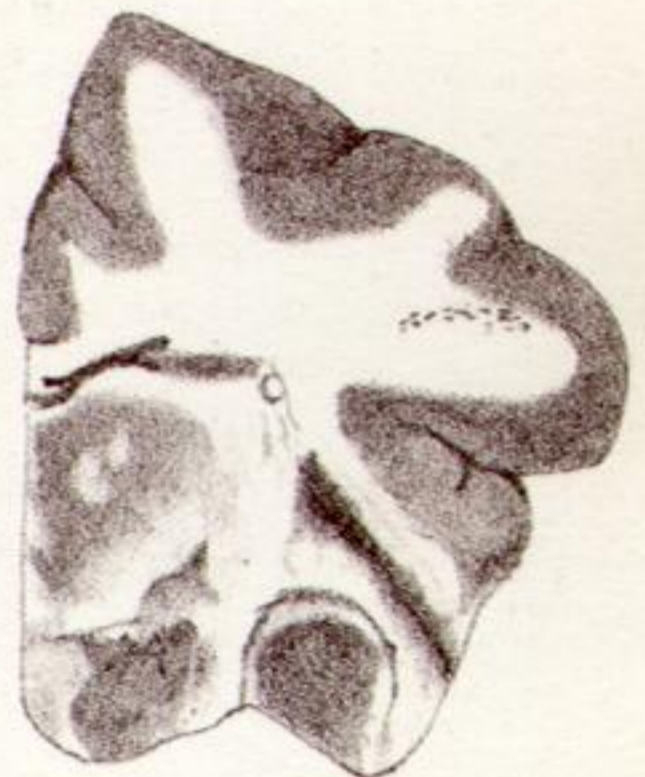27B.



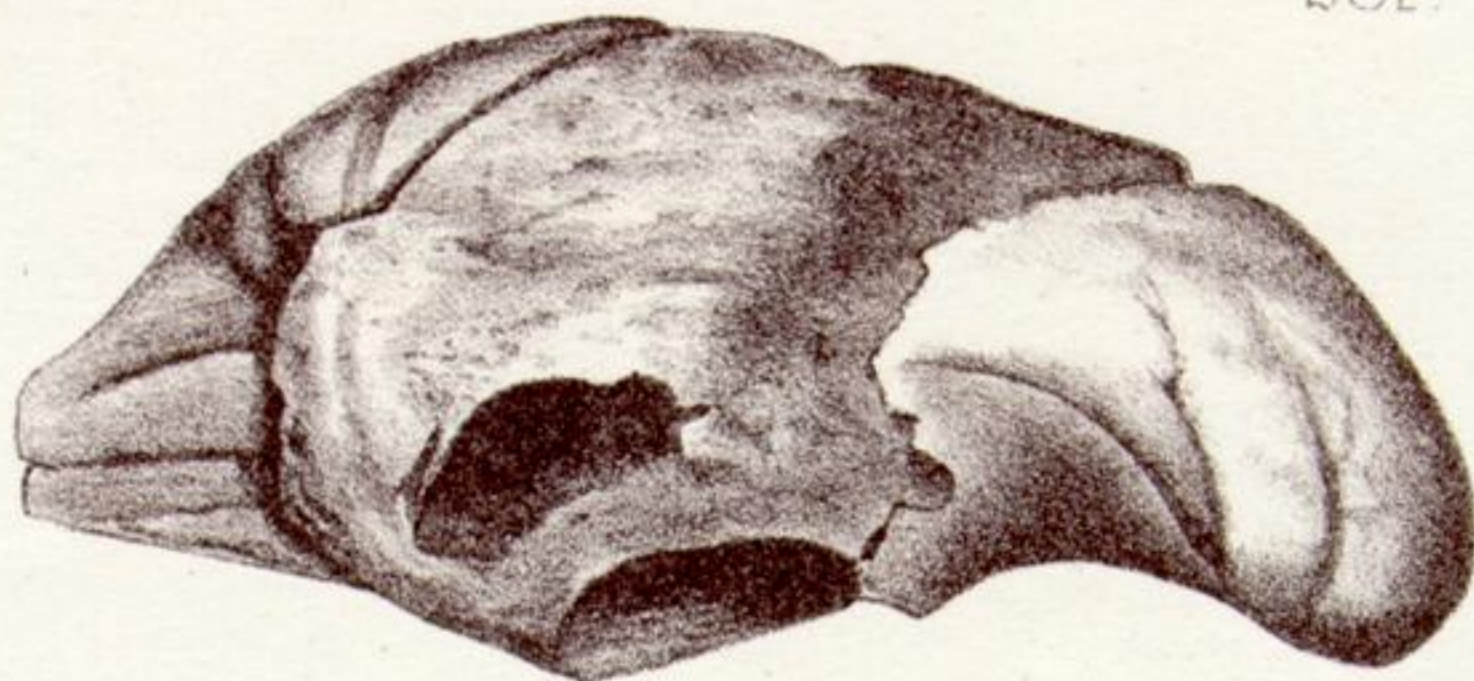28R.



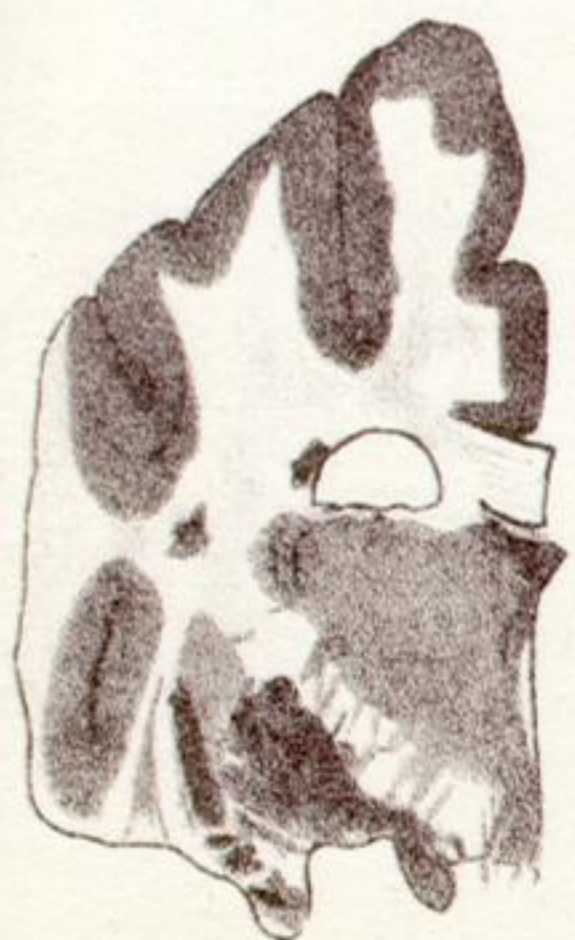28L.



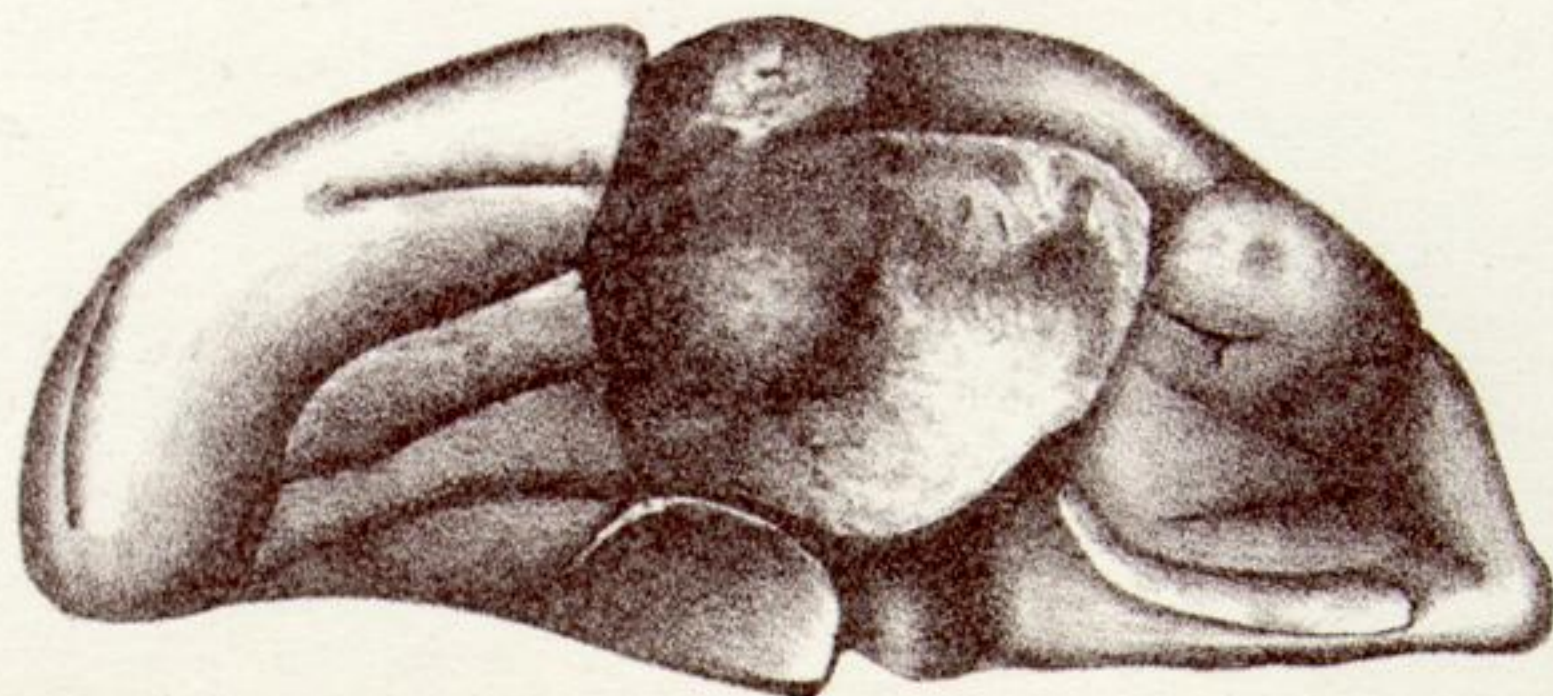28R''



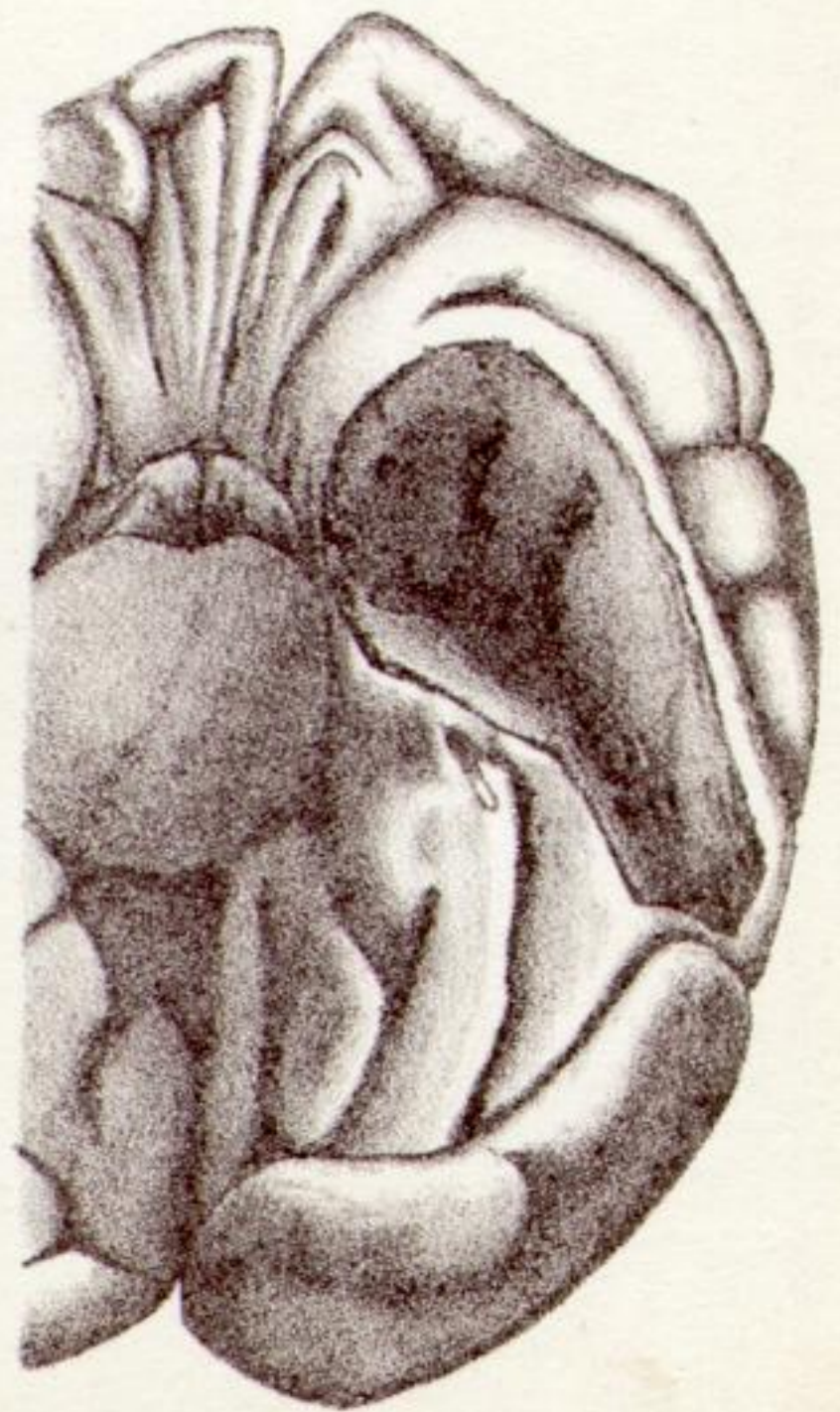
28L'



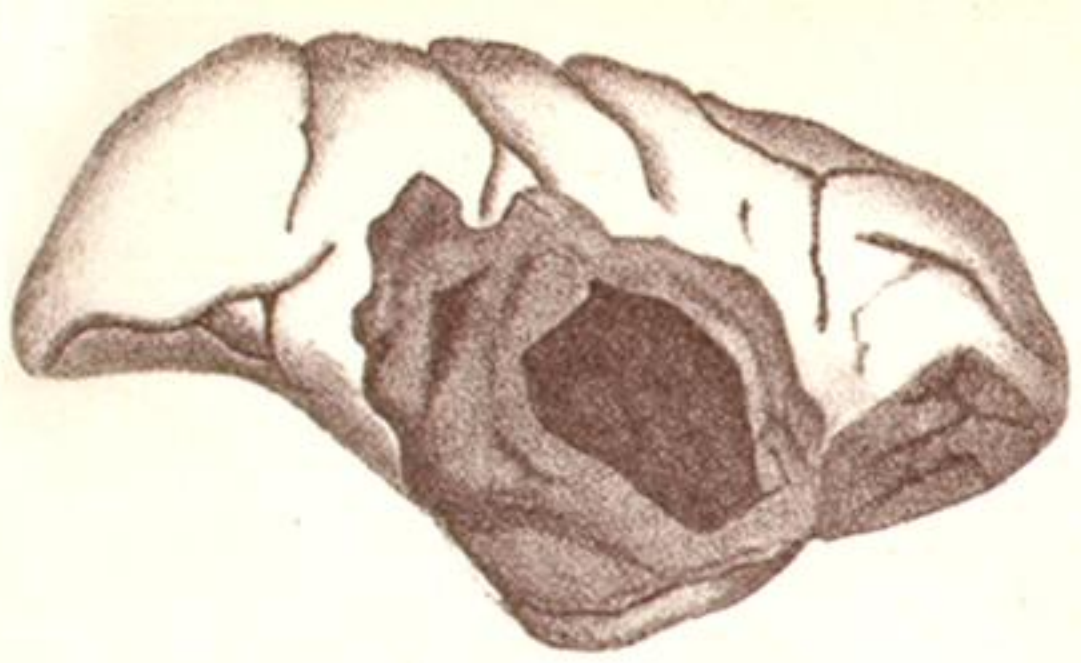
28L''



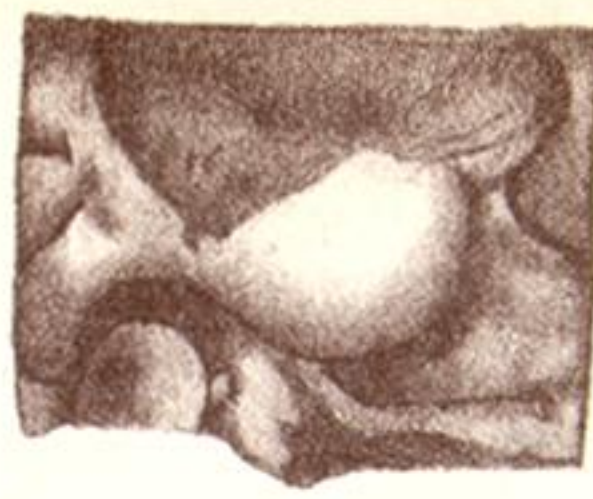28R'



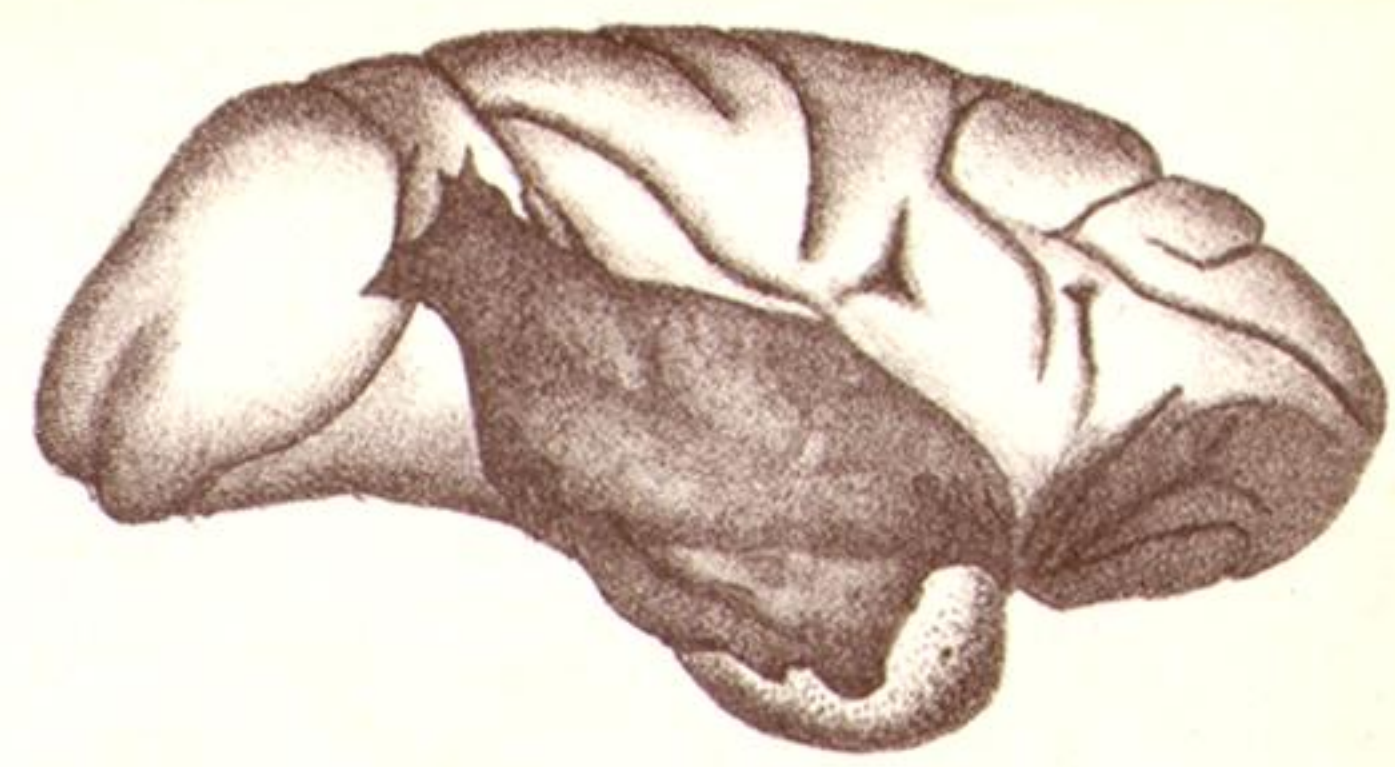
29.



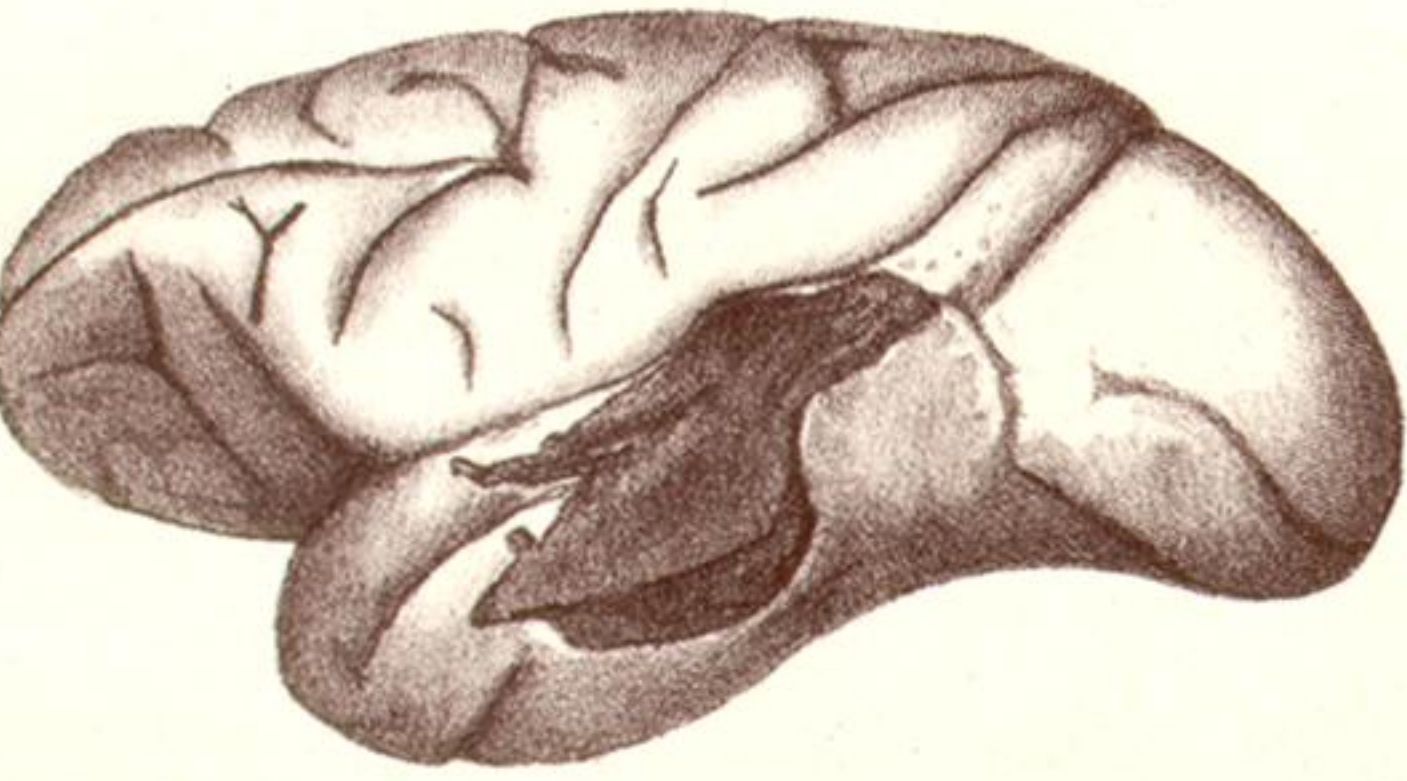
30A.



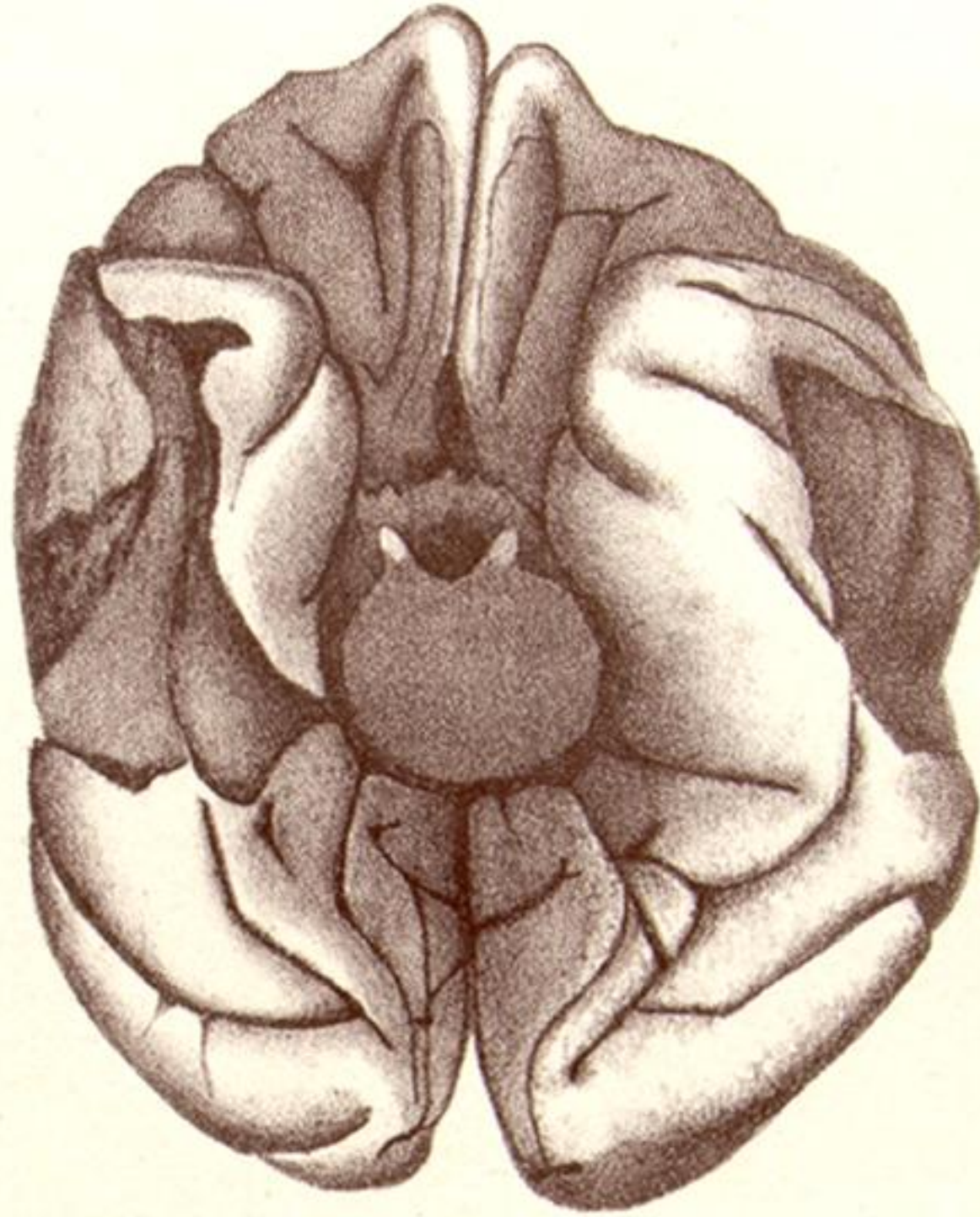
30B.



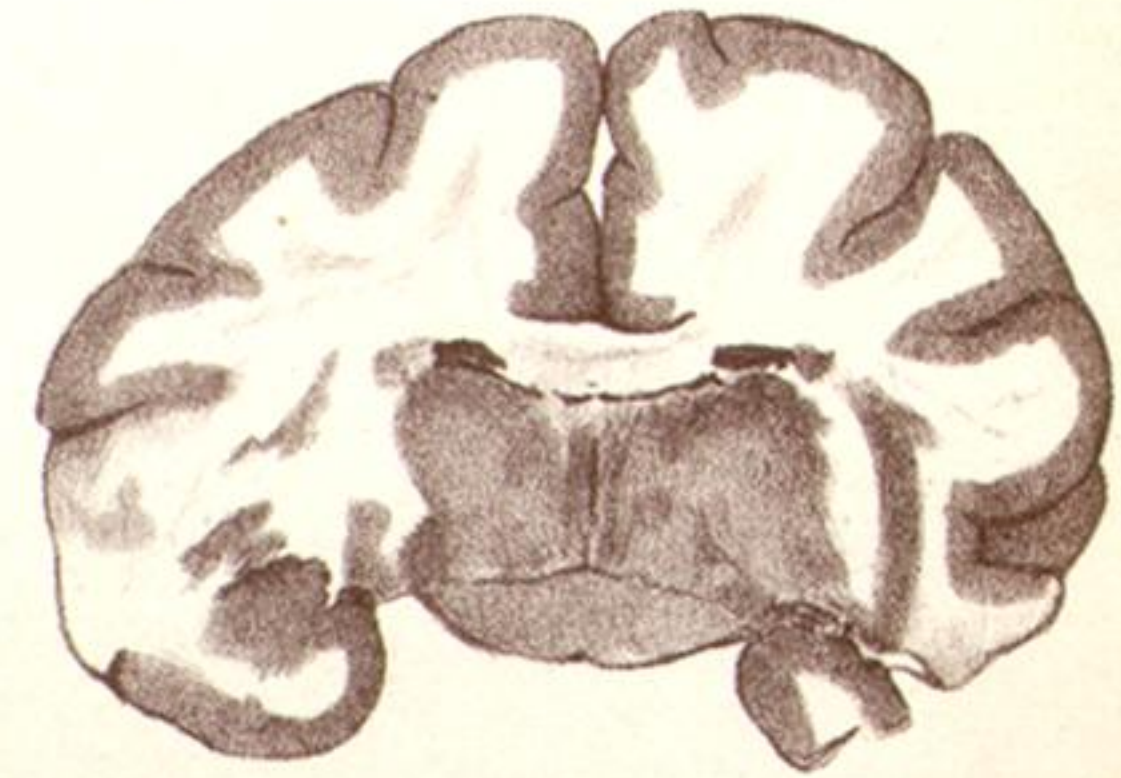
31A.



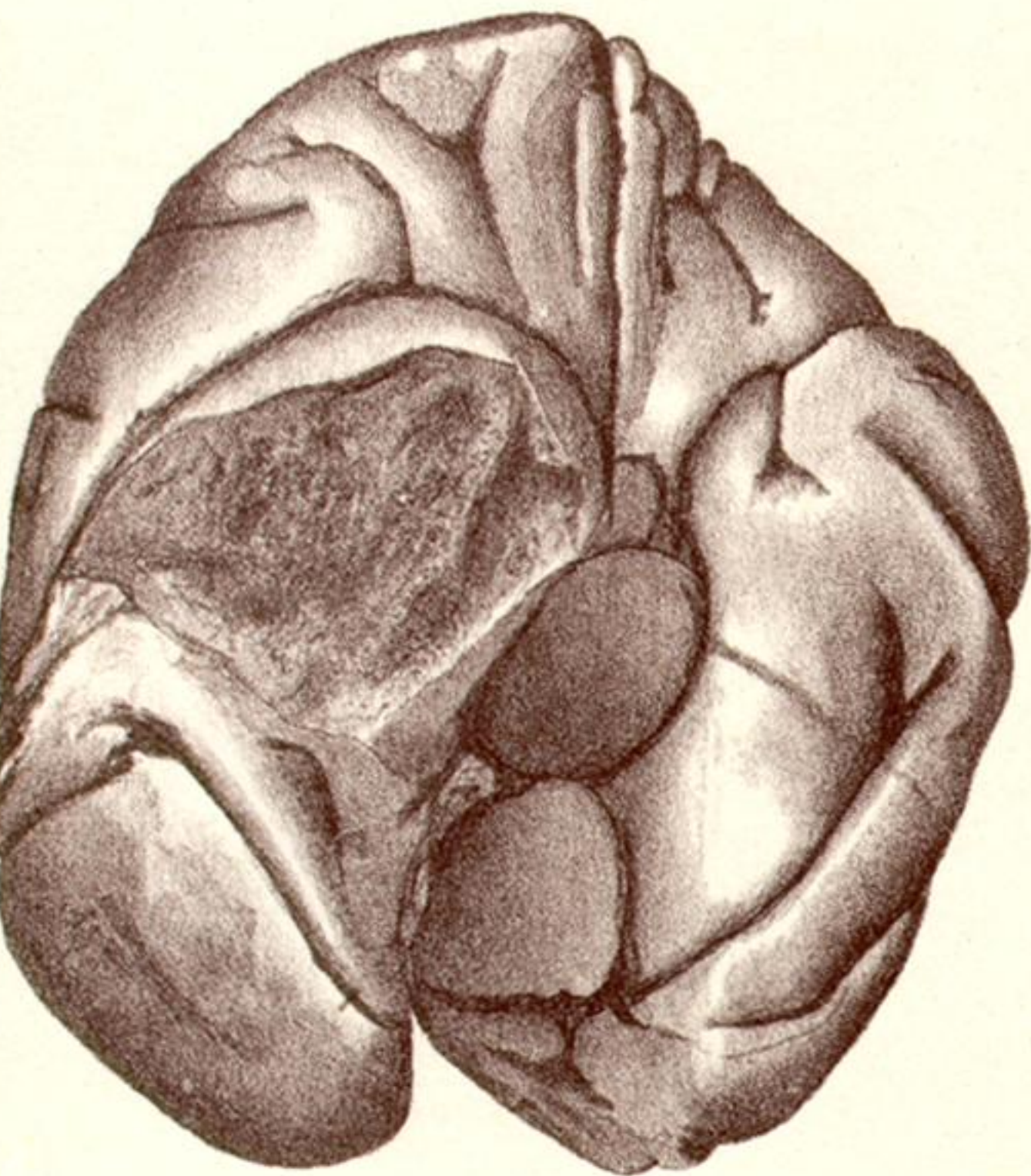
31B.



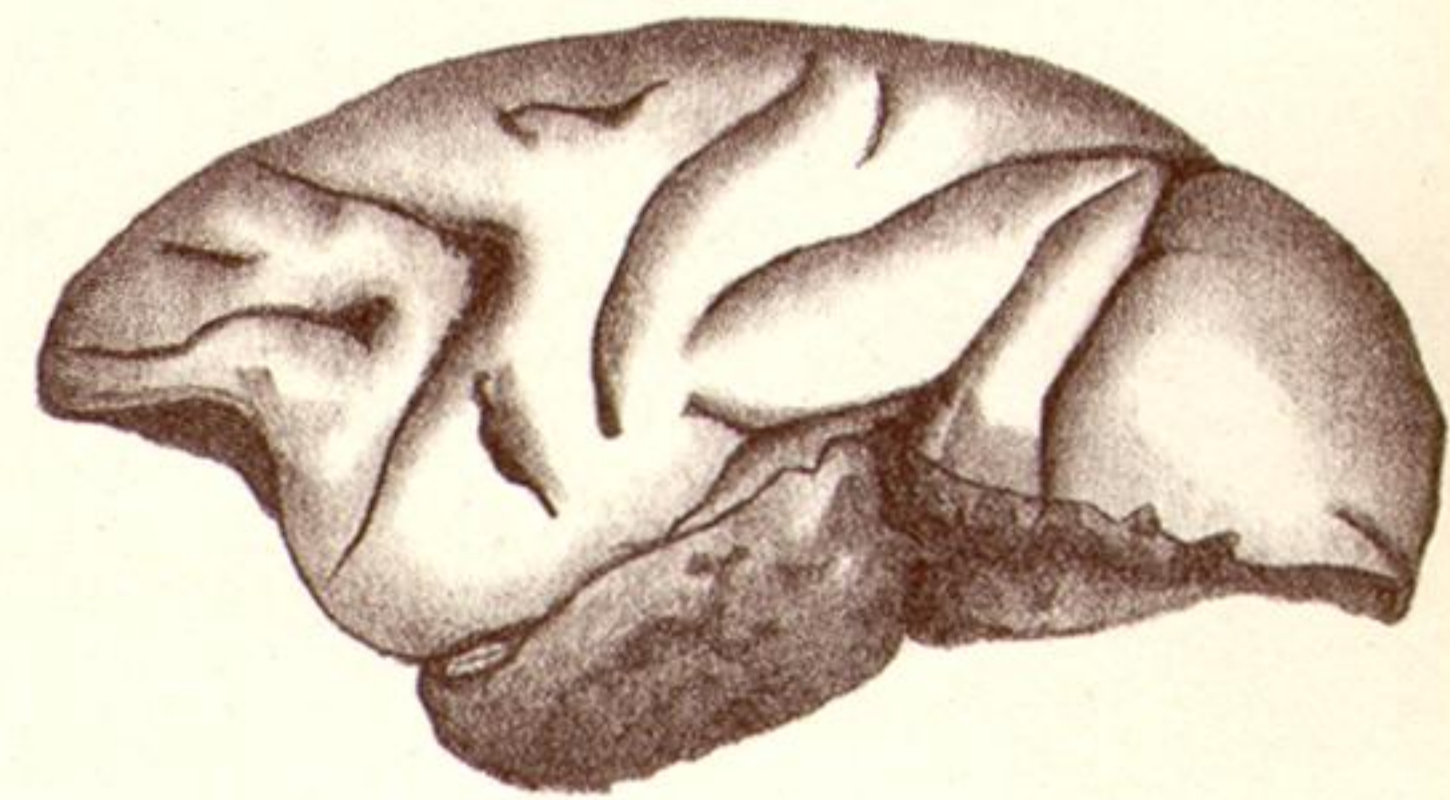31C.



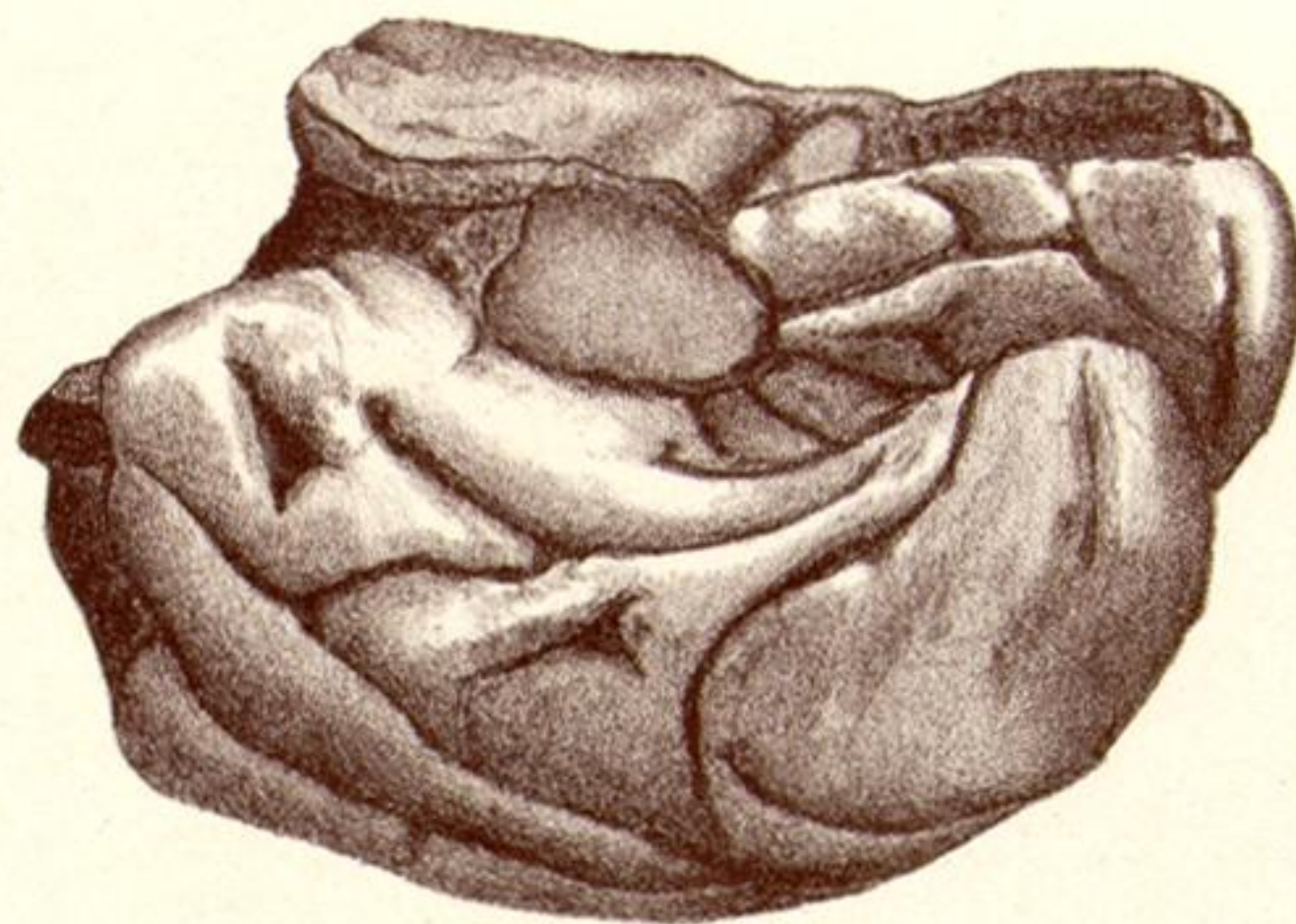31D.



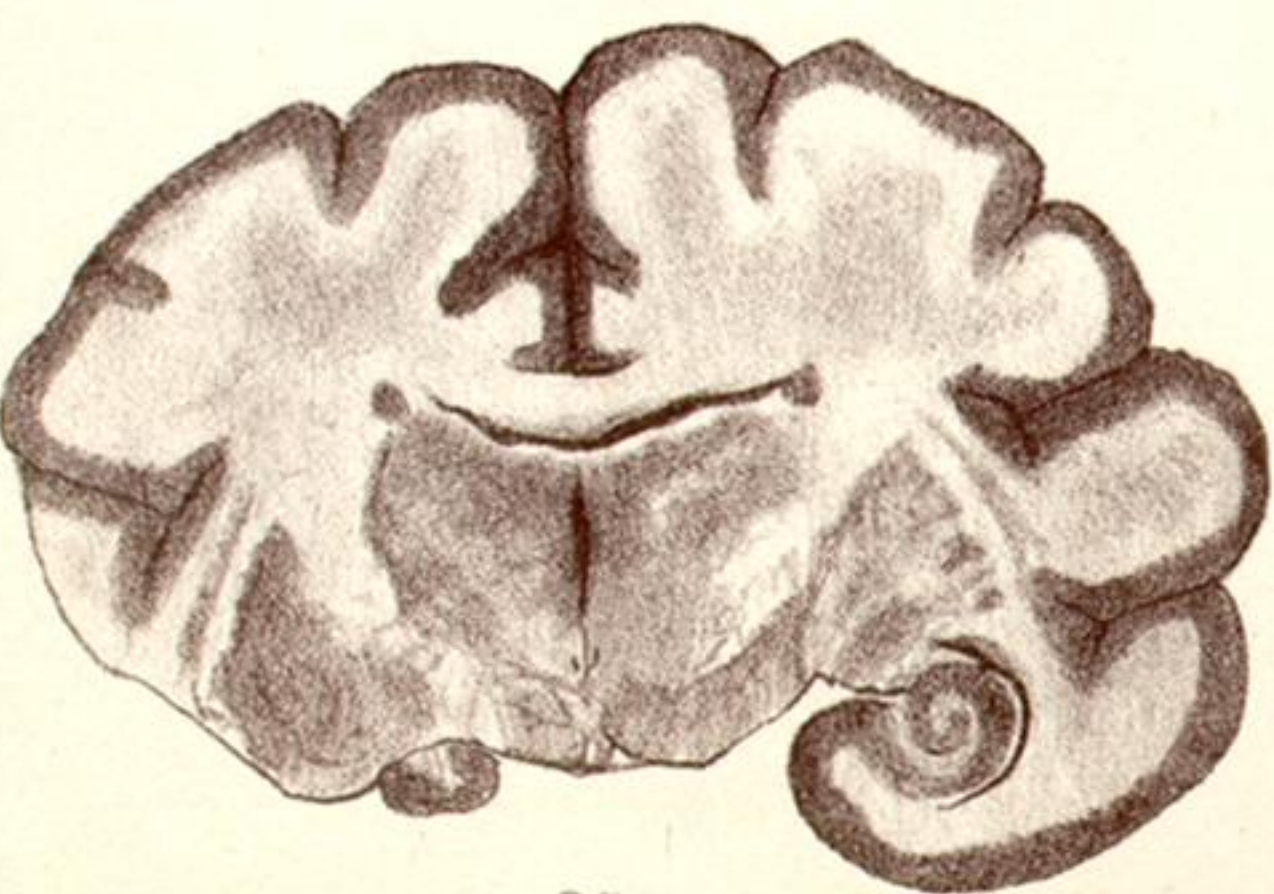
32A.



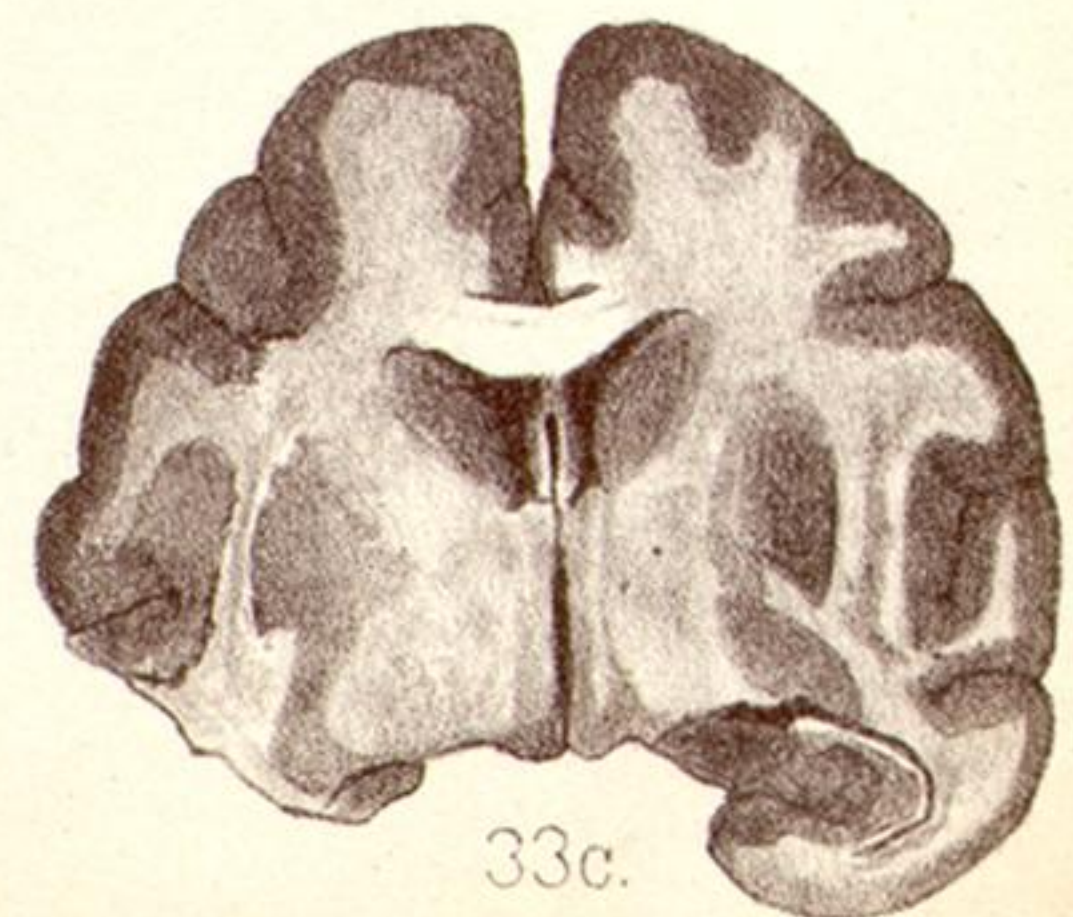33A.



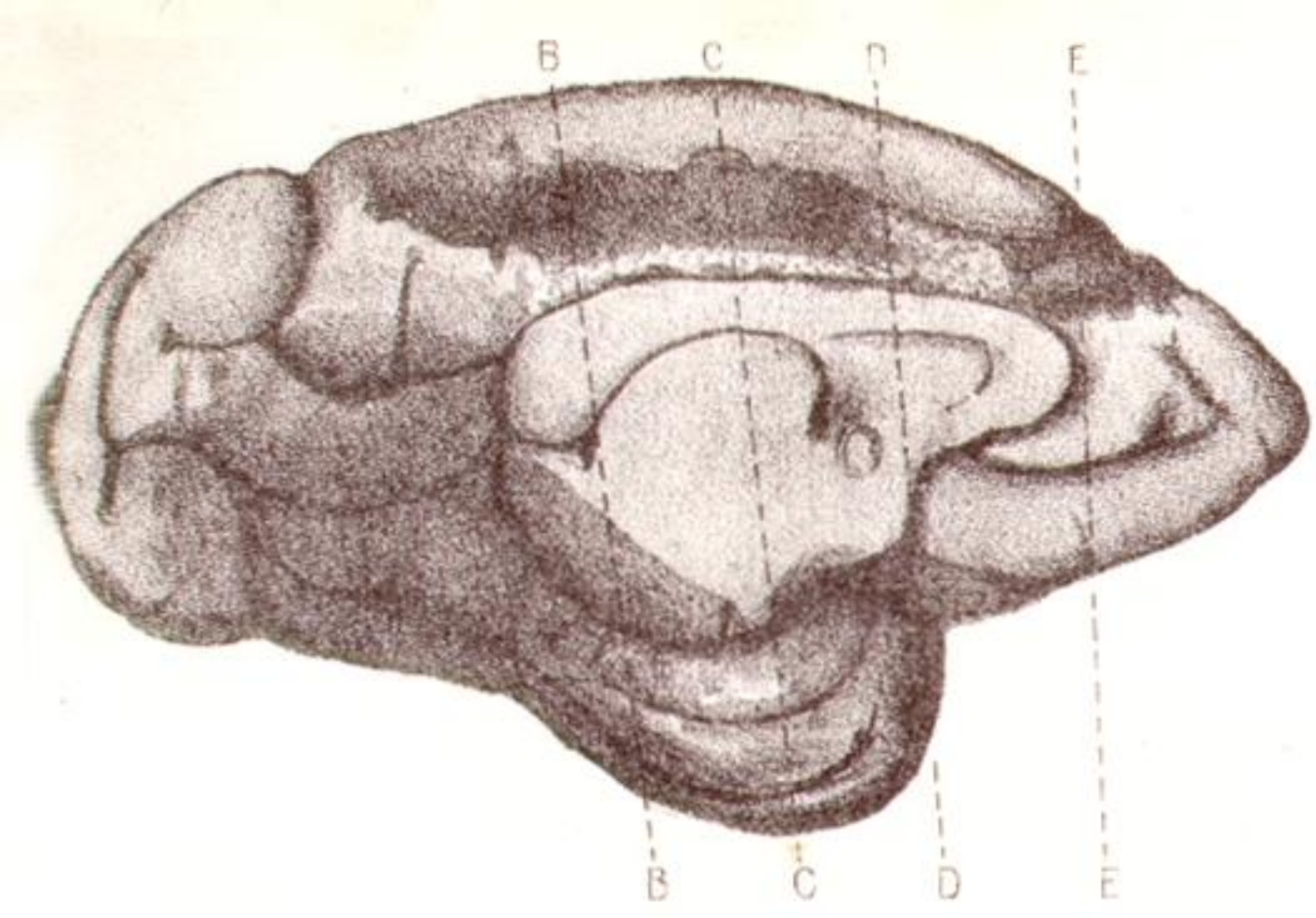
33B.



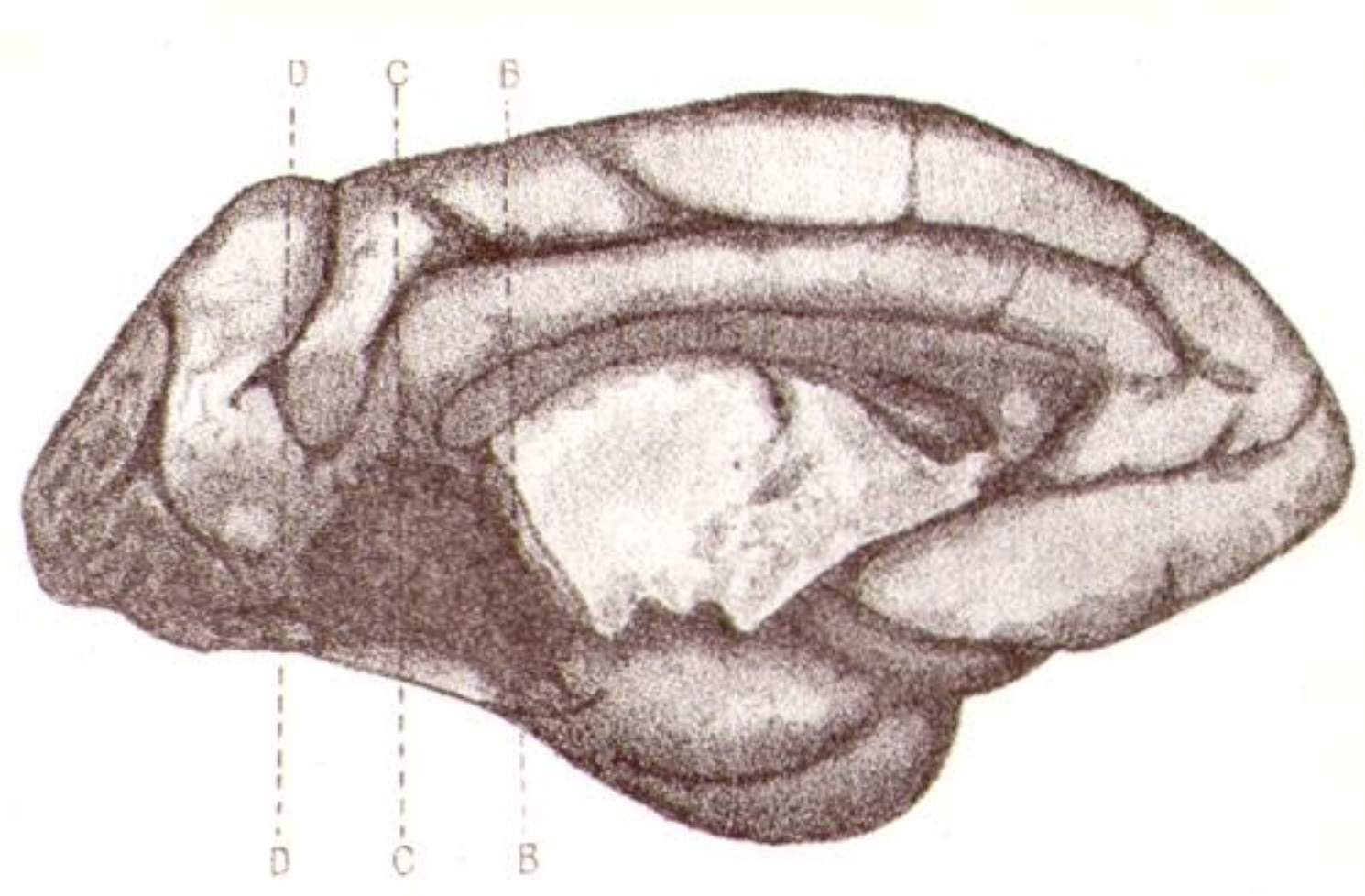
32B.



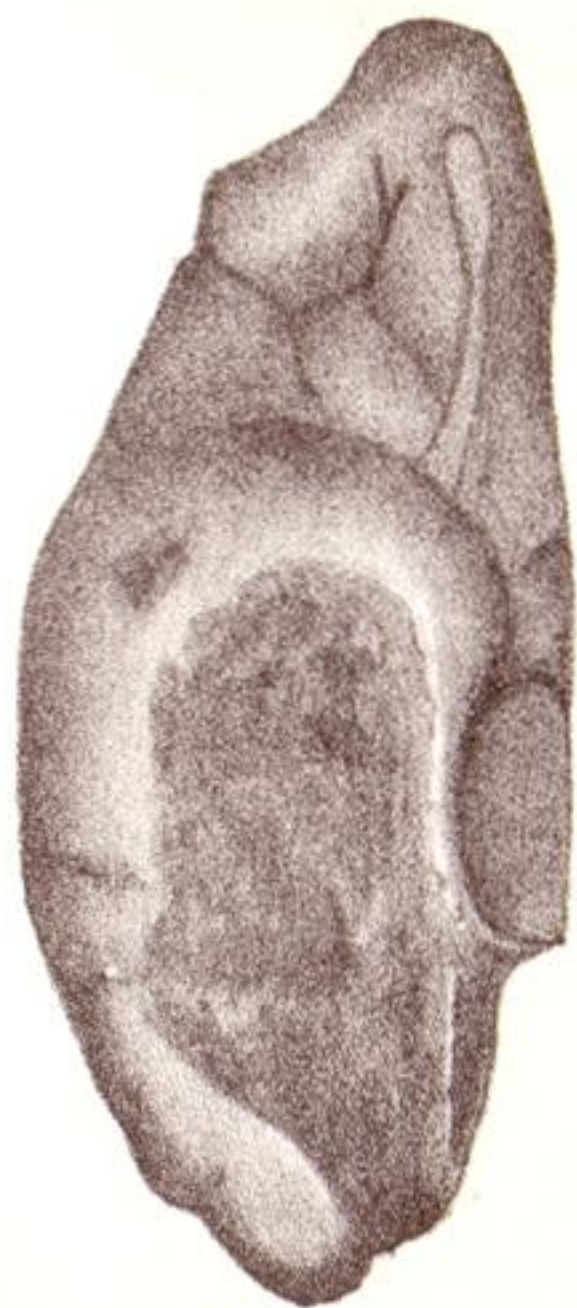
33C.



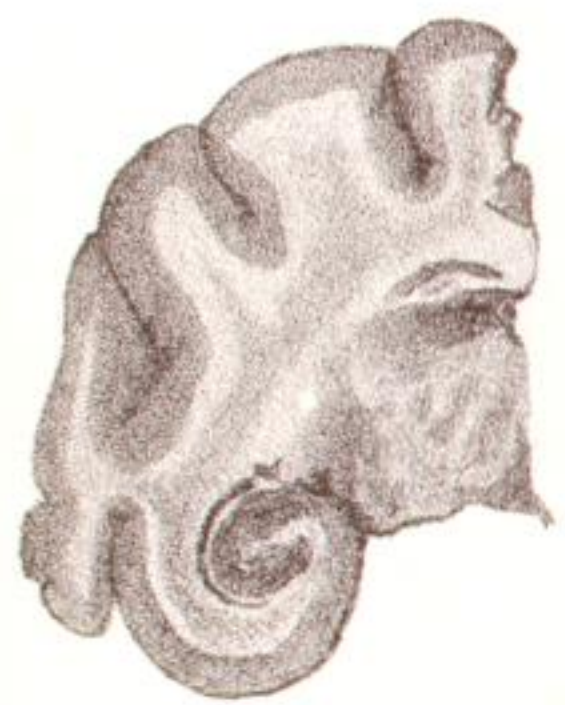37A.



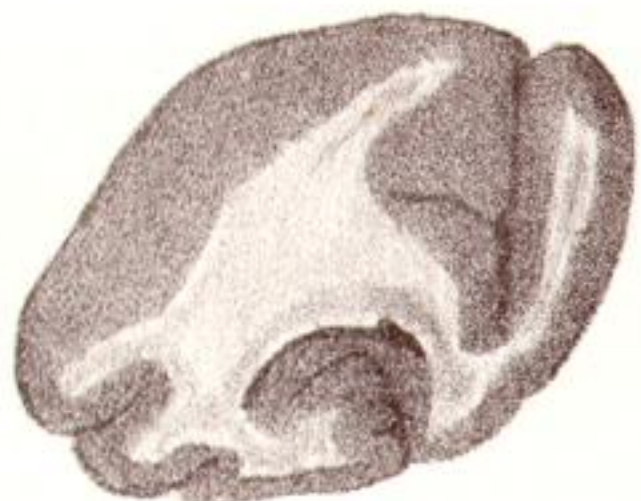38A.



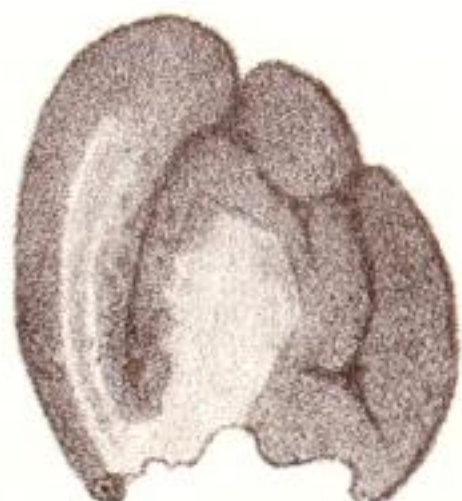34A.



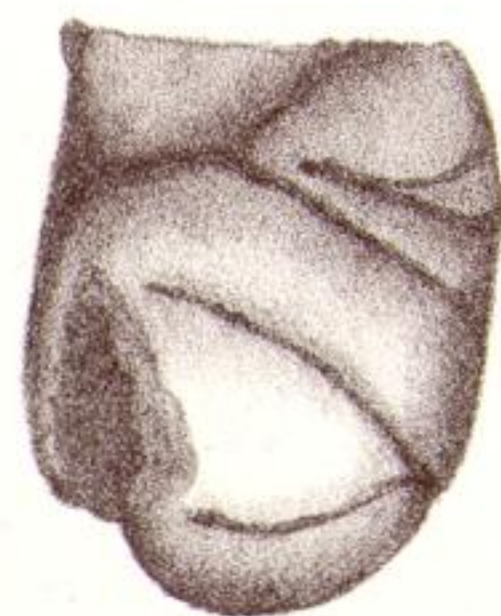
37E.



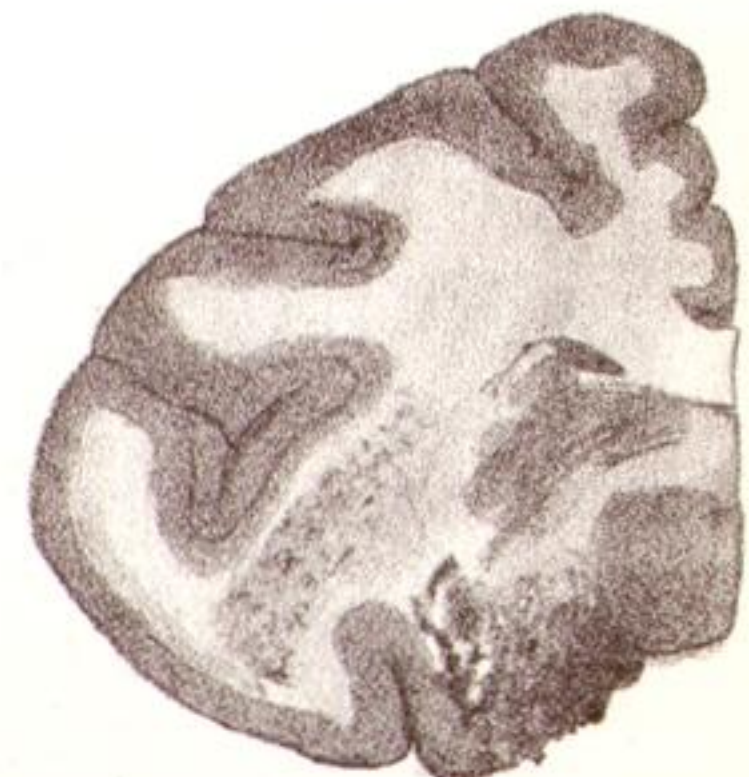34E.



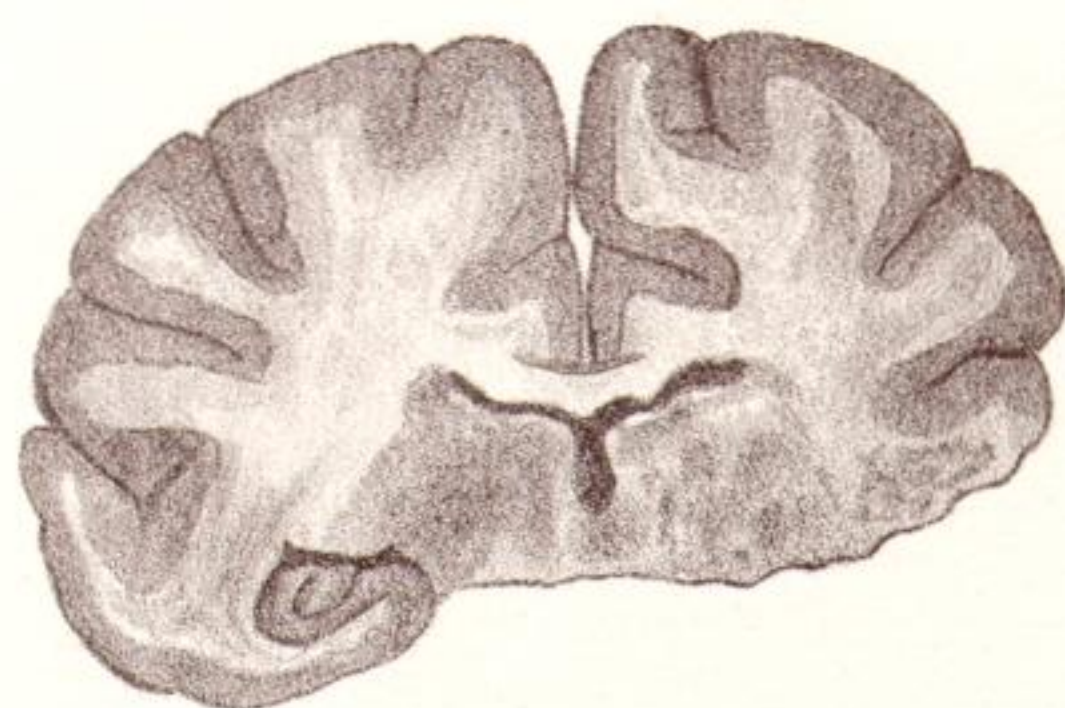34B.



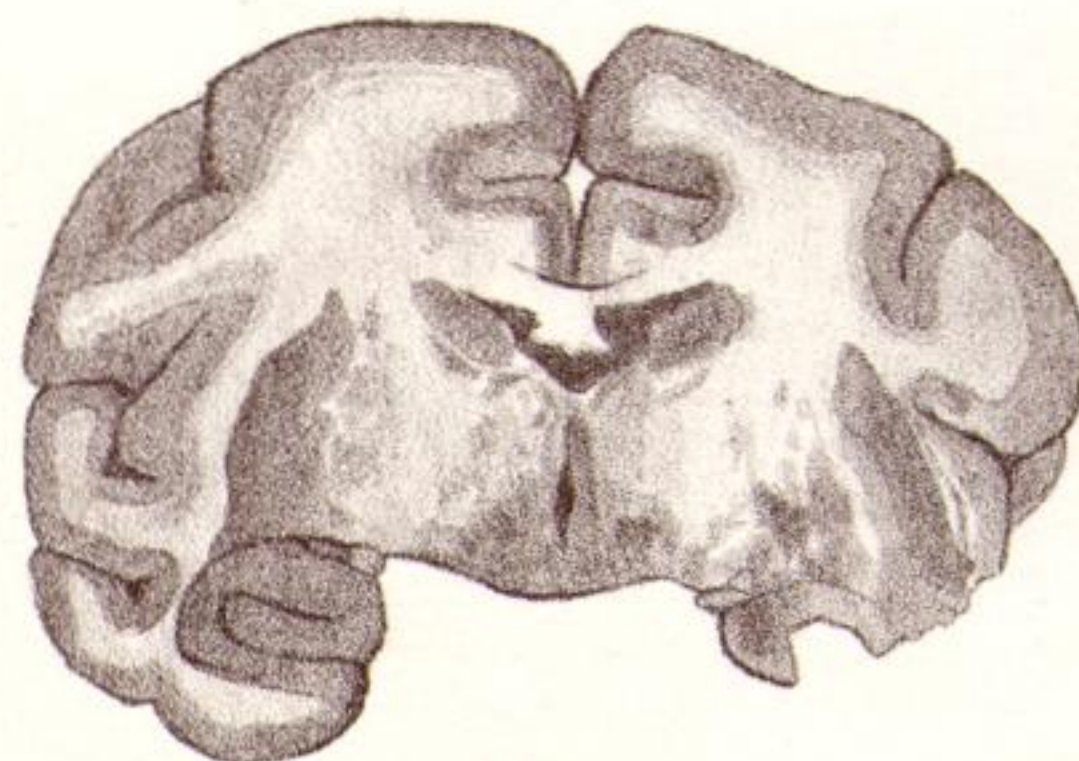
34C.



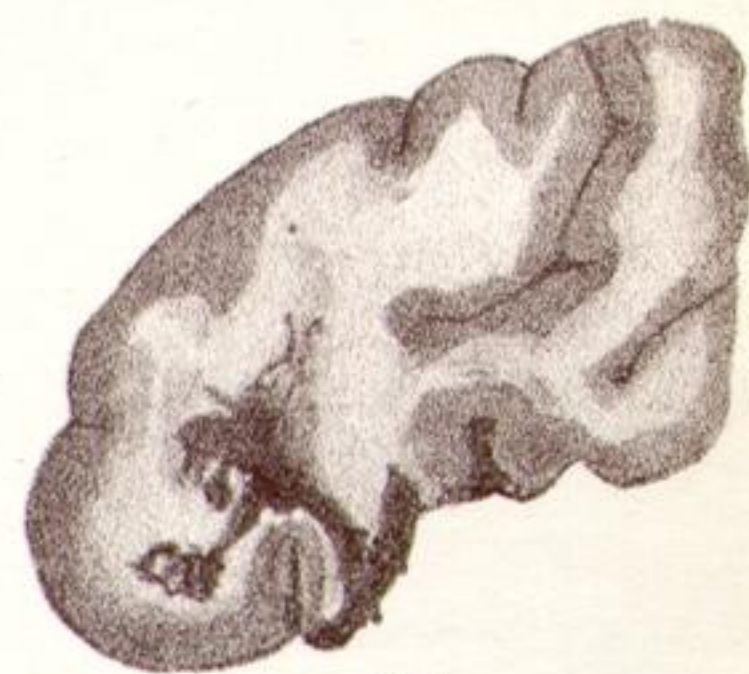38B.



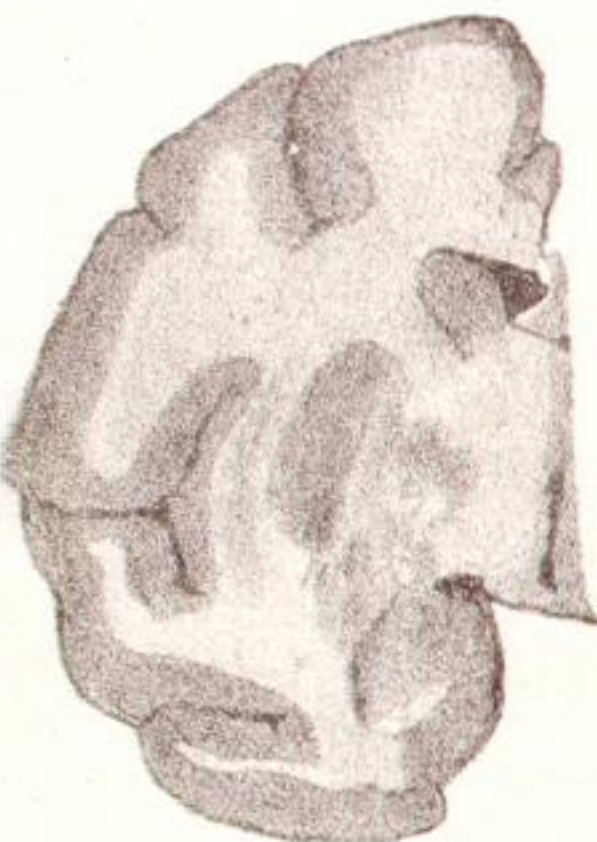34D.



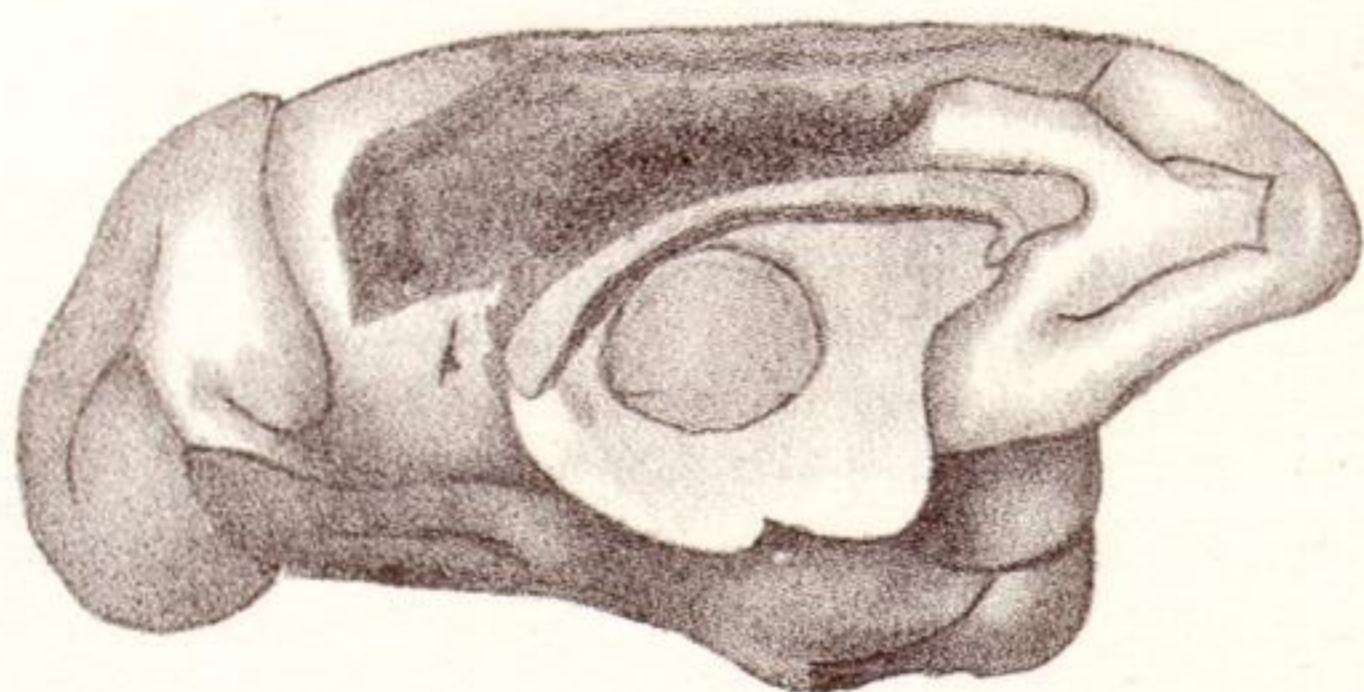
34C.



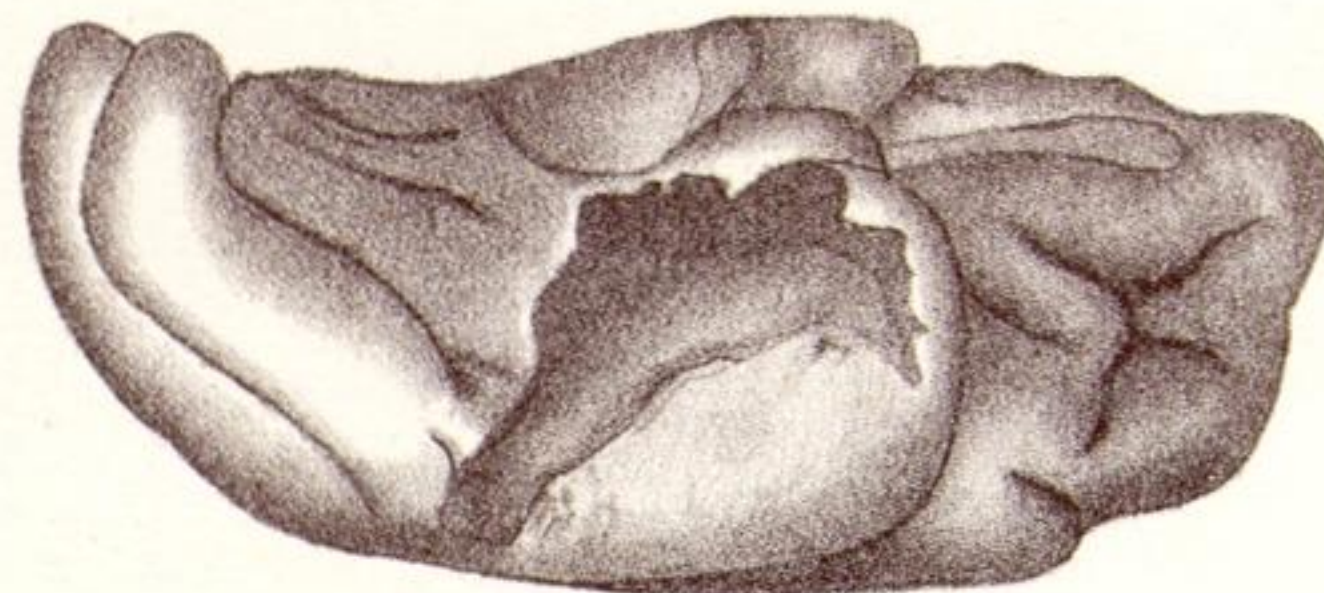38C.



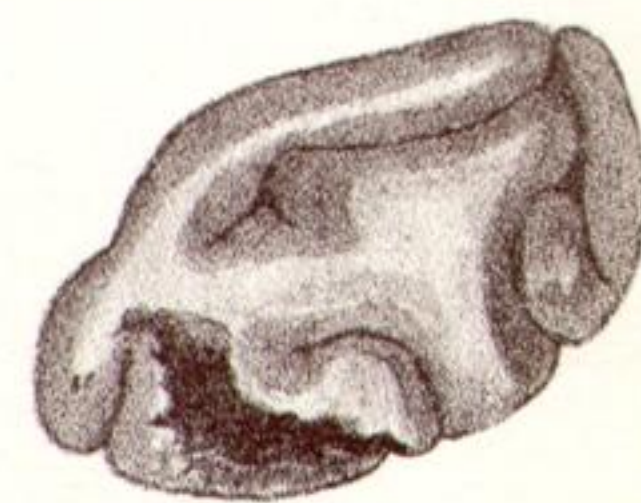37D.



35A.



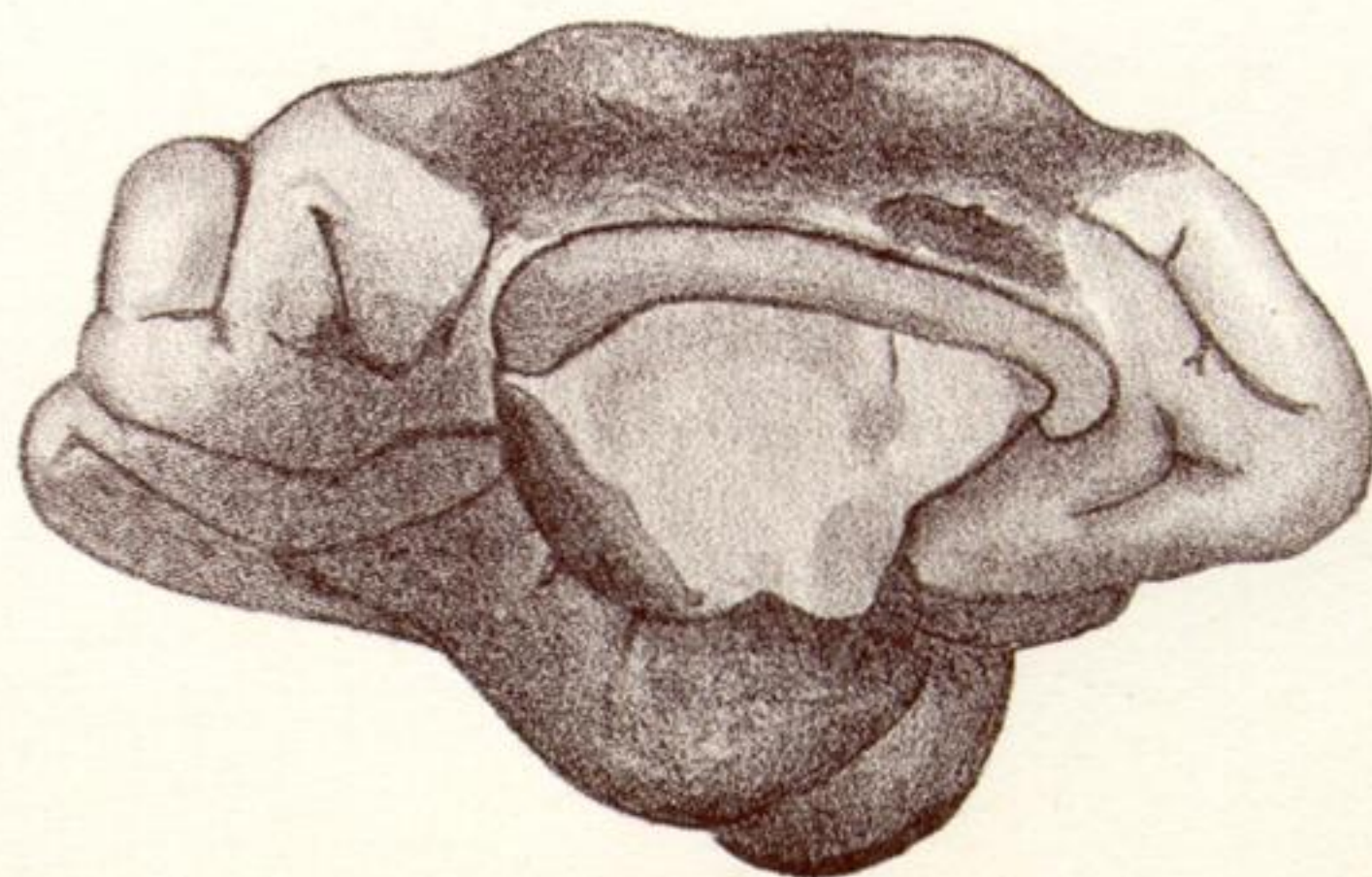
35B.



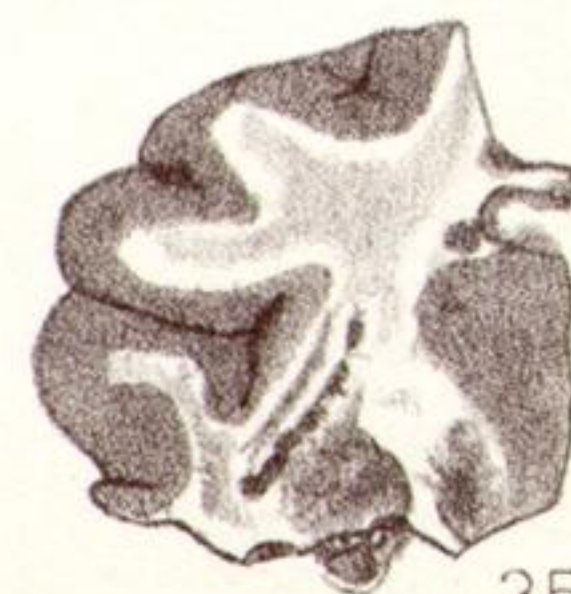38D.



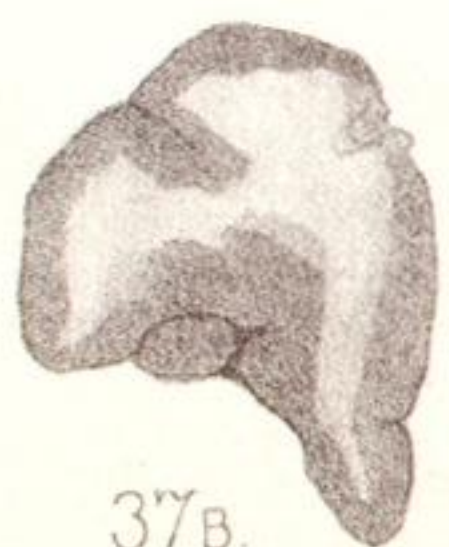
37C.



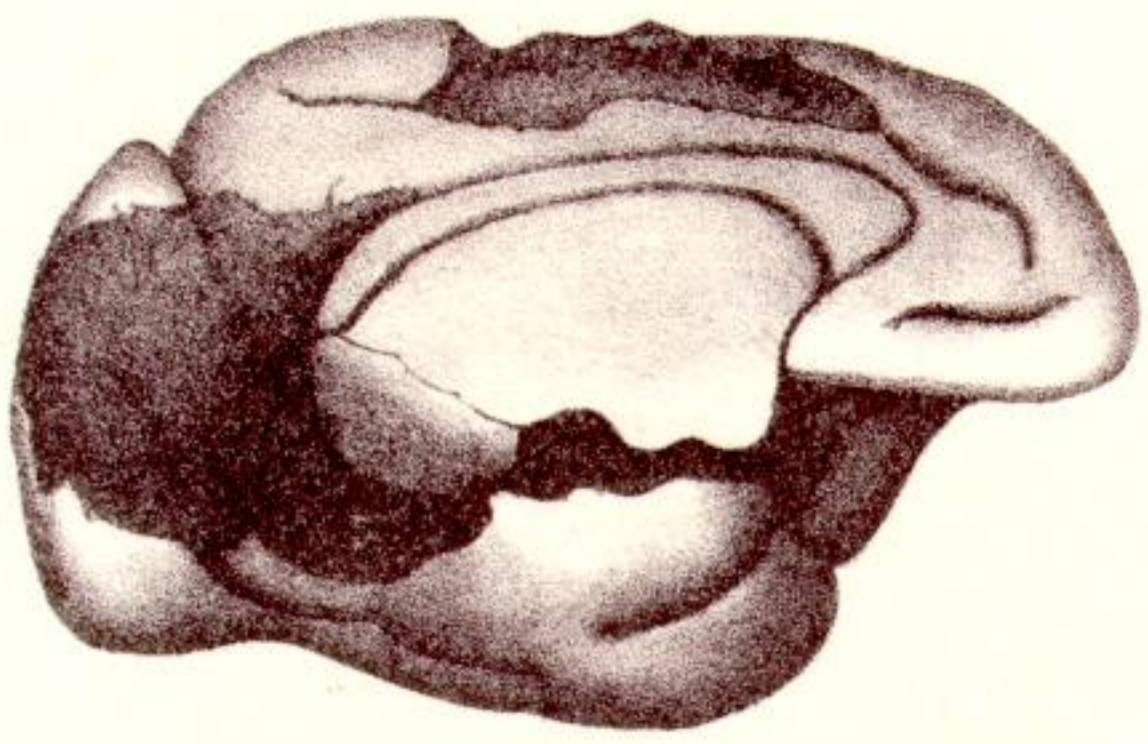
36.



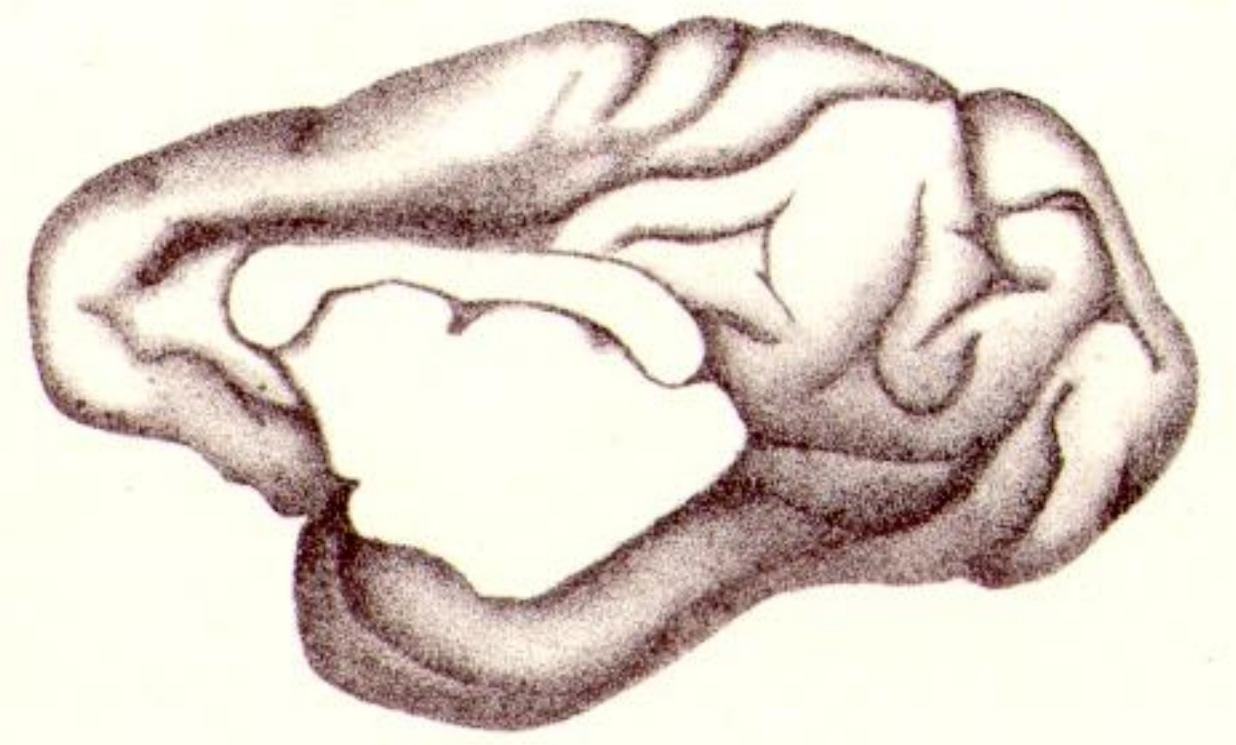
35C.



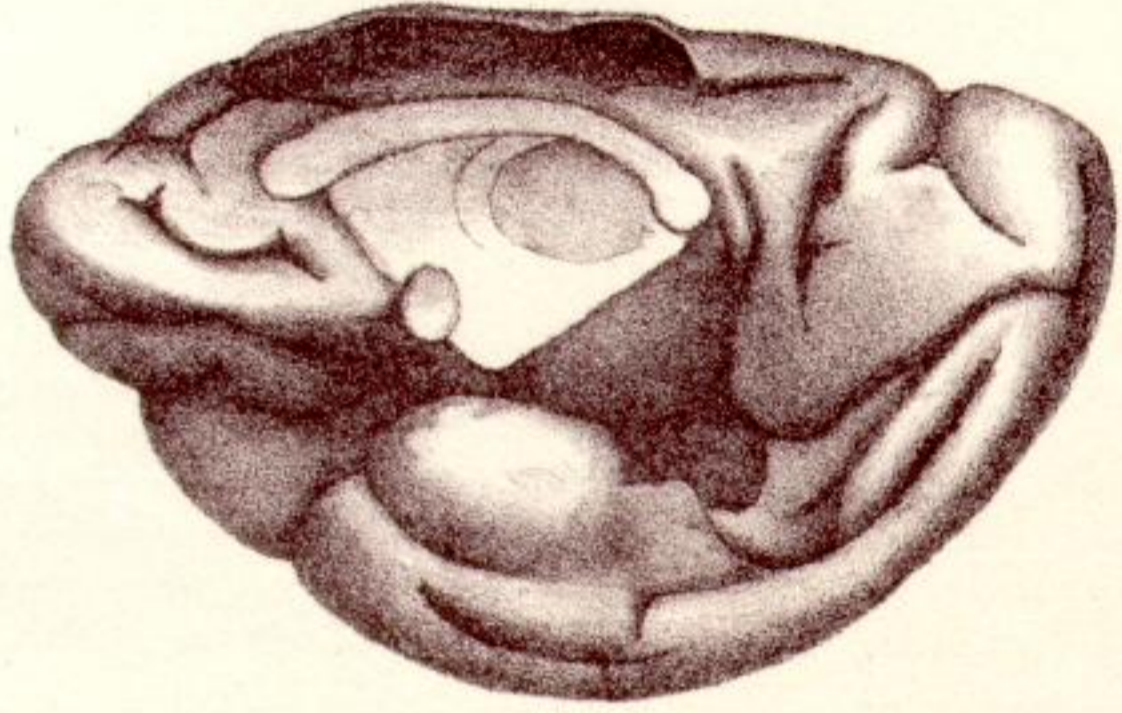
37B.



39.



40A.



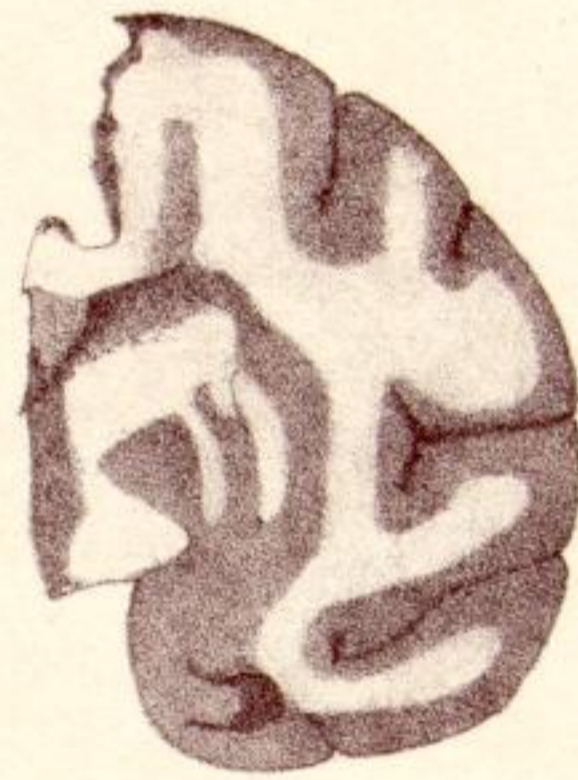41A




40B.



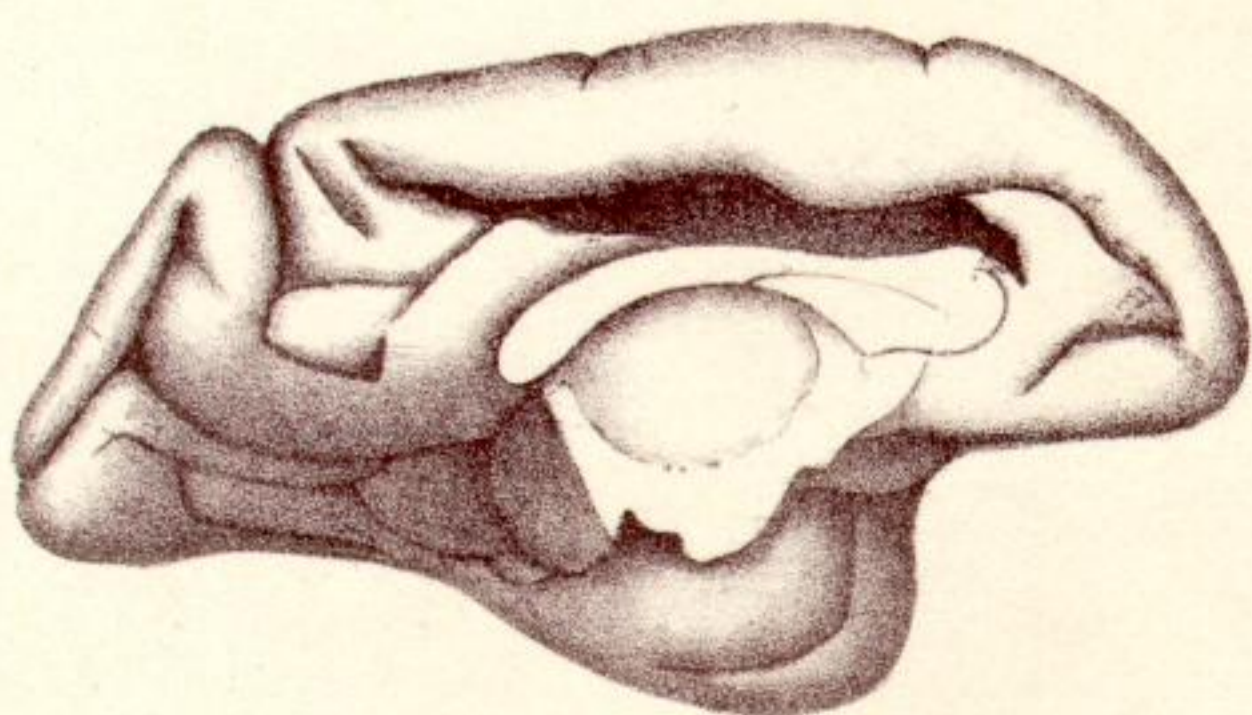
41B.



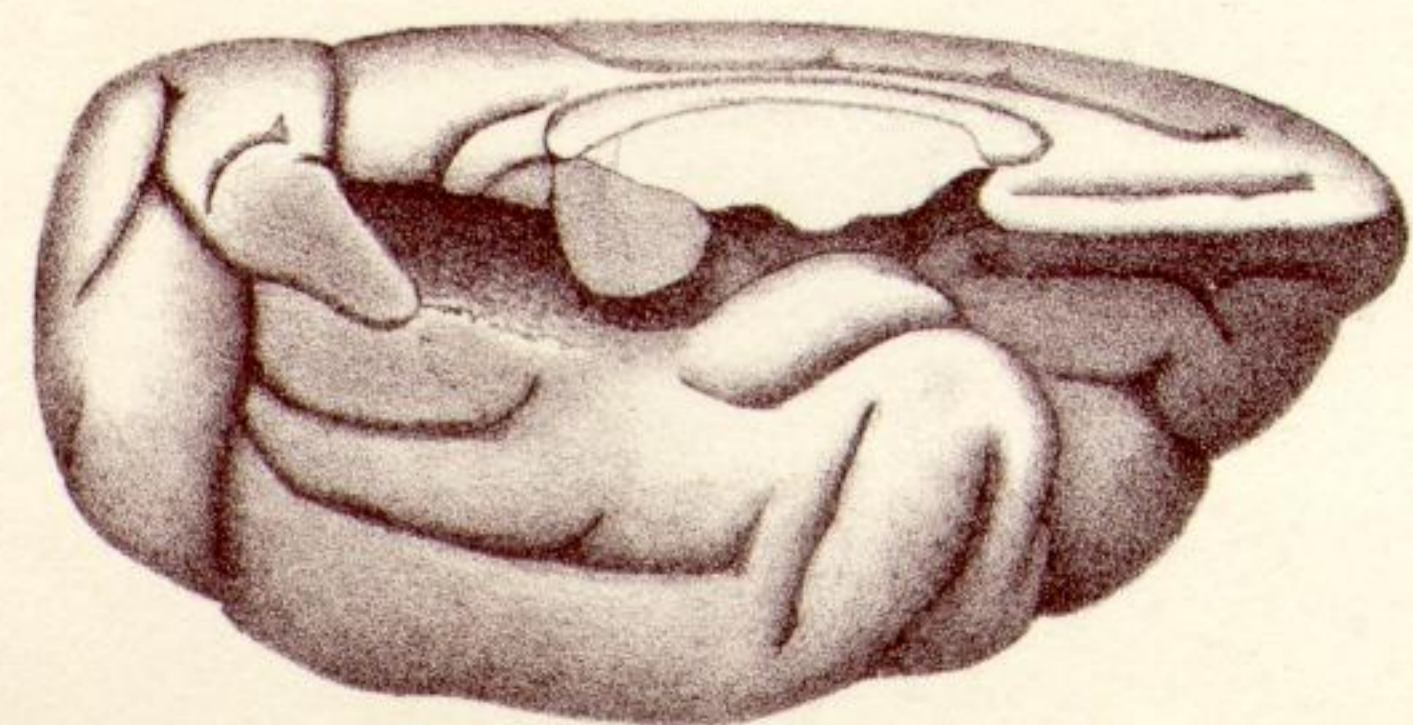
41c



41D



42



43